Boston Children's Hospital
300 Longwood Avenue
Boston, MA 02115

BCH MRN: **500-20-94**
Patient Name: **ALDHAHERI, ABDULLA KHALIFA**
DOB/Age/Sex: 2/18/2014 3 years Male

Admit Date: 9/15/2016
Discharge Date: 9/15/2016

Patient Location: Audiology
Patient Type: Outpatient
Financial #: 6119498964

Audiology

*** Auth (Verified) ***

Boston Children's Hospital
DEPARTMENT OF OTOLARYNGOLOGY
AND COMMUNICATION ENHANCEMENT
300 Longwood Avenue, Boston, MA 02115
Telephone (617) 355-6460

Report of Audiological Evaluation

Referred by: Margaret Kenna, MD, MPH
Date of Exam: 09-15-2016
Audiologist: JENNIFER BUTLER, AuD, CCC-A

MRN: 5002094
First Name: ABDULLA
Last Name: ALDHAHERI
DOB: 02-18-2014
CSN: 6119498964

HISTORY

☐ History of middle ear problems ☐ Most recent ORL procedure: Date:

☑ Speech-language delay ☐ Most recent hearing test: Date:

☐ Referred hearing screening ☐ Newborn hearing screening: at

☑ Suspected hearing loss ☐ Speech-language/aural (re)habilitation:

☐ Educational program:

☑ Other services:Communication therapy 1x/ week

☑ Other: Family from UAE. Born 25 weeks gestation; extended NICU stay; followed by neurosurgery for congenital brain abnormalities; developmental delays. Known severe hearing loss via behavioral testing as ABR testing indicated "no response." Discontinued binaural hearing aids as his family reports responsiveness without amplification.

AUDIOGRAM

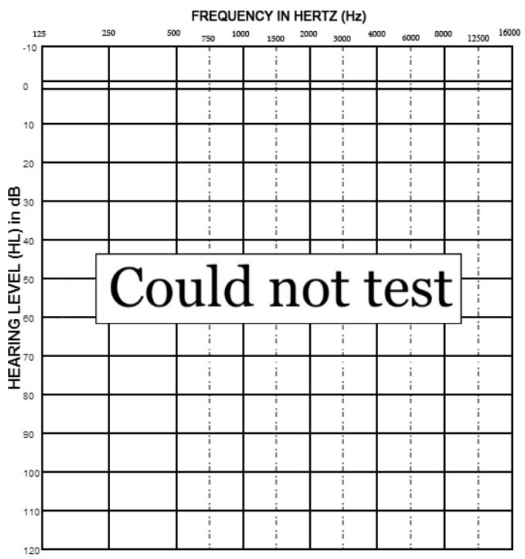

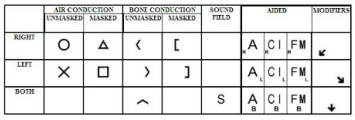

Test Room: BOS-5

Audiometer: GSI 61

Assist: KD

Test Methods for Audiogram:
☐ Conventional Audiometry
☐ Conditioned Play Audiometry
☑ Visual Reinforcement Audiometry
☑ Behavioral Observation Audiometry

Test Stimuli:
☐ Pure tones
☑ Warbled tones
☑ Narrow band noise

Transducer:
☑ Supra-aural earphones
☐ Insert earphones
☐ Earmold+insert
☑ Speaker

Reliability:
○ Good ◉ Fair ○ Poor

SPEECH AUDIOMETRY

	Est. SII	PTA	SRT (dB HL)	SAT (dB HL)	Masking (dB HL)	Word Recognition %	Word Recognition dB HL	Word Recognition Masking (dB HL)
R	- - -	- - -		CNT				
L	- - -	- - -		CNT				
BC	- - -	- - -		50				
SF	- - -	- - -		CNT				

Speech Reception Threshold (SRT):

Speech Awareness Threshold (SAT): speech & music

Word Recognition:

Presentation: ☐ Male ☑ Female ☑ Live Voice ☑ Recorded

IMMITTANCE MEASURES

TYMPANOMETRY PROBE FREQUENCY ☑ 226 Hz ☐ 1000 Hz

EAR	EQUIV CANAL VOL (cc)	PEAK PRESSURE (daPa)	STATIC ADMITTANCE (mmho)	GRADIENT (daPa)	DNT	CNT
RIGHT	0 . 6	- 292	0 . 3	Clear peak	☐	☐
LEFT	0 . 7	- 332	0 . 2	Rounded	☐	☐

MIDDLE EAR MUSCLE REFLEX THRESHOLDS

PROBE EAR	STIMULUS EAR (MODE)	500 Hz	1000 Hz	2000 Hz	DNT	CNT
RIGHT	RIGHT (IPSI)				☐	☐
	LEFT (CONTRA)					
LEFT	LEFT (IPSI)				☐	☐
	RIGHT (CONTRA)					

DNT: Did not test CNT: Could not test

*** Auth (Verified) ***

OTHER TEST FINDINGS

Clear conditioned responses to speech and tonal stimuli could not be obtained through the speakers or earphones. Speech awareness threshold obtained for bone conduction at 50 dB HL suggestive of a moderate hearing loss in at least one ear. DPOAES deferred due to patient activity level with tympanometry.

INTERPRETATION OF AUDIOMETRY

RIGHT EAR:

☐ Normal hearing

☐ hearing loss.

LEFT EAR:

☐ Normal hearing

☐ hearing loss.

UNMASKED BONE (not ear-specific):

☐ Normal.

☐ Consistent with conductive component.

☐ Consistent with sensorineural component.

☐ Consistent with mixed hearing loss.

SOUNDFIELD (Loudspeaker: not ear-specific):

☐ Normal hearing for at least one ear

☐ degree of hearing loss for at least one ear
(the better hearing ear, if there is an ear difference).

INTERPRETATION OF IMMITTANCE

Ear	Equiv Canal Volume	Peak Pressure	Admittance	Gradient
Right	Normal	Negative	Normal	
Left	Normal	Negative	Reduced	

TYMPANOMETRY

☐ Normal:

☐ Consistent with middle ear dysfunction:

☐ Consistent with patent PE tube or non-intact tympanic membrane:

☑ Consistent with Eustachian tube dysfunction:

Both Ears

MIDDLE EAR MUSCLE REFLEXES

☐ Normal:

☐ Consistent with cochlear pathology:

☐ Consistent with retrocochlear pathology:

☐ Consistent with facial nerve pathology:

COMMENTS AND RECOMMENDATIONS

Examination of ear health by a physician re: Eustachian tube dysfunction. Abdulla is scheduled to see Dr. Margaret Kenna, ORL on 10/3/2016. Retest hearing in conjunction with otologic care. Today's behavioral hearing test results yielded limited information regarding hearing sensitivity. Pending medical clearance, consider a more objective measure of hearing, such as Auditory Brainstem Response (ABR) testing to further assess Abdulla's hearing. In light of Abdulla's brain abnormalities briefly described in the medical records provided, this form of testing may not yield conclusive audiologic information. The parents asked several questions regarding amplification (i.e., hearing aids and cochlear implants). Additional audiological recommendations pending future evaluations.

CPT Codes:
92579; 92567;

ICD Codes:
H91.90; F80.9; H69.93; Z87.898;

Jennifer L Butler
AuD CCC-A

JENNIFER BUTLER, AuD, CCC-A

Date of Exam: 09-15-2016

ALDHAHERI , 5002094 : 6119498964

Boston Children's Hospital
300 Longwood Avenue
Boston, MA 02115

BCH MRN: **500-20-94**
Patient Name: **ALDHAHERI, ABDULLA KHALIFA**
DOB/Age/Sex: 2/18/2014 3 years Male

Admit Date: 10/31/2016
Discharge Date: 10/31/2016

Patient Location: Audiology
Patient Type: Outpatient
Financial #: 6119768705

Audiology

*** Auth (Verified) ***

Boston Children's Hospital
DEPARTMENT OF OTOLARYNGOLOGY
AND COMMUNICATION ENHANCEMENT
300 Longwood Avenue, Boston, MA 02115
Telephone (617) 355-6460

Report of Audiological Evaluation

Referred by: Margaret Kenna, MD, MPH
Date of Exam: 10-31-2016
Audiologist: JENNIFER BUTLER, AuD, CCC-A

MRN: 5002094
First Name: ABDULLA
Last Name: ALDHAHERI
DOB: 02-18-2014
CSN: 6119768705

HISTORY

☐ History of middle ear problems ☐ Most recent ORL procedure: Date:

☐ Speech-language delay ☐ Most recent hearing test: Date:

☐ Referred hearing screening ☐ Newborn hearing screening: at

☐ Suspected hearing loss ☐ Speech-language/aural (re)habilitation:

☐ Educational program:

☐ Other services:

☑ Other: Family from UAE. Born 25 weeks gestation; extended NICU stay; history of congenital brain abnormalities; developmental delays. Known hearing loss diagnosed in UAE. Previous use of hearing aids, but use discontinued due to responsiveness without amplification.

AUDIOGRAM

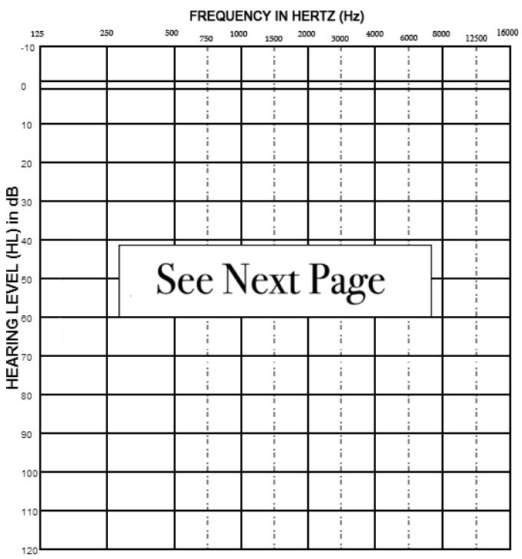

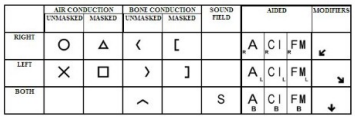

Test Room:

Audiometer:

Assist:

Test Methods for Audiogram:
☐ Conventional Audiometry
☐ Conditioned Play Audiometry
☐ Visual Reinforcement Audiometry
☐ Behavioral Observation Audiometry

Test Stimuli:
☐ Pure tones
☐ Warbled tones
☐ Narrow band noise

Transducer:
☐ Supra-aural earphones
☐ Insert earphones
☐ Earmold+insert
☐ Speaker

Reliability:
○ Good ○ Fair ○ Poor

SPEECH AUDIOMETRY

	Est. SII	PTA	SRT (dB HL)	SAT (dB HL)	Masking (dB HL)	Word Recognition %	Word Recognition dB HL	Word Recognition Masking (dB HL)
R	- - -	- - -						
L	- - -	- - -						
BC	- - -	- - -						
SF	- - -	- - -						

Speech Reception Threshold (SRT):

Speech Awareness Threshold (SAT):

Word Recognition:

Presentation: ☐ Male ☐ Female ☐ Live Voice ☐ Recorded

IMMITTANCE MEASURES

TYMPANOMETRY PROBE FREQUENCY ☐ 226 Hz ☐ 1000 Hz

EAR	EQUIV CANAL VOL (cc)	PEAK PRESSURE (daPa)	STATIC ADMITTANCE (mmho)	GRADIENT (daPa)	DNT	CNT
RIGHT	.		.		☑	☐
LEFT	.		.		☑	☐

MIDDLE EAR MUSCLE REFLEX THRESHOLDS

PROBE EAR	STIMULUS EAR (MODE)	500 Hz	1000 Hz	2000 Hz	DNT	CNT
RIGHT	RIGHT (IPSI)				☐	☐
	LEFT (CONTRA)					
LEFT	LEFT (IPSI)				☐	☐
	RIGHT (CONTRA)					

DNT: Did not test CNT: Could not test

*** Auth (Verified) ***

ELECTROPHYSIOLOGY

☐ Screening ☑ Comprehensive Diagnostic Evaluation ☐ Neurodiagnostic Evaluation

AUDITORY BRAINSTEM RESPONSE (ABR) THRESHOLDS

Equipment: Biologic AEP ☐ Natural Sleep ☐ Sedation ☑ General Anesthesia

	Click		500 Hz		1000 Hz		2000 Hz		4000 Hz		8000 Hz	
Air Conduction	**nHL**	**eHL**	**nHL**	**eHL**	**nHL**	**eHL**	**nHL**	**eHL**	**nHL**	**eHL**	**nHL**	**eHL**
Left AC ☐ Masked					>105		>105					
Right AC ☐ Masked					>95		>105					

Bone Conduction	**nHL**	**eHL**	**nHL**	**eHL**	**nHL**	**eHL**	**nHL**	**eHL**	**nHL**	**eHL**
Left BC ☐ masked										
Right BC ☐ masked										

Note: It is generally accepted that for large groups of subjects, click-evoked wave V thresholds correlate with the hearing sensitivity in the 2000 - 4000 Hz range. However, individual responses may not correlate with the group average. nHL = Normalized Hearing Level; eHL = Estimated Hearing Level; eHL values should be used for amplification programming when appropriate.

NEURODIAGNOSTIC AUDITORY BRAINSTEM RESPONSE (ABR)

Equipment:				**Absolute Latency (ms)**			**Interpeak Latency (ms)**		
Ear	**Stimulus Polarity**	**Intensity (nHL)**	**Stimulus Rep Rate (rate/sec)**	**I**	**III**	**V**	**I-III**	**III-V**	**I-V**

COMMENTS:

Auditory Brainstem Response (ABR) testing was completed to estimate peripheral hearing sensitivity. Auditory evoked potentials were recorded via 3 scalp electrodes while Abdulla was sedated under general anesthesia. Otoscopic examination was performed by Pediatric Otolaryngologist, Dr. Volk prior to today's testing. Ears were judged to be clear of debris/fluid. Evidence of a cochlear microphonic (CM) was noted using reverse polarity (rarefaction and condensation) stimulus presentations at 95 dB nHL for both right and left ear. A wave V as not elicited. Stimulus/recording artifact was ruled out using a click presentation at 95 dB nHL with clamped tubing. A lower amplitude is noted for the reversing CM for the left ear. Additional frequencies were also tested and no discernible wave V was noted at intensity levels of 95-105 dB nHL.

*** Auth (Verified) ***

OTHER TEST FINDINGS

Distortion Product Otoacoustic Emmisions (DPOAEs), a sensitive measure of outer hair cell function were absent 2000-8000 Hz bilaterally.

INTERPRETATION OF AUDIOMETRY

RIGHT EAR:

☐ Normal hearing

☐ hearing loss.

LEFT EAR:

☐ Normal hearing

☐ hearing loss.

UNMASKED BONE (not ear-specific):

☐ Normal.

☐ Consistent with conductive component.

☐ Consistent with sensorineural component.

☐ Consistent with mixed hearing loss.

SOUNDFIELD (Loudspeaker: not ear-specific):

☐ Normal hearing for at least one ear

☐ degree of hearing loss for at least one ear
(the better hearing ear, if there is an ear difference).

INTERPRETATION OF IMMITTANCE

Ear	Equiv Canal Volume	Peak Pressure	Admittance	Gradient
Right				
Left				

TYMPANOMETRY

☐ Normal:

☐ Consistent with middle ear dysfunction:

☐ Consistent with patent PE tube or non-intact tympanic membrane:

☐ Consistent with Eustachian tube dysfunction:

MIDDLE EAR MUSCLE REFLEXES

☐ Normal:

☐ Consistent with cochlear pathology:

☐ Consistent with retrocochlear pathology:

☐ Consistent with facial nerve pathology:

COMMENTS AND RECOMMENDATIONS

The results of today's Auditory Brainstem Response (ABR) test are consistent with Auditory Neuropathy Spectrum Disorder (ANSD). These results were reviewed with Abdulla's parents who asked several questions regarding future management (i.e. hearing aids & cochlear implants). Otologic follow up with Dr. Kenna. Pending approval through the International Office additional appointments may be scheduled with DHHP for ongoing management.

CPT Codes:
92585;

ICD Codes:
R94.120; Z87.898; H90.3;

Jennifer L Butler
AuD CCC-A

JENNIFER BUTLER, AuD, CCC-A

Date of Exam: 10-31-2016

ALDHAHERI , 5002094 : 6119768705

*** Auth (Verified) ***

APPENDIX

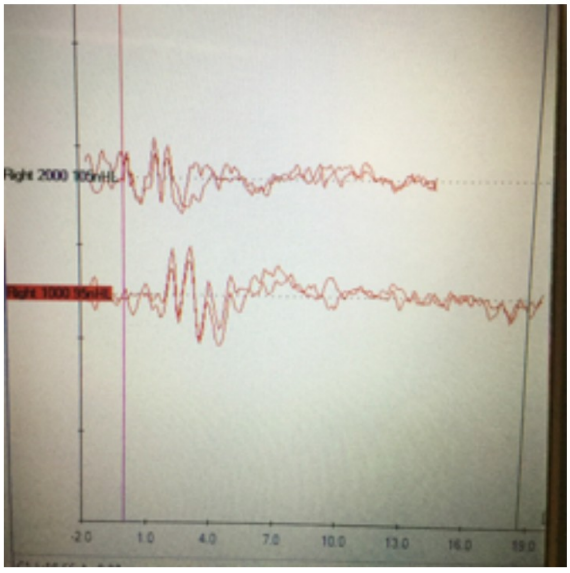

ABR Notes:
ABR wave forms, right ear

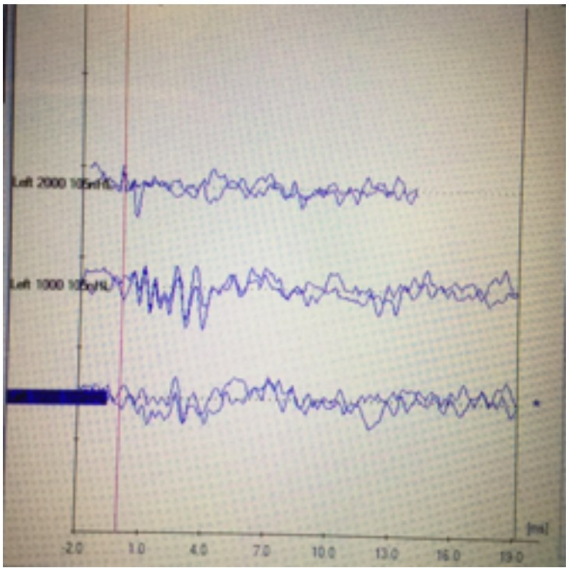

ABR Notes:
ABR waveforms, left ear

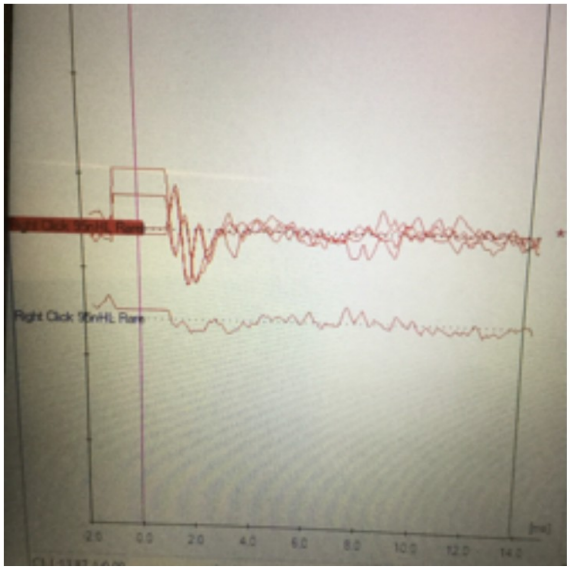

Result Notes:
ABR waveforms, right ear (reversing CM 95 dBnHL click stimulus & pinched tube)

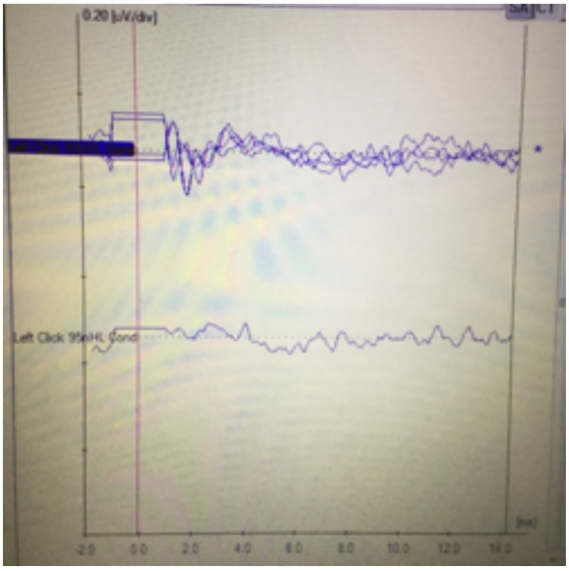

Result Notes:
ABR waveforms, left ear (reversing CM 95 dBnHL click stimulus & pinched tube)

Boston Children's Hospital
300 Longwood Avenue
Boston, MA 02115

BCH MRN: **500-20-94**
Patient Name: **ALDHAHERI, ABDULLA KHALIFA**
DOB/Age/Sex: 2/18/2014 3 years Male

Admit Date: 11/29/2016
Discharge Date: 11/29/2016

Patient Location: Audiology
Patient Type: Outpatient
Financial #: 6119961167

Audiology

*** Auth (Verified) ***

Boston Children's Hospital
DEPARTMENT OF OTOLARYNGOLOGY
AND COMMUNICATION ENHANCEMENT
300 Longwood Avenue, Boston, MA 02115
Telephone (617) 355-6460

Report of Audiological Evaluation

Referred by: CI Program
Date of Exam: 11-29-2016
Audiologist: ASHLEIGH LEWKOWITZ, AuD

MRN: 5002094
First Name: ABDULLA
Last Name: ALDHAHERI
DOB: 02-18-2014
CSN: 6119961167

HISTORY

☐ History of middle ear problems ☐ Most recent ORL procedure: Date:

☐ Speech-language delay ☐ Most recent hearing test: Date:

☐ Referred hearing screening ☐ Newborn hearing screening: at

☐ Suspected hearing loss ☐ Speech-language/aural (re)habilitation:

☐ Educational program:

☐ Other services:

☑ Other: See full narrative report in Powerchart - Documents\Clinical Documents\Clinics\Audiology.

AUDIOGRAM

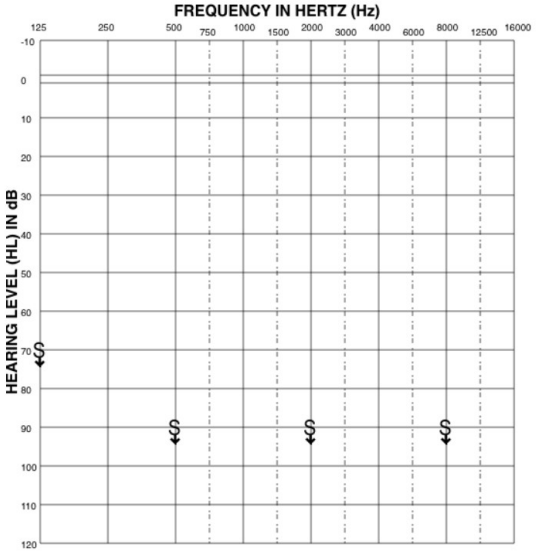

	AIR CONDUCTION UNMASKED	AIR CONDUCTION MASKED	BONE CONDUCTION UNMASKED	BONE CONDUCTION MASKED	SOUND FIELD	AIDED	MODIFIERS
RIGHT	O	△	〈	[		A CI FM	↙
LEFT	X	□	〉	]		A CI FM	↘
BOTH			⌒		S	A CI FM	↓

Test Room: BOS-4

Audiometer: GSI 61

Assist: JB

Test Methods for Audiogram:
☐ Conventional Audiometry
☐ Conditioned Play Audiometry
☑ Visual Reinforcement Audiometry
☑ Behavioral Observation Audiometry

Test Stimuli:
☐ Pure tones
☑ Warbled tones
☑ Narrow band noise

Transducer:
☐ Supra-aural earphones
☐ Insert earphones
☐ Earmold+insert
☑ Speaker

Reliability:
○ Good ◉ Fair ○ Poor

SPEECH AUDIOMETRY

	Est. SII	PTA	SRT (dB HL)	SAT (dB HL)	Masking (dB HL)	Word Recognition %	Word Recognition dB HL	Word Recognition Masking (dB HL)
R	- - -	- - -						
L	- - -	- - -						
BC	- - -	- - -						
SF	- - -	- - -		>85				

Speech Reception Threshold (SRT):

Speech Awareness Threshold (SAT): speech & music

Word Recognition:

Presentation: ☐ Male ☑ Female ☑ Live Voice ☐ Recorded

IMMITTANCE MEASURES

TYMPANOMETRY PROBE FREQUENCY ☑ 226 Hz ☐ 1000 Hz

EAR	EQUIV CANAL VOL (cc)	PEAK PRESSURE (daPa)	STATIC ADMITTANCE (mmho)	GRADIENT (daPa)	DNT	CNT
RIGHT	.		.		☐	☐
LEFT	.		.		☐	☐

MIDDLE EAR MUSCLE REFLEX THRESHOLDS

PROBE EAR	STIMULUS EAR (MODE)	500 Hz	1000 Hz	2000 Hz	DNT	CNT
RIGHT	RIGHT (IPSI)				☐	☐
	LEFT (CONTRA)					
LEFT	LEFT (IPSI)				☐	☐
	RIGHT (CONTRA)					

DNT: Did not test CNT: Could not test

*** Auth (Verified) ***

OTHER TEST FINDINGS

Additional information could not be obtained due to limited patient attention.

INTERPRETATION OF AUDIOMETRY

RIGHT EAR:

☐ Normal hearing

☐ hearing loss.

LEFT EAR:

☐ Normal hearing

☐ hearing loss.

UNMASKED BONE (not ear-specific):

☐ Normal.

☐ Consistent with conductive component.

☐ Consistent with sensorineural component.

☐ Consistent with mixed hearing loss.

SOUNDFIELD (Loudspeaker: not ear-specific):

☐ Normal hearing for at least one ear

☑ Profound degree of hearing loss for at least one ear (the better hearing ear, if there is an ear difference).

INTERPRETATION OF IMMITTANCE

Ear	Equiv Canal Volume	Peak Pressure	Admittance	Gradient
Right				
Left				

TYMPANOMETRY

☐ Normal:

☐ Consistent with middle ear dysfunction:

☐ Consistent with patent PE tube or non-intact tympanic membrane:

☐ Consistent with Eustachian tube dysfunction:

MIDDLE EAR MUSCLE REFLEXES

☐ Normal:

☐ Consistent with cochlear pathology:

☐ Consistent with retrocochlear pathology:

☐ Consistent with facial nerve pathology:

COMMENTS AND RECOMMENDATIONS

See full narrative report in Powerchart - Documents\Clinical Documents\Clinic Notes\Audiology.

CPT Codes:
92626;

ICD Codes:
H90.3; Z87.898;

ASHLEIGH LEWKOWITZ, AuD

Date of Exam: 11-29-2016

ALDHAHERI , 5002094 : 6119961167

Boston Children's Hospital
300 Longwood Avenue
Boston, MA 02115

BCH MRN: **500-20-94**
Patient Name: **ALDHAHERI, ABDULLA KHALIFA**
DOB/Age/Sex: 2/18/2014 3 years Male

Admit Date: 1/26/2017
Discharge Date: 1/26/2017

Patient Location: Balance Prgm/Waltham
Patient Type: Outpatient
Financial #: 6120309534

Audiology

DOCUMENT NAME:	Vestibular and Balance Test
SERVICE DATE/TIME:	1/26/2017 10:35 EST
PERFORM INFORMATION:	ZHOU ScD,GUANGWEI (1/31/2017 10:37 EST)
SIGN INFORMATION:	BRODSKY MD,JACOB R (2/2/2017 16:59 EST); ZHOU ScD, GUANGWEI (1/31/2017 10:38 EST)
RESULT STATUS:	Auth (Verified)

Boston Children's Hospital
Until every child is well™

Balance and Vestibular Program
Boston Children's Hospital at Waltham
9 Hope Avenue, Waltham, MA 02453
Tel: 781-216-2799 Fax: 781-216-3155

VESTIBULAR & BALANCE TEST REPORT

DATE OF EVALUATION: 01/26/2017
NAME, DOB & MRN: Abdula Khalifa AlDhaheri, 02/18/2014, #500-20-94
REFERRED BY: Dr. Licameli/b Dr. Brodsky
REASON FOR TEST: Bilateral hearing loss. h/o hydropcephalus and CP, Pre-CI
TESTED & REPORTED BY: Guangwei Zhou, Sc.D., CCC-A

Impression: No indication of peripheral vestibular loss on either side but central loss can't be ruled out.

Videonystagmography (VNG) under observational camera:

Spontaneous nystagmus: none
Pursuit: not smooth
Optokinetic nystagmus: age appropriate

Rotational testing: under observational camera (0.04, and 0.16 Hz)

VOR responses: present with both CW and CCW rotations
Fixation-suppression of the VOR: abnormal

Tympanometry:

Left ear: normal pressure and mobility
Right ear: negative pressure (-170daPa) but normal mobility

Vestibular Evoked Myogenic Potential (VEMP)

Audiology

Stimuli: 500 Hz tone-bursts via insert phones
Cervical VEMP responses: present on both sides
Cervical VEMP thresholds: left = 75 dB nHL; right = 80 dB nHL

Reviewed by: Jacob Brodsky, M.D.

Attachment(s): 1/26/2017 10:35 EST Aldhaheri5002094VEMP.pdf

VESTIBULAR EVOKED POTENTIAL REPORT

CH: 5002094 6120309534
AlDhaheri,Abdulla Khalifa
DOB:2/18/14 + 971 506 676685
DOS:1/26/17 OTL

Patient:	**Aldhaheri, Abdulla**	*Gender:*	**Male**	*Physician:*	**CI**
ID#:	**5002094**	*Test date:*	**1/26/2017 1:03:20 PM**	*Tested by:*	
Birth date:	**2/18/2014**				
Results:					

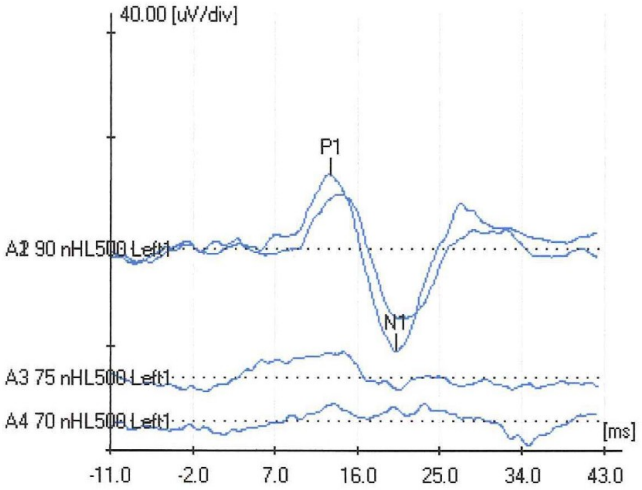

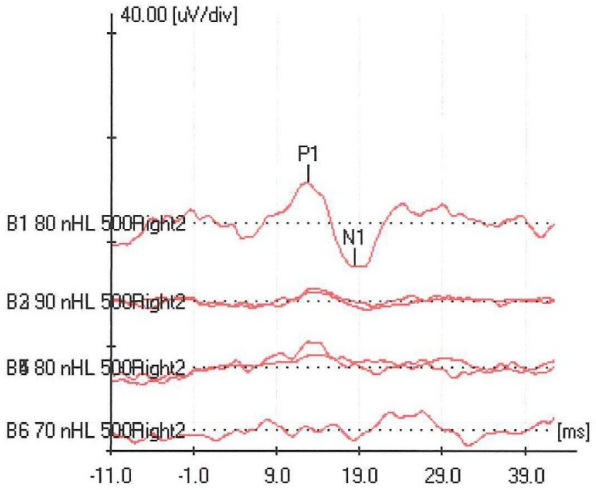

Latencies (ms)

Label Index	*P1*	*N1*	*P2*
A1	**13.04**	**20.22**	
B1	**12.62**	**18.35**	

Interlatencies (ms)

Label Index	*P1-N1*	*N1-P2*
A1	**-7.18**	
B1	**-5.73**	

Interamplitudes (uV)

Label Index	*P1-N1*	*N1-P2*
A1	**67.600**	
B1	**32.120**	

Stimulus Parameters

Label Index	*Intensity*	*Ear*	*Transducer*	*Insert Delay*	*Type*	*Frequency*	*Polarity*	*Ramp*	*Rise/Fall*	*Plateau*	*Rate*

Boston Children's Hospital
300 Longwood Avenue
Boston, MA 02115

BCH MRN: **500-20-94**
Patient Name: **ALDHAHERI, ABDULLA KHALIFA**
DOB/Age/Sex: 2/18/2014 3 years Male

Admit Date: 8/3/2017
Discharge Date: 8/3/2017

Patient Location: Balance Prgm/Waltham
Patient Type: Outpatient
Financial #: 6121171925

Audiology

DOCUMENT NAME:	Vestibular and Balance Test
SERVICE DATE/TIME:	8/3/2017 12:25 EDT
PERFORM INFORMATION:	ZHOU ScD,GUANGWEI (8/7/2017 12:27 EDT)
SIGN INFORMATION:	BRODSKY MD,JACOB R (8/8/2017 08:01 EDT); ZHOU ScD, GUANGWEI (8/7/2017 12:27 EDT)
RESULT STATUS:	Auth (Verified)

Boston Children's Hospital
Until every child is well™

Balance and Vestibular Program
Boston Children's Hospital at Waltham
9 Hope Avenue, Waltham, MA 02453
Tel: 781-216-2799 Fax: 781-216-3155

VESTIBULAR & BALANCE TEST REPORT

DATE OF EVALUATION: 08/03/2017
NAME, DOB & MRN: Abdula Khalifa AlDhaheri, 02/18/2014, #500-20-94
REFERRED BY: Dr. Licameli/b Dr. Brodsky
REASON FOR TEST: Bilateral hearing loss, s/p right CI
TESTED & REPORTED BY: Guangwei Zhou, Sc.D., CCC-A

Impression: Compared to pre-CI evaluation in January 2017, no significant change noted.

Videonystagmography (VNG) under observational camera:

Spontaneous nystagmus: none
Saccades: able to track targets
Pursuit: not smooth
Optokinetic nystagmus: age appropriate

Rotational testing: under observational camera (0.04, 0.08 and 0.16 Hz)

VOR responses: present with both CW and CCW rotations, stronger with CW rotations
Fixation-suppression of the VOR: abnormal

Vestibular Evoked Myogenic Potential (VEMP)

Stimuli: 500 Hz tone-bursts via insert phones
Cervical VEMP responses: present on both sides @ 90 dB nHL

Audiology

Reviewed by: Jacob Brodsky, M.D.

Attachment(s): 8/3/2017 12:25 EDT Aldhaheri5002094b.pdf

VESTIBULAR EVOKED POTENTIAL REPORT

CH: 5002094 6121171925
AlDhaheri,Abdulla Khalifa
DOB:2/18/14 + 971 506 676685
DOS:8/03/17 OTL

Patient:	**Aldhaheri, Abdulla**	*Gender:*	**Male**	*Physician:*	**CI**
ID#:	**5002094**	*Test date:*	**8/3/2017 2:39:14 PM**	*Tested by:*	
Birth date:	**2/18/2014**				
Results:					

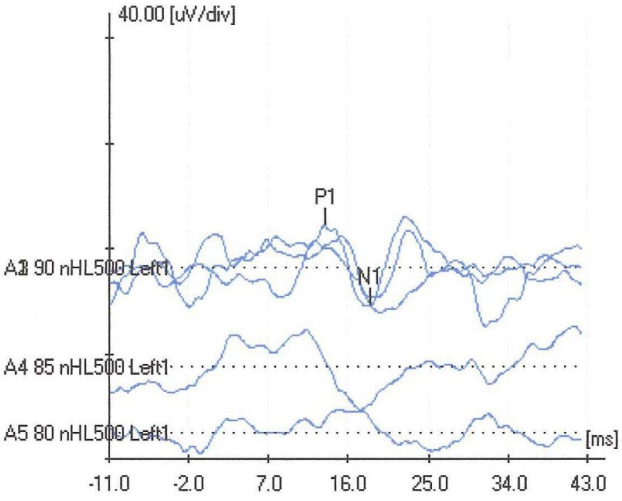

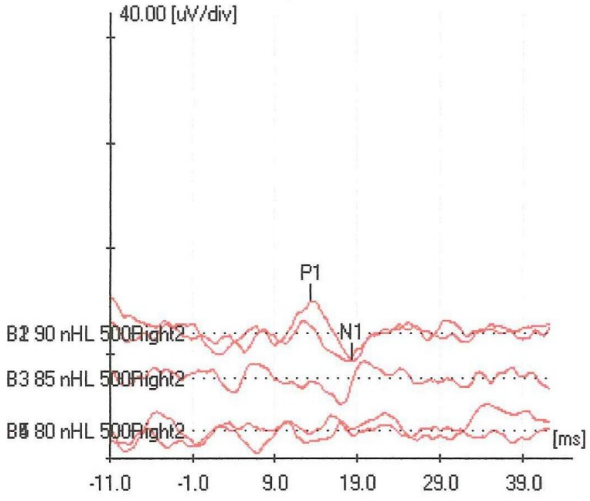

Latencies (ms)

Label Index	*P1*	*N1*	*P2*
A2	**13.46**	**18.45**	
B1	**13.35**	**18.35**	

Interlatencies (ms)

Label Index	*P1-N1*	*N1-P2*
A2	**-5.00**	
B1	**-5.00**	

Interamplitudes (uV)

Label Index	*P1-N1*	*N1-P2*
A2	**30.140**	
B1	**22.430**	

Boston Children's Hospital
300 Longwood Avenue
Boston, MA 02115

BCH MRN: **500-20-94**
Patient Name: **ALDHAHERI, ABDULLA KHALIFA**
DOB/Age/Sex: 2/18/2014 3 years Male

Admit Date: 4/5/2017
Discharge Date: 4/5/2017

Patient Location: Audiology Waltham
Patient Type: Outpatient
Financial #: 6120393847

Ambulatory Documentation

DOCUMENT NAME: Audiology Visit
SERVICE DATE/TIME: 3/27/2017 16:49 EDT
PERFORM INFORMATION: LEWKOWITZ AuD,ASHLEIGH (3/27/2017 16:53 EDT)
SIGN INFORMATION: LEWKOWITZ AuD,ASHLEIGH (3/27/2017 16:53 EDT)
RESULT STATUS: Auth (Verified)

Reason for Visit
Cochlear implant mapping, one month post-stim of right cochlear implant.

Session Narrative/HPI
NAME: Abdulla AlDhaheri
DOB: 2/18/2014
MR#: 500-20-94

DATE: 3/27/2017

RIGHT
IMPLANT: CI522
SURGERY DATE: 2/2/2017
INITIAL STIM: 2/21/2017
PROCESSOR(S): CP950 (Kanso) & CP910 (Nucleus 6)

AUDIOLOGIST: Ashleigh Lewkowitz, AuD, CCC-A, FAAA, PASC, CISC

*NOTES: One month post-stim of right ear. Mother continues to report increased auditory awareness and several new vocalizations, most notably a "nuh" sound. Abdulla appears to be tolerating his processor quite well and is wearing it with the hairclip alone for retention. Datalogging over the last 20 days reveals an average of 3.3 hours use per day with 28 coil-off events per day which account for an additional 3.3 hours per day of use time; essentially, Abdulla is utilizing his processor 6.6 hours per day but is only receiving consistent auditory input for about half of that . Mom does note that Abdulla was ill and also that the family was frequently traveling during the recorded period, both of which impacted device retention and use time.
Mom also reports Abdulla will be starting school in their local public school in Dedham in April but she is awaiting more information from the district regarding what Abdulla's specific program will entail.

*EVALUATION: Visual and tactile inspection of Abdulla's magnet site reveals no redness or swelling. Impedance measures are within appropriate limits and consistent with previous. Advanced neural response telemetry (NRT) using a PW of 37 is obtained for 5 of 22 electrodes with good morphology across the array. Today's NRT results are inserted into Abdulla's previous preferred 37 PW map (23), VRA/BOA are used to adjust T and C levels with fair-good reliability for two electrodes prior to fatigue. The conditioned play task is introduced with good success using live voice /ba ba ba/ and /sh sh sh/ stimuli and two testers.

Abdulla's right Kanso speech processor is configured as follows:

Problem List/Past Medical History
Ongoing
- Bronchopulmonary dysplasia
- Childhood asthma
- Cochlear implant in situ
- Developmental delay
- Feeding difficulties and mismanagement
- Hearing loss
- Sensorineural hearing loss, bilateral
- Spastic quadriplegic cerebral palsy
- Speech delay
- Wheeze

Historical
- No qualifying data

Procedure/Surgical History
Cochlear device implantation, with or without mastoidectomy (02/02/2017), Cochlear device implantation, with or without mastoidectomy (02/02/2017).

Social History
Assistive Technology Right - Audiology
- Hearing Device Cochlear Implant. Manufacturer Cochlear Americas. Model Internal: CI522; External: CP950 & CP910. Serial Number Internal: 1020170202749. Date Fit Surgery: 2/2/2017; Activation: 2/21/2017. Battery Size 675. Rechargeable Battery Lithium ion (CP910 only).

Basic Social History
- Living Arrangement Parent(s)/Guardian. Legal Guardian: Parent. Lives With: Mother, Father, Brother, nanny. Language Spoken at Home: English and Arabic.

Home/Environment
- Living situation: Home with assistance. Devices or Anatomic Adaptations: Ventriculoperitoneal shunt, Glasses, Hearing aides. Home equipment:

Ambulatory Documentation

*PROCESSOR CONFIGURATION(S):
RIGHT

P1	Map #24	500 Hz, PW37, ADRO; Home
P2	Map #-	-
P3	Map #-	-
P4	Map #-	-

*SUMMARY & RECOMMENDATIONS: Improved attention and engagement are observed following today's mapping changes. Mom is again counseled on realistic expectations for children in the first few months of implant use. Abdulla will return for follow-up in one week to include mapping of his CP910 speech processor.

I can be reached at 781-216-2265 or ashleigh.lewkowitz@childrens.harvard.edu for any questions/concerns regarding these findings and recommendations.

Ashleigh Lewkowitz, AuD, CCC-A, FAAA, PASC, CISC
Clinical Audiologist

Adaptive stroller, Ankle foot orthoses (AFO's).

Family History
Developmental delay: Brother.
Seizures: Cousin.

Boston Children's Hospital
300 Longwood Avenue
Boston, MA 02115

BCH MRN: **500-20-94**
Patient Name: **ALDHAHERI, ABDULLA KHALIFA**
DOB/Age/Sex: 2/18/2014 3 years Male

Admit Date: 3/7/2017
Discharge Date: 3/7/2017

Patient Location: Audiology Waltham
Patient Type: Outpatient
Financial #: 6120393496

Ambulatory Documentation

DOCUMENT NAME: Audiology Visit
SERVICE DATE/TIME: 3/7/2017 16:17 EST
PERFORM INFORMATION: LEWKOWITZ AuD,ASHLEIGH (3/9/2017 16:19 EST)
SIGN INFORMATION: LEWKOWITZ AuD,ASHLEIGH (3/9/2017 16:19 EST)
RESULT STATUS: Auth (Verified)

Reason for Visit
Cochlear implant mapping, two weeks post-stim of right ear.

Session Narrative/HPI
NAME: Abdulla AlDhaheri
DOB: 2/18/2014
MR#: 500-20-94

DATE: 3/7/2017

RIGHT
IMPLANT: CI522
SURGERY DATE: 2/2/2017
INITIAL STIM: 2/21/2017
PROCESSOR(S): CP950 (Kanso) & CP910 (Nucleus 6)

AUDIOLOGIST: Ashleigh Lewkowitz, AuD, CCC-A, FAAA, PASC, CISC

*NOTES: Two weeks post-stim of right ear. Mother reports some increased auditory awareness and improved processor retention with the pocket headband. She does note that, until two days ago, Abdulla would cry each time his processor was placed on his head and appeared to startle when first connected. He now seems to be tolerating his processor fairly well. Datalogging reveals an average of 6 hours use per day with 40 coil-off events per day. Mom reports Abdulla does seem to be responding to sounds and speech in the environment but has not yet begun to make new vocalizations like his brother has.

*EVALUATION: Visual and tactile inspection of Abdulla's magnet site reveals no redness or swelling; Mom is again counseled on the importance of at-home visual checks to ensure Abdulla's magnet and/or headband is not irritating his scalp. Impedance measures are within appropriate limits and consistent with previous. Neural response telemetry (NRT) is obtained for 9 of 22 electrodes with good morphology noted across the array. Rate is decreased to 500 Hz and PW to 37, VRA/BOA are used to check T and C levels with fair reliability.

Abdulla's right Kanso speech processor is configured as follows:

*PROCESSOR CONFIGURATION(S):
RIGHT

P1	Map #23	500 Hz, PW37, BOA/some VRA; Home
P2	Map #-	-

Problem List/Past Medical History
Ongoing
- Bronchopulmonary dysplasia
- Childhood asthma
- Cochlear implant in situ
- Developmental delay
- Feeding difficulties and mismanagement
- Hearing loss
- Sensorineural hearing loss, bilateral
- Spastic quadriplegic cerebral palsy
- Speech delay
- Wheeze

Historical
- No qualifying data

Procedure/Surgical History
Cochlear device implantation, with or without mastoidectomy (02/02/2017), Cochlear device implantation, with or without mastoidectomy (02/02/2017).

Social History
Assistive Technology Right - Audiology
- Hearing Device Cochlear Implant. Manufacturer Cochlear Americas. Model Internal: CI522; External: CP950 & CP910. Serial Number Internal: 1020170202749. Date Fit Surgery: 2/2/2017; Activation: 2/21/2017. Battery Size 675. Rechargeable Battery Lithium ion (CP910 only).

Basic Social History
- Living Arrangement Parent(s)/Guardian. Legal Guardian: Parent. Lives With: Mother, Father, Brother, nanny. Language Spoken at Home: English and Arabic.

Home/Environment
- Living situation: Home with assistance. Devices or Anatomic Adaptations: Ventriculoperitoneal shunt, Glasses, Hearing aides. Home equipment:

Ambulatory Documentation

P3	Map #-	-
P4	Map #-	-

*SUMMARY & RECOMMENDATIONS: With today's new map, Abdulla is noted to quiet and smile with intermittent attentiveness in response to speech and musical instruments in the mapping room; no adverse responses are observed for very loud sounds (i.e. clapping, /bababa/). Mom is again counseled on realistic expectations for children in the first few months of implant use. Abdulla will return for follow-up in two weeks; he will also see Nicole Salamy, CCC-SLP, following today's mapping appointment for speech-language therapy.

I can be reached at 781-216-2265 or ashleigh.lewkowitz@childrens.harvard.edu for any questions/concerns regarding these findings and recommendations.

Ashleigh Lewkowitz, AuD, CCC-A, FAAA, PASC, CISC
Clinical Audiologist

Adaptive stroller, Ankle foot orthoses (AFO's).

Family History

Developmental delay: Brother.
Seizures: Cousin.

Boston Children's Hospital
300 Longwood Avenue
Boston, MA 02115

BCH MRN: **500-20-94**
Patient Name: **ALDHAHERI, ABDULLA KHALIFA**
DOB/Age/Sex: 2/18/2014 3 years Male

Admit Date: 3/7/2017
Discharge Date: 3/7/2017

Patient Location: Audiology Waltham
Patient Type: Outpatient
Financial #: 6120393496

Ambulatory Documentation

DOCUMENT NAME: Audiology Visit
SERVICE DATE/TIME: 2/27/2017 08:16 EST
PERFORM INFORMATION: LEWKOWITZ AuD,ASHLEIGH (3/1/2017 08:44 EST)
SIGN INFORMATION: LEWKOWITZ AuD,ASHLEIGH (3/2/2017 08:45 EST)
RESULT STATUS: Auth (Verified)

Session Narrative/HPI

NAME: Abdulla AlDhaheri
DOB: 2/18/2014
MR#: 500-20-94

DATE: 2/27/2017

RIGHT
IMPLANT: CI522
SURGERY DATE: 2/2/2017
INITIAL STIM: 2/21/2017
PROCESSOR(S): CP950 (Kanso) & CP910 (CP910)

AUDIOLOGIST: Ashleigh Lewkowitz, AuD, CCC-A, FAAA, PASC, CISC

*NOTES: One week post-stim of right ear. Mother reports no noticeable responses to speech or environmental sound and notes considerable retention issues. Datalogging reveals 5 hours of Kanso use per day with an average of 40 coil-off events per day. He is wearing program 4 with no adverse responses noted.

*EVALUATION: Visual inspection of Abdulla's magnet site reveals no redness or swelling. Impedance measures are within normal limits and reduced from previous, consistent with one week of regular use. Neural response telemetry (NRT) is obtained for 8 of 22 electrodes and results inserted into the mapping screen. Pulse width is widened to 50 to maintain compliance and BOA/VRA used to evaluate T and C levels. Four progressive maps are generated and Abdulla's Kanso speech processor is programmed as follows:

*PROCESSOR CONFIGURATION(S):
RIGHT

P1	Map #15	new NRT, PW50 re: compliance, VRA/BOA Ts, live voice BOA Cs
P2	Map #16	+ 5 CU
P3	Map #17	+10 CU
P4	Map #18	Cs +2 CU, Ts dec x 3 CU

Problem List/Past Medical History

Ongoing
- Bronchopulmonary dysplasia
- Childhood asthma
- Cochlear implant in situ
- Developmental delay
- Feeding difficulties and mismanagement
- Hearing loss
- Sensorineural hearing loss, bilateral
- Spastic quadriplegic cerebral palsy
- Speech delay
- Wheeze

Historical
- No qualifying data

Social History

Assistive Technology Right - Audiology
- Hearing Device Cochlear Implant. Manufacturer Cochlear Americas. Model Internal: CI522; External: CP950 & CP910. Serial Number Internal: 1020170202749. Date Fit Surgery: 2/2/2017; Activation: 2/21/2017. Battery Size 675. Rechargeable Battery Lithium ion (CP910 only).

Basic Social History
- Living Arrangement Parent(s)/Guardian. Legal Guardian: Parent. Lives With: Mother, Father, Brother, nanny. Language Spoken at Home: English and Arabic.

Home/Environment
- Living situation: Home with assistance. Devices or Anatomic Adaptations: Ventriculoperitoneal shunt, Glasses, Hearing aides. Home equipment: Adaptive stroller, Ankle foot orthoses (AFO's).

Family History

Developmental delay: Brother.
Seizures: Cousin.

Ambulatory Documentation

*SUMMARY & RECOMMENDATIONS: With today's new maps, Abdulla is noted to quiet and shift his gaze in response to speech and clapping. Mom is counseled on appropriate use of the progressive programs and they will return for follow-up in one week. Abdulla is provided with a pocket headband today to aid retention of the Kanso with good success.

I can be reached at 781-216-2265 or ashleigh.lewkowitz@childrens.harvard.edu for any questions/concerns regarding these findings and recommendations.

Ashleigh Lewkowitz, AuD, CCC-A, FAAA, PASC, CISC
Clinical Audiologist

Boston Children's Hospital
300 Longwood Avenue
Boston, MA 02115

BCH MRN: **500-20-94**
Patient Name: **ALDHAHERI, ABDULLA KHALIFA**
DOB/Age/Sex: 2/18/2014 3 years Male

Admit Date: 2/28/2017
Discharge Date: 2/21/2017

Patient Location: Audiology
Patient Type: Outpatient
Financial #: 6120393469

Ambulatory Documentation

DOCUMENT NAME:	Audiology Visit
SERVICE DATE/TIME:	2/21/2017 09:23 EST
PERFORM INFORMATION:	LEWKOWITZ AuD,ASHLEIGH (2/22/2017 09:31 EST)
SIGN INFORMATION:	LEWKOWITZ AuD,ASHLEIGH (2/22/2017 09:31 EST)
RESULT STATUS:	Auth (Verified)

NAME: Abdulla AlDhaheri
DOB: 2/18/2014
MR#: 500-20-94

DATE: 2/21/2017

RIGHT
IMPLANT: CI522
SURGERY DATE: 2/2/2017
INITIAL STIM: 2/21/2017
PROCESSOR(S): Kanso & CP910

AUDIOLOGIST: Ashleigh Lewkowitz, AuD, CCC-A, FAAA, PASC, CISC

*BRIEF HISTORY: Abdulla AlDhaheri is here today for initial programming of his right Cochlear CI522 cochlear implant and Kanso external speech processor. His also has a CP910 speech processor which is not programmed today. Abdulla is from the United Arab Emirates and has a history of prematurity; he is one of a set of triplets delivered at 25 weeks, 5 days. Additionally, history is significant for spastic quadriplegia, cerebral palsy with superimposition of right hemiplegia, intracranial hemorrhage resulting in hydrocephalus necessitating shunt placement, vision impairment, bilateral hearing loss, and significant speech and developmental delays. Sedated auditory brainstem response (ABR) testing completed at Boston Children's on 10/31/2016 revealed bilateral auditory neuropathy spectrum disorder (ANSD). A trial period with bilateral amplification yielded no measureable benefit per parent report.

*EVALUATION: Abdulla is accompanied to today’s appointment by his mother, father, and brother; his brother is also having his cochlear implant activated today. The skin flap over the internal device shows no major irritation and slight residual swelling. Kanso magnet strength is increased to 3 for improved retention. Neural Response Telemetry (NRT) measures are attempted but discontinued when Abdulla becomes upset. T and C levels are set via behavioral observation to generate a conservative initial map.

Ambulatory Documentation

This map (#6) is placed into program 1. Progressively louder maps (#7), (#8), and (#9) are created and placed in programs 2, 3 and 4 respectively.
Abdulla's family is instructed to progress through the programs until he feels comfortable using program 4 by the time he returns for his appointment next week. Care, use, and maintenance of the implant and Remote Assistant are discussed. The family is also counseled on how to visually monitor the magnet site, realistic expectations, importance of consistent use, and the necessity of intensive speech and auditory therapy.

*SUMMARY AND RECOMMENDATIONS: Abdulla appears to be tolerating the implant and sounds fairly well. He is noted to quiet and smile in response to loud speech and environmental sounds, i.e. clapping. Abdulla is comfortably wearing program 1 (map #6) upon leaving the clinic with no adverse responses noted, he will return for follow-up in one week.

*MEDICAL WARNINGS/PRECAUTIONS: Abdulla's parents should distribute warning information (provided to family) to anyone that may need to take medical care of Abdulla to alert them to the presence of the internal device so they may take necessary precautions. These may include: pediatrician, school, and local emergency department. If Abdulla requires any medical attention related to the cochlear implant, please call the nursing line at 617.355.7147 during regular business hours or page the on-call ORL fellow.

I can be reached at 781-216-2265 or ashleigh.lewkowitz@childrens.harvard.edu for any questions/concerns regarding these findings and recommendations.

Ashleigh Lewkowitz, AuD, CCC-A, FAAA, PASC, CISC
Clinical Audiologist

Boston Children's Hospital

300 Longwood Avenue
Boston, MA 02115

BCH MRN: **500-20-94**
Patient Name: **ALDHAHERI, ABDULLA KHALIFA**
DOB/Age/Sex: 2/18/2014 3 years Male

Admit Date: 9/21/2017
Discharge Date: 9/21/2017

Patient Location: Audiology Waltham
Patient Type: Outpatient
Financial #: 6121609132

Ambulatory Documentation

DOCUMENT NAME:	Audiology Visit
SERVICE DATE/TIME:	10/5/2017 16:30 EDT
PERFORM INFORMATION:	LEWKOWITZ AuD,ASHLEIGH (10/5/2017 16:33 EDT)
SIGN INFORMATION:	LEWKOWITZ AuD,ASHLEIGH (10/5/2017 16:33 EDT)
RESULT STATUS:	Auth (Verified)

It is imperative that Abdulla return for mapping and testing IN 12 MONTHS to ensure appropriate cochlear implant device function and foster successful outcomes; please diregard the erroneously stated 'three months' in the Audiology Visit note dated 9/21/2017.

Boston Children's Hospital
300 Longwood Avenue
Boston, MA 02115

BCH MRN: **500-20-94**
Patient Name: **ALDHAHERI, ABDULLA KHALIFA**
DOB/Age/Sex: 2/18/2014 3 years Male

Admit Date: 9/21/2017
Discharge Date: 9/21/2017

Patient Location: Audiology Waltham
Patient Type: Outpatient
Financial #: 6121609132

Ambulatory Documentation

DOCUMENT NAME: Audiology Visit
SERVICE DATE/TIME: 9/21/2017 16:04 EDT
PERFORM INFORMATION: LEWKOWITZ AuD,ASHLEIGH (10/5/2017 16:19 EDT)
SIGN INFORMATION: LEWKOWITZ AuD,ASHLEIGH (10/5/2017 16:19 EDT)
RESULT STATUS: Auth (Verified)

Reason for Visit
Routine mapping and testing of right cochlear implant.

Session Narrative/HPI
NAME: Abdulla AlDhaheri
DOB: 2/18/2014
MR#: 500-20-94

DATE: 9/21/2017

RIGHT
IMPLANT: CI522
SURGERY DATE: 2/2/2017
INITIAL STIM: 2/21/2017
PROCESSOR(S): CP950 (Kanso) & CP910 (Nucleus 6)

AUDIOLOGIST: Ashleigh Lewkowitz, AuD, CCC-A, FAAA, PASC, CISC

*NOTES: 7 months post-stim of right ear. Mom reports Abdulla has been wearing his CP910 speech processor fairly consistently at home since he was discharged from the ICU 10 days ago; datalogging reveals 5.2 hours of use per day which is a significant improvement over previous visits. Mom does note Abdulla seems to respond to speech and environmental sounds only sporadically with his processor in place but does seem to be tolerating it quite well.

*EVALUATION: Visual and listening checks of Abdulla's CP910 speech processor reveal it to be in good working order. Visual inspection of the Kanso processor reveals it to be in good condition; Mom reports no further issues with orange blinking since it was determined Abdulla and his brother's Kansos had been inadvertently mixed up.
Visual and tactile inspections of Abdulla's magnet site reveal no redness or swelling. Impedance measures are within appropriate limits and decreased from previous, consistent with increased wear time. Prior to mapping, Abdulla is evaluated in soundfield and found to have a speech awareness threshold (SAT) at 40 dB HL. Reliable responses for warble tones cannot be obtained prior to Abdulla becoming fatigued.
T and C levels are rechecked using visually reinforced audiometry and behavioral observation; conditioned play is again attempted but discontinued due to inability to condition. Clear behavioral changes are noted in response to speech and musical instruments following today's mapping adjustments.

Abdulla's right CP910 and CP950 speech processors are configured as follows:

*PROCESSOR CONFIGURATION(S):
RIGHT

This Visit Problems
1. Cochlear implant in situ
2. Sensorineural hearing loss, bilateral

Procedure/Surgical History
Cochlear device implantation, with or without mastoidectomy (02/02/2017), Cochlear device implantation, with or without mastoidectomy (02/02/2017).

Social History
Assistive Technology Right - Audiology
Hearing Device Cochlear Implant. Manufacturer Cochlear Americas. Model Internal: CI522; External: CP950 & CP910. Serial Number Internal: 1020170202749. Date Fit Surgery: 2/2/2017; Activation: 2/21/2017. Battery Size 675. Rechargeable Battery Lithium ion (CP910 only).
Basic Social History
Living Arrangement Parent(s)/Guardian. Legal Guardian: Parent. Lives With: Mother, Father, Brother, nanny. Language Spoken at Home: English and Arabic.
Home/Environment
Living situation: Home with assistance. Devices or Anatomic Adaptations: Ventriculoperitoneal shunt, Glasses, Hearing aides. Home equipment: Adaptive stroller, Ankle foot orthoses (AFO's).

Family History
Developmental delay: Brother.
Seizures: Cousin.

Ambulatory Documentation

P1	Map #37	500 Hz, 50 PW, BOA/VRA Ts/Cs, increased from previous; ASC+ADRO
P2	Map #-	-
P3	Map #-	-
P4	Map #-	-

*SUMMARY & RECOMMENDATIONS: Abdulla and his family will be returning to the UAE at the end of this month; it is imperative that he return for repeat mapping and testing in three months to ensure appropriate cochlear implant function and foster successful outcomes.

I can be reached at 781-216-2265 or ashleigh.lewkowitz@childrens.harvard.edu for any questions/concerns regarding these findings and recommendations.

Ashleigh Lewkowitz, AuD, CCC-A, FAAA, PASC, CISC
Clinical Audiologist

Boston Children's Hospital
300 Longwood Avenue
Boston, MA 02115

BCH MRN: **500-20-94**
Patient Name: **ALDHAHERI, ABDULLA KHALIFA**
DOB/Age/Sex: 2/18/2014 3 years Male

Admit Date: 9/11/2017
Discharge Date: 9/11/2017

Patient Location: Audiology Waltham
Patient Type: Outpatient
Financial #: 6120784940

Ambulatory Documentation

DOCUMENT NAME: Audiology Visit
SERVICE DATE/TIME: 9/11/2017 08:10 EDT
PERFORM INFORMATION: LEWKOWITZ AuD,ASHLEIGH (9/12/2017 08:22 EDT)
SIGN INFORMATION: LEWKOWITZ AuD,ASHLEIGH (9/18/2017 14:02 EDT)
RESULT STATUS: Auth (Verified)

Reason for Visit
Routine mapping and testing of right cochlear implant.

Session Narrative/HPI
NAME: Abdulla AlDhaheri
DOB: 2/18/2014
MR#: 500-20-94

DATE: 9/11/2017

RIGHT
IMPLANT: CI522
SURGERY DATE: 2/2/2017
INITIAL STIM: 2/21/2017
PROCESSOR(S): CP950 (Kanso) & CP910 (Nucleus 6)

AUDIOLOGIST: Ashleigh Lewkowitz, AuD, CCC-A, FAAA, PASC, CISC

*NOTES: 6 months post-stim of right ear. Earlier today Abdulla was discharged from inpatient care at Boston Children's Hospital following a one month admission for shunt malfunction with subsequent revision. Mom states he has not worn his speech processor at all during his admission. Prior to his hospitalization, he was using both the Kanso and Nucleus 6 processors interchangeably; as such, accuracy of datalogging cannot be assured. Mother also notes Abdulla's Kanso processor, as well as his brother's Kanso processor, have been blinking orange when on the head despite both having just been replaced.

*EVALUATION: Visual and listening checks of Abdulla's Nucleus 6 speech processor reveal it to be in good working order. Visual inspection of the Kanso processor reveals it to be in good condition; however, during the course of troubleshooting it is noted that Abdulla's Kanso is in his brother's case and vice versa. It is possible the orange blinking that has been observed at home is due to the devices being on the wrong user. Abdulla's Kanso is reset in the software today prior to downloading programs and Mom is reinstructed on keeping the boys' devices separate.

Visual and tactile inspections of Abdulla's magnet site reveal no redness or swelling. Impedance measures are within appropriate limits and slightly higher than previous, consistent with decreased wear time. Repetition of neural response telemetry (NRT) is attempted today but discontinued as Abdulla continues to show adverse responses to electrode-specific stimulation. Rate is set to 500 Hz, PW widened to 50, Ts/Cs measured using two-tester BOA/VRA; reliable BOA/VRA responses are noted at suprathreshold levels and are decreased for use in the map. Upon going live with today's

This Visit Problems
1. Hearing loss
2. Cochlear implant in situ

Procedure/Surgical History
Cochlear device implantation, with or without mastoidectomy (02/02/2017), Cochlear device implantation, with or without mastoidectomy (02/02/2017).

Social History
Assistive Technology Right - Audiology
Hearing Device Cochlear Implant. Manufacturer Cochlear Americas. Model Internal: CI522; External: CP950 & CP910. Serial Number Internal: 1020170202749. Date Fit Surgery: 2/2/2017; Activation: 2/21/2017. Battery Size 675. Rechargeable Battery Lithium ion (CP910 only).
Basic Social History
Living Arrangement Parent(s)/Guardian. Legal Guardian: Parent. Lives With: Mother, Father, Brother, nanny. Language Spoken at Home: English and Arabic.
Home/Environment
Living situation: Home with assistance. Devices or Anatomic Adaptations: Ventriculoperitoneal shunt, Glasses, Hearing aides. Home equipment: Adaptive stroller, Ankle foot orthoses (AFO's).

Family History
Developmental delay: Brother.
Seizures: Cousin.

Ambulatory Documentation

new map, Abdulla is noted to look up and smile. When the map is deactivated, he looks back and forth from the computer keyboard to the clinician until stimulation is re-enabled. This pattern of behavior is repeated several times. No adverse responses to speech or environmental sounds are noted.

Abdulla's right Kanso speech processor is configured as follows:

*PROCESSOR CONFIGURATION(S):
RIGHT

P1	Map #35	500 Hz, 50 PW, BOA/VRA Ts/Cs; ASC+ADRO
P2	Map #-	-
P3	Map #-	-
P4	Map #-	-

*SUMMARY & RECOMMENDATIONS: Abdulla and his family will be returning to the UAE at the end of this month; it is recommended he be seen once more prior to departure to ensure comfort of settings and functionality of equipment. He is scheduled to return on 9/21/2017.

I can be reached at 781-216-2265 or ashleigh.lewkowitz@childrens.harvard.edu for any questions/concerns regarding these findings and recommendations.

Ashleigh Lewkowitz, AuD, CCC-A, FAAA, PASC, CISC
Clinical Audiologist

Boston Children's Hospital
300 Longwood Avenue
Boston, MA 02115

BCH MRN: **500-20-94**
Patient Name: **ALDHAHERI, ABDULLA KHALIFA**
DOB/Age/Sex: 2/18/2014 3 years Male

Admit Date: 8/3/2017
Discharge Date: 8/3/2017

Patient Location: Balance Prgm/Waltham
Patient Type: Outpatient
Financial #: 6121171925

Ambulatory Documentation

DOCUMENT NAME:	Audiology Visit
SERVICE DATE/TIME:	8/3/2017 10:40 EDT
PERFORM INFORMATION:	ZHOU ScD,GUANGWEI (8/4/2017 10:41 EDT)
SIGN INFORMATION:	ZHOU ScD,GUANGWEI (8/4/2017 10:41 EDT)
RESULT STATUS:	Auth (Verified)

Patient had cochlear implantation (CI) surgery for the right ear on 2/2/2017. He returned today for post-CI vestibular evaluation.

Videonystagmography (VNG), rotation and cervical Vestibular Evoked Myogenic Potential (cVEMP) testing were done. Final report will be posted in powerchart under Diagnostic Studies View: Audiology and Vestibular/Balance

Guangwei Zhou, ScD, CCC-A
Clinical Director, Balance and Vestibular Program
Department of Otolaryngology and Communication Enhancement
Boston Children's Hospital at Waltham

Boston Children's Hospital
300 Longwood Avenue
Boston, MA 02115

BCH MRN: **500-20-94**
Patient Name: **ALDHAHERI, ABDULLA KHALIFA**
DOB/Age/Sex: 2/18/2014 3 years Male

Admit Date: 7/24/2017
Discharge Date: 7/24/2017

Patient Location: Audiology Waltham
Patient Type: Outpatient
Financial #: 6120784931

Ambulatory Documentation

DOCUMENT NAME: Audiology Visit
SERVICE DATE/TIME: 7/24/2017 09:49 EDT
PERFORM INFORMATION: LEWKOWITZ AuD,ASHLEIGH (7/31/2017 09:51 EDT)
SIGN INFORMATION: LEWKOWITZ AuD,ASHLEIGH (7/31/2017 09:51 EDT)
RESULT STATUS: Auth (Verified)

Reason for Visit
Routine mapping of right cochlear implant

Session Narrative/HPI
NAME: Abdulla AlDhaheri
DOB: 2/18/2014
MR#: 500-20-94

DATE: 7/24/2017

RIGHT
IMPLANT: CI522
SURGERY DATE: 2/2/2017
INITIAL STIM: 2/21/2017
PROCESSOR(S): CP950 (Kanso) & CP910 (Nucleus 6)

AUDIOLOGIST: Ashleigh Lewkowitz, AuD, CCC-A, FAAA, PASC, CISC

*NOTES: 5 months post-stim of right ear. Mother continues to report Abdulla is making new sounds and will try to copy sounds that are made to him by others; however, he still cries briefly when the processor is first placed on his head. Abdulla arrives today wearing his newly replaced Nucleus 6 speech processor; his Kanso is reported to be non-functional and has been RMAd. Troubleshooting reveals the Kanso to be working but the battery door to be loose. Abdulla and his family will be returning home to the UAE later this summer.

*EVALUATION: Booth testing is attempted at the start of today's visit but Abdulla's Nucleus 6 processor is noted to be non-functional. Troubleshooting reveals the port for the coil cable to be rotated in the body of the processor with marks on the cable coil plug itself suggest it has been twisted into/out of place rather than pushed/pulled. Changing out the cable does not resolve the issue; as such, Abdulla's processor and cable are again RMAd and his Kanso is used for mapping despite the loose battery door. Visual and tactile inspection of Abdulla's magnet site reveals no redness or swelling.

Impedance measures are within appropriate limits and consistent with previous. Ts/Cs decreased slightly, soft start increased to 30 seconds. With today's changes, no crying or other adverse responses are noted upon going live and Abdulla attempts to repeat /ba ba ba/ and /m/ when given an auditory-visual model.

Abdulla's right Kanso speech processor is configured as follows:

*PROCESSOR CONFIGURATION(S):
RIGHT

This Visit Problems
1. Cochlear implant in situ
2. Sensorineural hearing loss, bilateral

Procedure/Surgical History
Cochlear device implantation, with or without mastoidectomy (02/02/2017), Cochlear device implantation, with or without mastoidectomy (02/02/2017).

Social History
Assistive Technology Right - Audiology
Hearing Device Cochlear Implant. Manufacturer Cochlear Americas. Model Internal: CI522; External: CP950 & CP910. Serial Number Internal: 1020170202749. Date Fit Surgery: 2/2/2017; Activation: 2/21/2017. Battery Size 675. Rechargeable Battery Lithium ion (CP910 only).
Basic Social History
Living Arrangement Parent(s)/Guardian. Legal Guardian: Parent. Lives With: Mother, Father, Brother, nanny. Language Spoken at Home: English and Arabic.
Home/Environment
Living situation: Home with assistance. Devices or Anatomic Adaptations: Ventriculoperitoneal shunt, Glasses, Hearing aides. Home equipment: Adaptive stroller, Ankle foot orthoses (AFO's).

Family History
Developmental delay: Brother.
Seizures: Cousin.

Ambulatory Documentation

P1	Map #30	dec Ts/Cs, DR 35, 30 second soft start; ADRO
P2	Map #-	-
P3	Map #-	-
P4	Map #-	-

*SUMMARY & RECOMMENDATIONS: Abdulla will return in one month for booth testing or sooner should concerns arise.

I can be reached at 781-216-2265 or ashleigh.lewkowitz@childrens.harvard.edu for any questions/concerns regarding these findings and recommendations.

Ashleigh Lewkowitz, AuD, CCC-A, FAAA, PASC, CISC
Clinical Audiologist

Boston Children's Hospital

300 Longwood Avenue
Boston, MA 02115

BCH MRN: **500-20-94**
Patient Name: **ALDHAHERI, ABDULLA KHALIFA**
DOB/Age/Sex: 2/18/2014 3 years Male

Admit Date: 8/15/2017
Discharge Date: 9/11/2017

Patient Location: 09 NorthWest 9204 A
Patient Type: Inpatient
Financial #: 6121467356

Radiology

ACCESSION	EXAM DATE/TIME	PROCEDURE	ORDERING PROVIDER	STATUS
RA-17-0161306	9/8/2017 11:27 EDT	XR-Shunt Series Study	ALEXOPOULOS MD, GEORGIOS	Modified

CDM code
2267000005
2267000047
2267000315
2267000323
F70250
F70360
F71020
F74020

Reason For Exam
(XR-Shunt Series Study) evaluate shunt

Report

.

SHUNT SERIES, AP AND LATERAL RADIOGRAPHS OF THE HEAD, NECK, CHEST, ABDOMEN, AND PELVIS REGIONS.

INDICATION: This is a 3-year-old male with a ventriculoperitoneal shunt catheter.

FINDINGS: There is a ventriculoperitoneal shunt catheter projecting over the left frontoparietal region. There is a radiolucent reservoir projecting over the parietal bone. The catheter portions which connect to the reservoir appear appropriately aligned. The shunt catheter courses into the left side of the neck and chest, crosses midline into the right abdomen, an and there is redundant catheter tubing which terminates in the left hemiabdomen. There is no evidence of shunt kinking or discontinuity. There is a right upper cavity PICC terminating at the cavoatrial junction. Lung volumes are low and there is multifocal atelectasis. Bowel gas pattern is nonobstructive . Spinal dysraphic defect is noted over the lumbosacral spine and there is a cochlear implant projecting over the right skull. Focal lucencies overlying the parietal and frontal bones near the vertex are likely postsurgical.

Radiology

ACCESSION	EXAM DATE/TIME	PROCEDURE	ORDERING PROVIDER	STATUS
RA-17-0161306	9/8/2017 11:27 EDT	XR-Shunt Series Study	ALEXOPOULOS MD, GEORGIOS	Modified

Report

IMPRESSION: Intact ventriculoperitoneal shunt tubing.

***** *Final Report**

Dictated by: BIXBY MD, SARAH D 09/08/2017 11:37

Verified by: BIXBY MD, SARAH D 09/08/2017 11:45

Boston Children's Hospital
300 Longwood Avenue
Boston, MA 02115

BCH MRN: **500-20-94**
Patient Name: **ALDHAHERI, ABDULLA KHALIFA**
DOB/Age/Sex: 2/18/2014 3 years Male

Admit Date: 2/2/2017
Discharge Date: 2/3/2017

Patient Location: 10 NorthWest 1001 A
Patient Type: Observation
Financial #: 6120300773

Radiology

ACCESSION	EXAM DATE/TIME	PROCEDURE	ORDERING PROVIDER	STATUS
RA-17-0019493	2/2/2017 12:13 EST	XR-Skull 3 Views or Less	LICAMELI MD,GREG R	Modified

CDM code
2267000315
F70250

Reason For Exam
(XR-Skull 3 Views or Less) cochlear implant

Report

.

HISTORY: 35-month-old male cochlear implant

COMPARISON:
12/27/2016

EXAMINATION:XR-Skull 3 Views or Less

FINDINGS:
Again seen is a left parietal approach ventriculostomy catheter with shunt catheter tubing along the left neck. Portions of an endotracheal tube are seen.
New from the prior examinations is a cochlear implant overlying the right side of the skull.
The electrode of the cochlear implant projects over the region of the inner ear with an approximate 270 degree turn of the electrode tip .

***** *Final Report*****

Dictated by: CONNOLLY MD, SUSAN A 02/02/2017 12:15

Verified by: CONNOLLY MD, SUSAN A 02/03/2017 12:49

Boston Children's Hospital

300 Longwood Avenue
Boston, MA 02115

BCH MRN: **500-20-94**
Patient Name: **ALDHAHERI, ABDULLA KHALIFA**
DOB/Age/Sex: 2/18/2014 3 years Male

Admit Date: 12/27/2016
Discharge Date: 12/27/2016

Patient Location: X-Ray Boston
Patient Type: Outpatient
Financial #: 6120164545

Radiology

ACCESSION	EXAM DATE/TIME	PROCEDURE	ORDERING PROVIDER	STATUS
RA-16-0238389	12/27/2016 20:14 EST	XR-Skull 3 Views or Less	DRIVER MD,JOSEPH	Modified

CDM code
2267000315
F70250

Reason For Exam
(XR-Skull 3 Views or Less) shunt

Report

STUDY: Lateral Skull View

HISTORY: Skull radiograph after medros valve resetting

COMPARISON: Prior study from today.

FINDINGS: IMPRESSION: The medros valve setting is now between 100-110 mm H2O. Finding was discussed with Dr. Joe Driver by Dr. Alexei Kudla, on the phone at 20:30 p.m. on 27 December 2016, 2 minutes after this current findings.

I, the teaching physician, have reviewed the images with the trainee and agree with the findings

***** *Final Report*****

Dictated by: KUDLA MD, ALEXEI U 12/27/2016 20:16

Verified by: LEE MD, MPH, EDWARD Y 12/27/2016 20:44

Boston Children's Hospital

300 Longwood Avenue
Boston, MA 02115

BCH MRN: **500-20-94**
Patient Name: **ALDHAHERI, ABDULLA KHALIFA**
DOB/Age/Sex: 2/18/2014 3 years Male

Admit Date: 12/12/2016
Discharge Date: 12/12/2016

Patient Location: Neurosurgery Foundation
Patient Type: Outpatient
Financial #: 6119954193

Radiology

ACCESSION	EXAM DATE/TIME	PROCEDURE	ORDERING PROVIDER	STATUS
RA-16-0228621	12/12/2016 16:01 EST	XR-Skull 3 Views or Less	BIRCH CPNP,ASHLEY K	Modified

CDM code
2267000315
F70250

Reason For Exam
(XR-Skull 3 Views or Less) check medos valve setting, hydrocephalus

Report

.

STUDY: Single view of the skull. Compared to the study done earlier today.

HISTORY: 33-month-old status post resetting of the medos valve.

IMPRESSION: The Medos valve setting reads 100 mm H2O.

***** *Final Report*****

Dictated by: PEREZ-ROSSELLO MD, JEANNETT12/12/2016 16:04

Verified by: PEREZ-ROSSELLO MD, JEANNETT12/12/2016 16:06

Boston Children's Hospital

300 Longwood Avenue
Boston, MA 02115

BCH MRN: **500-20-94**
Patient Name: **ALDHAHERI, ABDULLA KHALIFA**
DOB/Age/Sex: 2/18/2014 3 years Male

Admit Date: 10/28/2016
Discharge Date: 10/28/2016

Patient Location: MRI Radiology
Patient Type: Outpatient
Financial #: 6119696389

Radiology

ACCESSION	EXAM DATE/TIME	PROCEDURE	ORDERING PROVIDER	STATUS
RA-16-0197589	10/28/2016 11:11 EDT	XR-Skull 3 Views or Less	COULTER MD,DAVID L	Modified

CDM code
2267000315
F70250

Reason For Exam
(XR-Skull 3 Views or Less) XR for Medos Valve Setting (Post-MRI)

Report

.

INDICATION: 2-year-old boy status post MRI. Assess Medos valve setting.

TECHNIQUE: Single radiograph of the skull, as per departmental protocol for assessment of Medos valve position, in comparison to one performed on 7:20 AM.

FINDINGS: The Medos valve position is approximately 70 mmHg. The ventricular catheter is again seen. The radiolucent reservoir is approximately 2.5 cm in length, similar.

***** *Final Report*****

Dictated by: TSAI MD, ANDY 10/28/2016 10:16

Verified by: TSAI MD, ANDY 10/28/2016 10:21

Boston Children's Hospital
300 Longwood Avenue
Boston, MA 02115

BCH MRN: **500-20-94**
Patient Name: **ALDHAHERI, ABDULLA KHALIFA**
DOB/Age/Sex: 2/18/2014 3 years Male

Admit Date: 8/15/2017
Discharge Date: 9/11/2017

Patient Location: 09 NorthWest 9204 A
Patient Type: Inpatient
Financial #: 6121467356

Radiology

ACCESSION	EXAM DATE/TIME	PROCEDURE	ORDERING PROVIDER	STATUS
RA-17-0147605	8/17/2017 19:21 EDT	XR-Chest 1 View	WALTON CPNP,TRACY MARIE	Modified

CDM code
2267000043
F71010

Reason For Exam
(XR-Chest 1 View) PICC placement in the OR

Report

CHEST RADIOGRAPH

HISTORY: -Year-old boy with a history of prematurity, diminished breath sounds.

TECHNIQUE: Portable supine frontal view of the chest.

COMPARISON: Multiple prior chest radiographs, most recent dated 8/17/2017.

FINDINGS:

New right upper extremity PICC is seen with tip projecting over the cavoatrial junction.

Endotracheal tube projects over the distal trachea. Enteric tube is seen to course below the diaphragm with the tip overlying the left upper quadrant in the region of the stomach. Previously seen left VP shunt is no longer visualized.

Low lung volumes. Redemonstration of bibasilar opacities, most confluent in the retrocardiac region. There is no pleural effusion or pneumothorax. Similar mild vascular congestion. The cardiothymic silhouette is not significantly changed.

IMPRESSION:

Since prior film of same date:
1.Low lung volumes. Redemonstration of bibasilar opacities, most confluent in the retrocardiac region, nonspecific, may reflect

Radiology

ACCESSION	EXAM DATE/TIME	PROCEDURE	ORDERING PROVIDER	STATUS
RA-17-0147605	8/17/2017 19:21 EDT	XR-Chest 1 View	WALTON CPNP,TRACY MARIE	Modified

Report

atelectasis or infection. Attention on follow-up is recommended.
2.Similar mild pulmonary vascular congestion.
3.Tubes and lines, as described above.

***** *Final Report*****

Dictated by: WINANT MD, ABBEY J 08/17/2017 19:54

Verified by: WINANT MD, ABBEY J 08/17/2017 19:56

Boston Children's Hospital
300 Longwood Avenue
Boston, MA 02115

BCH MRN: **500-20-94**
Patient Name: **ALDHAHERI, ABDULLA KHALIFA**
DOB/Age/Sex: 2/18/2014 3 years Male

Admit Date: 8/15/2017
Discharge Date: 9/11/2017

Patient Location: 09 NorthWest 9204 A
Patient Type: Inpatient
Financial #: 6121467356

Radiology

ACCESSION	EXAM DATE/TIME	PROCEDURE	ORDERING PROVIDER	STATUS
RA-17-0145907	8/15/2017 21:09 EDT	XR-Chest 1 View	O'HALLORAN MD, AMANDA J	Modified

CDM code
2267000043
F71010

Reason For Exam
(XR-Chest 1 View) intubation, s/p transfer from OR, check ETT placement and lung fields

Report

CHEST RADIOGRAPH.

INDICATION: 3-year-old male with history of prematurity (born at 25 weeks of gestation), cerebral palsy and seizures, status post intubation and ventriculoperitoneal shunt placement. Check endotracheal tube placement lung fields.

COMPARISON: Multiple prior chest radiographs, most recent dated 8/15/2017

Technique: Frontal portable upright radiograph of the chest.

FINDINGS:

Endotracheal tube is projected over the midthoracic trachea. Nasogastric tube is seen with its side port and distal tip projected over the body and antropyloric region of the stomach respectively. Partially visualized VP shunt is seen coursing craniocaudally over the left hemithorax and left hemiabdomen with its distal course out of the field-of-view but the distal tip terminating within the mid abdomen. No evidence of kinking or discontinuity of the visualized catheter is seen.

The lung volumes are low, similar to prior imaging. There is unchanged cardiothymic silhouette. No pleural effusion or pneumothorax is seen. There is mild bibasilar segmental atelectasis, most prominent within the retrocardiac region. No pulmonary edema is present.

IMPRESSION:

Radiology

ACCESSION	EXAM DATE/TIME	PROCEDURE	ORDERING PROVIDER	STATUS
RA-17-0145907	8/15/2017 21:09 EDT	XR-Chest 1 View	O'HALLORAN MD, AMANDA J	Modified

Report

1.Mild bibasilar atelectasis, most prominent in the retrocardiac region.
2.Lines and tubes as outlined above.

I, the teaching physician, have reviewed the images with the trainee and agree with the findings

***** *Final Report*****

Dictated by: LAUR MD, OLGA 08/16/2017 00:45

Verified by: DIPERNA MD, STEPHANIE A 08/16/2017 09:27

Boston Children's Hospital

300 Longwood Avenue
Boston, MA 02115

BCH MRN: **500-20-94**
Patient Name: **ALDHAHERI, ABDULLA KHALIFA**
DOB/Age/Sex: 2/18/2014 3 years Male

Admit Date: 11/14/2016
Discharge Date: 11/15/2016

Patient Location: Emergency Department 49 .
Patient Type: Emergency
Financial #: 6119941933

Radiology

ACCESSION	EXAM DATE/TIME	PROCEDURE	ORDERING PROVIDER	STATUS
RA-16-0209856	11/14/2016 19:55 EST	XR-Chest 2 Views	FARRELL MD,CAITLIN A	Modified

CDM code
2267000047
F71020

Reason For Exam
(XR-Chest 2 Views) 2yo M w/ complex PMH ex-25wk, cerebral palsy, hydrocephalus, VPS, here w/ fever

Report

.

CHEST RADIOGRAPH 11/14/2016 1956 hours

INDICATION: 32-month-old male presents to the emergency department with fever. Past medical history includes cerebral palsy and hydrocephalus with ventriculoperitoneal shunt

COMPARISON STUDIES: Radiograph of the entire spine from 9/16/2016

TECHNIQUE: Frontal and lateral views of the chest

FINDINGS:

There is a linear radiodensity projecting vertically over the left neck, hemithorax and upper abdomen reflecting the ventriculoperitoneal shunt catheter without kink or discontinuity.

There are low lung volumes.
There is no focal airspace consolidation.
There is no pneumothorax.
There is no pleural effusion.
The mediastinal and cardiac contours are unchanged and remain within normal limits.

IMPRESSION:
Low lung volumes with no focal consolidation.

Radiology

ACCESSION	EXAM DATE/TIME	PROCEDURE	ORDERING PROVIDER	STATUS
RA-16-0209856	11/14/2016 19:55 EST	XR-Chest 2 Views	FARRELL MD,CAITLIN A	Modified

Report

I, the teaching physician, have reviewed the images with the trainee and agree with the findings

***** *Final Report*****

Dictated by: HECHAVARRIA MD, DANIEL 11/14/2016 20:14

Verified by: CALLAHAN MD, MICHAEL J 11/15/2016 15:51

Boston Children's Hospital

300 Longwood Avenue
Boston, MA 02115

BCH MRN: **500-20-94**
Patient Name: **ALDHAHERI, ABDULLA KHALIFA**
DOB/Age/Sex: 2/18/2014 3 years Male

Admit Date: 9/20/2017
Discharge Date: 9/20/2017

Patient Location: Cerebral Palsy
Patient Type: Outpatient
Financial #: 6121656015

Radiology

ACCESSION	EXAM DATE/TIME	PROCEDURE	ORDERING PROVIDER	STATUS
RA-17-0169348	9/20/2017 13:54 EDT	XR-Hips/Pelvis 3 or 4 Views Bilateral	FOGELMAN MD,DAVID	Modified
RA-17-0169348	9/20/2017 13:54 EDT	XR-Spine Entire 2 or 3 Views	FOGELMAN MD,DAVID	Modified

CDM code
2267000578
2267000588
F72082
F73522

Reason For Exam
(XR-Hips/Pelvis 3 or 4 Views Bilateral) Patient with CP for Hip Surveillance
(XR-Spine Entire 2 or 3 Views) Scoliosis

Report

.

SITTING AP AND LATERAL SPINE AND BILATERAL HIP SERIES: 9/20/2017

INDICATION: 3-year-old boy with history of cerebral palsy, spastic quadriplegia, global developmental delay, and intraventricular hemorrhage requiring a ventriculoperitoneal shunt.

COMPARISON STUDIES: Shunt series 9/8/2017. Supine AP spine and bilateral hip series 9/16/2016.

TECHNIQUE: Sitting AP and lateral spine. Supine AP pelvis and frog-leg lateral and von Rosen views of the hips.

FINDINGS: Slight dextroconvex midthoracic curvature and slight levoconvex upper lumbar curvature. Straightening of the lumbar spine. Modest exaggeration of thoracic kyphosis. Straightening of the cervical spine.

No vertebral segmentation anomalies nor fused ribs. The left iliac crest is slightly higher than the right in the seated position.

Left sided VP shunt catheter is intact where visualized. No discontinuity or kinking. The intra-abdominal tip has changed location, as expected. Moderate amount of stool throughout the colon.

Radiology

ACCESSION	EXAM DATE/TIME	PROCEDURE	ORDERING PROVIDER	STATUS
RA-17-0169348	9/20/2017 13:54 EDT	XR-Hips/Pelvis 3 or 4 Views Bilateral	FOGELMAN MD,DAVID	Modified
RA-17-0169348	9/20/2017 13:54 EDT	XR-Spine Entire 2 or 3 Views	FOGELMAN MD,DAVID	Modified

Report

Right cochlear implant. Remainder of the scoliosis examination is unremarkable.

Both acetabula are well formed with normal acetabular angles. Normal-appearing, symmetric femoral head ossification centers are well situated within the acetabula. Apparent bilateral coxa valga is at least in part related to external rotation of the legs. Normal mineralization. No fracture. No additional abnormality.

IMPRESSION:

1. Slight S-shaped scoliosis, as detailed above.

2. Modest exaggeration thoracic kyphosis and straightening of the lumbar and cervical spine.

3. No evidence for DDH.

4. Apparent bilateral coxa valga is at least in part related to external rotation of the legs.

I, the teaching physician, have reviewed the images with the trainee and agree with the findings

***** *Final Report*****

Dictated by: PAI MD, VINAY V 09/20/2017 14:30

Verified by: FAIR MD, RICK A 09/23/2017 10:43

Boston Children's Hospital
300 Longwood Avenue
Boston, MA 02115

BCH MRN: **500-20-94**
Patient Name: **ALDHAHERI, ABDULLA KHALIFA**
DOB/Age/Sex: 2/18/2014 3 years Male

Admit Date: 9/16/2016
Discharge Date: 9/16/2016

Patient Location: Cerebral Palsy
Patient Type: Outpatient
Financial #: 6119588895

Radiology

ACCESSION	EXAM DATE/TIME	PROCEDURE	ORDERING PROVIDER	STATUS
RA-16-0167565	9/16/2016 13:26 EDT	XR-Hips/Pelvis 3 or 4 Views Bilateral	FOGELMAN MD,DAVID	Modified
RA-16-0167565	9/16/2016 13:26 EDT	XR-Spine Entire 1 View	FOGELMAN MD,DAVID	Modified

CDM code
2267000577
2267000588
F72081
F73522

Reason For Exam
(XR-Hips/Pelvis 3 or 4 Views Bilateral) Patient with CP for Hip Surveillance
(XR-Spine Entire 1 View) Scoliosis

Report

.

SUPINE AP SPINE, HIPS AND PELVIS 3 VIEWS, SEPTEMBER 16, 2016

HISTORY: CEREBRAL PALSY

COMPARISON: NONE

There is no substantial spinal curvature.

Bone detail is limited but no vertebral anomalies are apparent.
Cervical spine is not well seen.

Femoral heads are well formed and symmetrical. Both are directed into normal appearing acetabula with slightly less coverage on the right than on the left in supine position and complete reduction with abduction.

The femurs are valgus and/ or excessively anteverted.

Portions of the VP shunt are visualized.

***** *Final Report*****

Dictated by: BUONOMO MD, CARLO 09/16/2016 13:34

Verified by: BUONOMO MD, CARLO 09/16/2016 13:36

Boston Children's Hospital

300 Longwood Avenue
Boston, MA 02115

BCH MRN: **500-20-94**
Patient Name: **ALDHAHERI, ABDULLA KHALIFA**
DOB/Age/Sex: 2/18/2014 3 years Male

Admit Date: 10/3/2016
Discharge Date: 10/3/2016

Patient Location: Otolaryngology Foundation
Patient Type: Outpatient
Financial #: 6119500686

Ambulatory Documentation

DOCUMENT NAME:	Otolaryngology Visit
SERVICE DATE/TIME:	10/3/2016 00:00 EDT
PERFORM INFORMATION:	KENNA MD,MARGARET A (10/8/2016 20:52 EDT)
SIGN INFORMATION:	KENNA MD,MARGARET A (11/8/2016 09:16 EST)
RESULT STATUS:	Auth (Verified)

DOB: 02/18/2014

CHIEF COMPLAINT: Hearing loss.

HISTORY OF PRESENT ILLNESS: Abdulla is a 2-1/2-year-old young boy seen in consultation at the request of the International Office for further evaluation of his hearing. He is here today with his mom and his uncle.

Abdulla was born in the UAE at 25 weeks 5 days and was one out of a set of triplet babies. He weighed about 800 grams. He spent approximately 4 months in the neonatal intensive care unit. He required mechanical ventilation for approximately 6 weeks and then was transitioned to CPAP and then off by the time he was discharged home from the hospital. His hospital course was complicated by intracranial hemorrhage resulting in hydrocephalus and VP shunt placement at 40 weeks. He also had retinopathy of prematurity that required laser treatment and second stage surgery. It appeared he also had treatment with Avastin.

Abdulla underwent ABR evaluation initially in the UAE and then in Thailand. Mom reports that in Thailand he had an ABR and ASSR both consistent with a significant degree of hearing loss. We do not have copies of the reports or the waveforms. Mom reports that Abdulla did seem to be responding well and then in December and January he had decreased hearing and was hospitalized with a very severe ear infection. Since that time his hearing appears to be decreased. He did receive intravenous antibiotic through 3 to 5 days for the ear infection. Apparently a CT scan was performed and an ear infection was documented. Mom reports that he did have symptoms of sleeplessness and vomiting but no fever. In general he has had a few episodes of acute otitis media. Mom does not report any difficulty with middle ear fluid.

Abdulla did have hearing aids that he has had for about the last year and a half. Mom reports he is not really using them and that they felt that he was really not making any progress with hearing aids. Mom reports that Abdulla had a booth test and was told to stop using the hearing aids because he was responding on his own without the hearing aids.

Review of systems is positive for history of retinopathy of prematurity. He was recently seen in Ophthalmology and found to be myopic with significant anisometropia. Eyeglasses have been recommended and follow up in 6 months' time to evaluate for amblyopia on the left was also recommended.

Abdulla has been seen in Neurology and has a diagnosis of cerebral palsy. It is unclear whether he has seizures but an EEG has been recommended. He did develop hydrocephalus secondary to intracranial bleed in the newborn period and does have a shunt and has had a shunt revision. He has also been seen in Orthopedics for spasticity motor delays and cerebral palsy. He has been given a prescription for physical therapy, occupational therapy and speech therapy. His physical therapy will focus on gait training as well as sitting and balance.

There is also concern about reactive airway disease and he has been referred to Pulmonary Medicine. Mom does not describe any cardiac, endocrine GU, dermatologic psychiatric or hematologic issues.

Ambulatory Documentation

Current medications include baclofen, and as-needed albuterol.

He has no known medication allergies and his immunizations are up-to-date.

Previous surgery includes a VP shunt in May 2014 a shunt revision in February 2016 and an inguinal hernia repair in May 2014 and February 2015. He also has had laser surgery for his ROP.

Socially Abdulla lives with his twin brother Mohammed as well as 4 older siblings and his parents in the United Arab Emirates. Sadly Abdulla and Mohammed's triplet brother passed away at about the age of 3 months post gestational age.

Abdulla has been receiving PT, OT and speech services three times a week for several hours in the UAE. Mom definitely feels these services have been of benefit. He also receives feeding therapy and aquatherapy. He is not receiving any sign language therapy.

As noted Abdulla has 4 older siblings 3 girls and a boy ages 15, 10, 8 and 6 years. All hear well and are developmentally normal.

Physical examination today shows a weight of 12.1 kg a height of 87 cm and a temperature of 37.4 degrees centigrade. Mom did report today some coughing which may be consistent with his reactive airway disease. He had widely patent ear canals. The eardrums were found to be intact and mildly retracted bilaterally. There are no preauricular pits or masses. Neck exam shows no lymphadenopathy or thyromegaly and trachea is midline. Oral cavity exam shows dentition in good repair. Soft palate is mobile with single midline uvula. Tonsils are 1+ in size without erythema or exudate. Voice is strong and clear without stridor. Cranial nerves II-XII are grossly intact except for the hearing loss. We also did not do any formal eye muscle motion assessment today. There are no obvious head or neck birthmarks, vitiligo, synophrys or skin rashes.

Audiometric assessment was obtained on 09/15/2016. No ear or frequency specific information could be obtained. Speech awareness threshold was obtained for bone conduction at 50 dB HL. DPOAEs were deferred due to patient activity level. Tympanograms showed negative pressure of -292 on the right and 332 on the left with a clear peak on the right and a rounded peak on the left.

IMPRESSION: Abdulla is a very pleasant little boy with a complex medical history. He has bilateral hearing loss. It is unclear the exact degree of his hearing loss and whether he may have some element of auditory dyssynchrony given his early gestation. We were unable to get a clear idea of his hearing today and attempted behavioral testing last week did not provide ear specific or frequency specific results. We are therefore recommending auditory brainstem response testing in the operating room to get a better idea what his hearing looks like so that we can make more concrete recommendations. Mom is very interested going forward with this and will get that organized in the near future here at Children's.

Mom has very good understanding and is in agreement with the plan. We spent approximately 80 minutes today in discussion of these issues with over 50% time spent in direct counseling and coordination of care.

Margaret A Kenna, MD, MPH
Department of Otolaryngology
Boston Children's Hospital

Ambulatory Documentation

DOCUMENT NAME:	Pulmonary Visit
SERVICE DATE/TIME:	5/11/2017 00:00 EDT
PERFORM INFORMATION:	MARTIN MD,THOMAS R II (5/11/2017 15:05 EDT)
SIGN INFORMATION:	MARTIN MD,THOMAS R II (5/15/2017 10:53 EDT)
RESULT STATUS:	Auth (Verified)

DATE OF BIRTH: 02/18/2014

Dear Colleagues:

I had the significant pleasure of seeing Abdulla in followup today in the Pulmonary Clinic. I met this 3-year-old boy in early November 2016 and had some concerns about possible aspiration and asthma that might have been responsible for the congestion, cough, and audible wheeze that we noted that day and of which he has had preceding history. We got him in for a modified barium swallow study which proved normal and started him on Flovent 110 2 puffs daily. I learned today that the family did not start the Flovent until December and at about that same time they moved from an apartment with carpeting that the mother thought might be contributing to an asthmatic chest congestion into a house in which there is no such carpeting. With the combination of the move and the Flovent his chest symptoms improved quite significantly not long after they moved. Mother reports today that he has done well since then. They kept him on the Flovent until about a month ago when the weather warmed and they thought a viral season was coming to an end when they stopped it. Thus far, he has not had return to any of the preceding chest findings or symptoms.

He is on an essentially normal diet and no longer has any particular tendency to cough or choke when he drinks.

He has been seen here by a number of specialists and is followed by Laurie Glader in the CCS clinic. He had his cochlear implants placed in February and his mother reports that he is already showing some speech development. He also is able to crawl now and has better tone and responsiveness and he is starting to say a few words such mama and dada.

The mother feels that he is currently in very good respiratory health with no chest congestion, coughing, wheezing, or labored breathing with exertion.

On his physical exam today, Abdulla has much better tone, he is much better grown, and generally appears much healthier than last November. He has a cochlear implant in place. His neck was supple with no adenopathy. Nares were clear. Chest was normal in shape and there are no retractions. Lungs

Ambulatory Documentation

were clear bilaterally with no crackles or wheezes. Heart sounds were normal with no murmur. His abdomen was soft and nontender with no mass or organomegaly. His extremities showed no clubbing. Skin was without rash. He is developmentally delayed, but quite responsive with nearly normal tone.

I am very pleased with how well Abdulla is doing. I am inclined to agree with his very intelligent mother that something in the carpeting made have been a trigger, perhaps, with the usual winter viruses, and I completely agree with her decision to take him off the Flovent. I think that he can probably safely stay off the Flovent through the summer and perhaps restart it in the fall. Apparently he currently is scheduled to continue having his cochlear implant adjusted until the end of summer and tentatively planning on returning the Middle East in mid-September.

I do not think I need to see him in follow-up unless he develops new respiratory symptoms or, if he stays beyond September, I should see him in the fall to address the question of whether he should start back on Flovent for the colder season.

I very much appreciate the chance to see Abdulla again today.

Sincerely,

Thomas R Martin, MD

CC:

International Office

300 Longwood Ave

Boston, MA 02115

Boston Children's Hospital

300 Longwood Avenue
Boston, MA 02115

BCH MRN: **500-20-94**
Patient Name: **ALDHAHERI, ABDULLA KHALIFA**
DOB/Age/Sex: 2/18/2014 3 years Male

Admit Date: 11/9/2016
Discharge Date: 11/9/2016

Patient Location: Pulmonary
Patient Type: Outpatient
Financial #: 6119824570

Ambulatory Documentation

DOCUMENT NAME: Pulmonary Visit
SERVICE DATE/TIME: 11/9/2016 00:00 EST
PERFORM INFORMATION: MARTIN MD,THOMAS R II (11/9/2016 16:43 EST)
SIGN INFORMATION: MARTIN MD,THOMAS R II (11/10/2016 17:11 EST)
RESULT STATUS: Auth (Verified)

DATE OF BIRTH: 2/18/2014

Dear Colleagues:

It was my pleasure to see Abdulla in the Pulmonary Clinic this afternoon here at Children's Hospital. He was referred here by Dr. Glader in the Complex Care Service Division because of a history of recurrent chest congestion and cough. He is here with his twin brother, both former 26-week premature babies, for comprehensive medical evaluation. In Dr. Glader's history she learned that they had fairly difficult premature courses. She did not detail in her letter that Abdulla and his twin were both on mechanical ventilation for about 6 weeks after birth, and Abdulla was weaned off of supplemental oxygen within about a week thereafter, and during that week his O2 requirement may have been partly related to the fact that he required a shunting procedure for hydrocephalus. Thereafter, in the UAE, Abdulla had recurrent congestion, cough, and wheeze, that typically occurred about every 6 weeks, usually leading to the administration of a nebulized steroid for about 4 to 5 days, generally successfully. He never developed significant evidence of labored breathing, and never required readmission to the hospital. Those episodes seem to develop even though he is seldom exposed to respiratory infections. He was not in day care in the UAE and he lives in an apartment in the Chestnut Hill area since coming to Boston 2 months ago. There, he is staying with his mother, her brother, his brother, and a nanny and the mother said to me that they never take the boys out from their apartment except to go to medical appointments. None of the adults is otherwise in contact with other adults and they do not get much in the way of exposure to crowds such as in the supermarket.

There is some concern about the possibility of aspiration because Abdulla has axial weakness /hypotonia, developmental delay, and may have a mild movement disorder. He has never had pneumonia, and does not generally choke when he drinks. As of about a month ago he stopped drinking milk and stopped drinking from a bottle with a nipple, and drinks some water from an open cup. When he drinks the water he does have some mild tendency to choke, but he never had that type of problem while drinking from the bottle. The water is the only thin liquid he is currently drinking. He is getting some liquid in his diet in the form of yogurt and pureed foods. The family is in the process of obtaining an appointment with our feeding team and the nutritionist.

The mother has noted that since moving into the carpeted apartment in Chestnut Hill area that both Abdulla and his brother have had much more frequent respiratory symptoms. She is using the nebulized albuterol. This was provided from the CCS clinic about twice a week, giving it only as needed and very much as seldom as possible. He is not currently on an inhaled steroid. It seems as though he has somewhat noisy breathing, but the mother does not give the nebulized medicine unless he has a fairly bad cough or the breathing is fairly pronounced. As noted he has not developed signs of labored breathing.

His review of systems is nicely outlined in Dr. Glader's note and I have nothing further to add to that. He will be undergoing surgery sometime in the next 3 months for cochlear implants bilaterally and the mother has been told that he will be required to stay in this area for 6 months following that procedure.

On his physical exam today, Abdulla is a well-nourished appearing boy who has some head enlargement, hypotonia, some

Ambulatory Documentation

movement incoordination, but he was in no distress. His nares were normal without mucosal thickening or secretions. His neck was supple with no adenopathy or thyroid abnormality. Chest was normal in shape. On auscultation he had soft mid expiratory wheeze that was very high-and pitched loudest at the lower posterior zones, but heard diffusely. There seemed to be symmetric aeration. His heart sounds were normal with no murmur. His abdomen was soft and nontender with no mass. His extremities showed no clubbing and skin was without rash.

My impression is that Abdulla has some mild asthma and it seems that it has worsened in these 2 months that they have been living in the Boston area, almost exclusively in their carpeted apartment. It is also conceivable that there is some aspiration that is contributing to this, but I think that has been less of a factor given that symptoms escalated so much after moving, and that they had been so infrequent and so transient and mild back in the UAE. Nevertheless, I think that we ought to obtain a modified barium swallow and the mother was readily agreeable to that. In addition, I think we ought to start him on Flovent 110 2 puffs once daily with AeroChamber and mask and I also will provide mother with a letter requesting that their apartment manager allow them to transfer into a different apartment where carpeting is not present.

I thank you for giving me the pleasure of meeting this very lovely family.

Sincerely,

Thomas R Martin, MD

CC:

CH International Health Services

300 Longwood Avenue

Pavilion One

Boston, MA 02115

Boston Children's Hospital
300 Longwood Avenue
Boston, MA 02115

BCH MRN: **500-20-94**
Patient Name: **ALDHAHERI, ABDULLA KHALIFA**
DOB/Age/Sex: 2/18/2014 3 years Male

Admit Date: 8/15/2017
Discharge Date: 9/11/2017

Patient Location: 09 NorthWest 9204 A
Patient Type: Inpatient
Financial #: 6121467356

Radiology

ACCESSION	EXAM DATE/TIME	PROCEDURE	ORDERING PROVIDER	STATUS
RA-17-0148572	8/19/2017 12:54 EDT	XR-Abdomen AP View	SHAPIRO ,DANIEL J	Modified

CDM code
2267000001
F74000

Reason For Exam
(XR-Abdomen AP View) s/p NJT placement, eval tube locaton

Report

.

STUDY: Single view of the abdomen.

HISTORY: 3-year-old status post VP shunt removal secondary to infection. A new feeding tube has been place.

IMPRESSION: The feeding tube tip is in the third portion of the duodenum. Bowel gas pattern is normal.

***** *Final Report*****

Dictated by: PEREZ-ROSSELLO MD, JEANNETT08/19/2017 13:13

Verified by: PEREZ-ROSSELLO MD, JEANNETT08/19/2017 13:15

Boston Children's Hospital
300 Longwood Avenue
Boston, MA 02115

BCH MRN: **500-20-94**
Patient Name: **ALDHAHERI, ABDULLA KHALIFA**
DOB/Age/Sex: 2/18/2014 3 years Male

Admit Date: 8/15/2017
Discharge Date: 9/11/2017

Patient Location: 09 NorthWest 9204 A
Patient Type: Inpatient
Financial #: 6121467356

Radiology

ACCESSION	EXAM DATE/TIME	PROCEDURE	ORDERING PROVIDER	STATUS
RA-17-0148417	8/18/2017 21:14 EDT	XR-Chest 1 View	LEVY MD,EMILY R	Modified

CDM code
2267000043
F71010

Reason For Exam
(XR-Chest 1 View) Post extubation

Report

Portable chest, 8/18/2017 at 9:10 PM

INDICATION: 3-year-old status post extubation. History of prematurity , intracranial hemorrhage, seizures, and recent intubation. The patient is now postop day 1 from infected VP shunt removal, and has been extubated.

COMPARISON: 8/18/2017 at 5:32 AM

FINDINGS: Portable semiupright AP chest was obtained. Endotracheal tube and NG tube have been removed. Right arm PICC line terminates in the right atrium, stable.
Lung volumes are extremely low. Bibasilar opacities, left greater than right, are in keeping with atelectasis. Otherwise the lungs are grossly clear, allowing for the low lung volumes.

The cardiac silhouette appears mildly enlarged, accentuated by the low lung volumes.

Moderate diffuse gaseous distention of the bowel is present, with a nonobstructive distribution of bowel gas.

No other changes.

IMPRESSION:
1. Extremely low lung volumes following extubation. Bibasilar opacities are likely related to atelectasis but should be followed on subsequent examinations.
2. Right arm PICC line is in stable position, reaching the right atrium.

Radiology

ACCESSION	EXAM DATE/TIME	PROCEDURE	ORDERING PROVIDER	STATUS
RA-17-0148417	8/18/2017 21:14 EDT	XR-Chest 1 View	LEVY MD,EMILY R	Modified

Report
***** *Final Report*****

Dictated by: VOSS MD, PhD, STEPHAN D 08/18/2017 21:28

Verified by: VOSS MD, PhD, STEPHAN D 08/18/2017 21:34

Boston Children's Hospital

300 Longwood Avenue
Boston, MA 02115

BCH MRN: **500-20-94**
Patient Name: **ALDHAHERI, ABDULLA KHALIFA**
DOB/Age/Sex: 2/18/2014 3 years Male

Admit Date: 9/30/2016
Discharge Date: 9/30/2016

Patient Location: Ophthalmology Waltham
Patient Type: Outpatient
Financial #: 6119462561

Ambulatory Documentation

DOCUMENT NAME:	Ophthalmology Visit
SERVICE DATE/TIME:	9/30/2016 00:00 EDT
PERFORM INFORMATION:	ALKHARASHI MD,MAAN S (10/3/2016 08:05 EDT); ALKHARASHI MD,MAAN S (9/30/2016 17:06 EDT)
SIGN INFORMATION:	ALKHARASHI MD,MAAN S (10/3/2016 08:05 EDT); ALKHARASHI MD,MAAN S (10/3/2016 08:01 EDT)
RESULT STATUS:	Modified

Addendum by ALKHARASHI MD, MAAN S on October 03, 2016 08:05 EDT
The 6 months follow up visit can be arranged here or with his local ophthalmologist in Cleveland Clinic Abu Dhabi.

DATE OF BIRTH: 02/18/2014

HISTORY OF PRESENT ILLNESS: Today I had the pleasure of seeing Abdulla with his mother and uncle in the eye clinic. This is the initial visit for a history of retinopathy of prematurity. Abdulla has a history of prematurity. He was born at 25 weeks of gestation. He has a history of retinopathy of prematurity that required laser treatment and Avastin eye injection. He has cerebral palsy and hydrocephalus with a history of intracranial hemorrhage. He takes no medications and has no allergies.

EXAMINATION: On examination, the patient was alert but uncooperative. He was fixating and following with each eye. With both eyes he was seeing 20/270 using PLT. Cycloplegic refraction was -0.50 +1.00 X090 in the right eye and -4.50 +1.50 X090 in the left eye. On sensorimotor evaluation, he had no nystagmus with full extraocular muscle movements. He was mostly orthotropic. We attempted but were unable to evaluate his stereopsis. Pupils were equal and reactive. Slit lamp examination of the anterior segment showed a limbal dermoid in the inferior part of the right cornea. Otherwise, normal anterior segment. Intraocular pressure was normal using tactile method. On visual field testing, he was able to look at targets in all four quadrants with both eyes. Dilated fundus examination was very difficult to obtain due to poor cooperation. I was not able to look at the peripheral retina. The optic nerve was healthy in both eyes and grossly there was no retinal detachment.

ASSESSMENT AND PLAN: In summary, Abdulla has a history of retinopathy of prematurity. He is myopic with significant anisometropia. I dispensed glasses for full time wear. At his next visit if we are able to demonstrate any amblyopia in the left eye, we may consider patching the right eye. I would like to see him again in 6 months for reevaluation.

Maan Alkharashi, MD

Boston Children's Hospital
300 Longwood Avenue
Boston, MA 02115

BCH MRN: **500-20-94**
Patient Name: **ALDHAHERI, ABDULLA KHALIFA**
DOB/Age/Sex: 2/18/2014 3 years Male

Admit Date: 8/3/2017
Discharge Date: 8/3/2017

Patient Location: Otolaryngology Waltham
Patient Type: Outpatient
Financial #: 6121426575

Ambulatory Documentation

DOCUMENT NAME:	Otolaryngology Visit
SERVICE DATE/TIME:	8/3/2017 15:00 EDT
PERFORM INFORMATION:	BRODSKY MD,JACOB R (8/8/2017 12:25 EDT)
SIGN INFORMATION:	BRODSKY MD,JACOB R (8/8/2017 12:25 EDT)
RESULT STATUS:	Auth (Verified)

VESTIBULAR & BALANCE TEST REPORT

DATE OF EVALUATION: 08/03/2017
NAME, DOB & MRN: Abdula Khalifa Aldhaheri, 02/18/2014, #500-20-94
REFERRED BY: Dr. Licameli/Dr. Brodsky
REASON FOR TEST: Bilateral hearing loss, s/p right CI

Videonystagmography (VNG) under observational camera:

Spontaneous nystagmus: none
Saccades: able to track targets
Pursuit: not smooth
Optokinetic nystagmus: age appropriate

Rotational testing: under observational camera (0.04, 0.08 and 0.16 Hz)

VOR responses: present with both CW and CCW rotations, stronger with CW rotations
Fixation-suppression of the VOR: abnormal

Vestibular Evoked Myogenic Potential (VEMP)

Stimuli: 500 Hz tone-bursts via insert phones
Cervical VEMP responses: present on both sides @ 90 dB nHL

Impression: Compared to pre-CI evaluation in January 2017, no significant change noted.

Boston Children's Hospital
300 Longwood Avenue
Boston, MA 02115

BCH MRN: **500-20-94**
Patient Name: **ALDHAHERI, ABDULLA KHALIFA**
DOB/Age/Sex: 2/18/2014 3 years Male

Admit Date: 2/15/2017
Discharge Date: 2/15/2017

Patient Location: Otolaryngology Waltham
Patient Type: Outpatient
Financial #: 6120390616

Ambulatory Documentation

DOCUMENT NAME:	Otolaryngology Visit
SERVICE DATE/TIME:	2/15/2017 00:00 EST
PERFORM INFORMATION:	LICAMELI MD,GREG R (2/15/2017 13:47 EST)
SIGN INFORMATION:	LICAMELI MD,GREG R (2/23/2017 16:17 EST)
RESULT STATUS:	Auth (Verified)

DATE OF BIRTH: 02/18/2014.

Abdulla is status post recent right cochlear implant on February 2nd due to his diagnosis of bilateral sensorineural hearing loss. His surgery was uneventful. He was monitored overnight and discharged to home the following day in stable condition. The parents state that he and his brother both recovered quite well from the surgery. They had minimal incisional discomfort, managed with Tylenol. They have otherwise returned back to their normal diets and activity.

Home Medication List (Medication Name Only)
- aerochamber with medium mask
- albuterol (albuterol 1.25 mg/3 mL (0.042%) inhalation solution)
- cholecalciferol (Vitamin D3 400 intl units/mL oral liquid)
- fluticasone (Flovent HFA 110 mcg/inh inhalation aerosol)
- Nebulizer machine

Allergies: No known allergies

The review of systems form, as filled in by the parent, was reviewed and is positive for those symptoms detailed above. It is otherwise negative for cardiac, pulmonary, endocrine, GI, GU, neurologic, dermatologic, hematologic, musculoskeletal, or psychiatric symptoms.

Temperature: 36.7; Patient In Pain Now: No; Weight: 13.9 kg (41%ile)*; Length: 90.5 cm (13%ile)*; Stature Type: Standing; Body Mass Index: 17 kg/m2 (78%ile)*

Physical exam today shows a well-healed postauricular incision line. The postauricular flap on the right is flat and nontender. The tympanic membranes are healthy. Middle ear spaces are well aerated bilaterally. Cranial nerve VII is intact and bilaterally symmetric. Skin is warm, and well perfused for the upper extremities. The patient was cooperative and appropriate during the examination.

Overall, I think that Abdulla has done quite well. We will see both children back for their first mapping session in one weeks' time.

Ambulatory Documentation

Sincerely,

Greg R. Licameli MD, FACS

Attending Physician

Otolaryngology and Communication Enhancement

Boston Children's Hospital

Boston Children's Hospital
300 Longwood Avenue
Boston, MA 02115

BCH MRN: **500-20-94**
Patient Name: **ALDHAHERI, ABDULLA KHALIFA**
DOB/Age/Sex: 2/18/2014 3 years Male

Admit Date: 1/31/2017
Discharge Date: 1/31/2017

Patient Location: Otolaryngology Waltham
Patient Type: Outpatient
Financial #: 6120224047

Ambulatory Documentation

DOCUMENT NAME:	Otolaryngology Visit
SERVICE DATE/TIME:	1/31/2017 00:00 EST
PERFORM INFORMATION:	LICAMELI MD,GREG R (1/31/2017 13:20 EST)
SIGN INFORMATION:	LICAMELI MD,GREG R (2/2/2017 18:53 EST)
RESULT STATUS:	Auth (Verified)

DATE OF BIRTH: 02/18/2014

Abdulla is here today with his twin brother to discuss his candidacy for a right cochlear implant. This almost 3 -year-old is an ex-25-week preemie. He is one of triplets and he does have a surviving twin, who as mentioned, is here today with him. He also has a history of spastic quadriplegia, cerebral palsy with right hemiplegia, global developmental delay and a history of intracranial hemorrhage, as well as auditory neuropathy for his diagnosis of hearing loss.

The mother states that early on, he was aided in their home country, and occasionally would respond to sounds. He has no language production to date. Communication primarily is with facial expressions. They do not have any Sign Language.

Abdulla had a history of a few ear infections when younger, but he has had none this winter season. He is up-to-date on his vaccinations.

He has been given the diagnosis of bilateral auditory neuropathy on recent ABR performed at Children's. Surgical interventions include hernia repair in the neonatal period, shunt with revision in 2014 in Abu Dhabi, Botox injections in November 2016 with an EUA of the ears by Otolaryngology, ABR on 10/31/2016, and laser surgery for retinopathy of prematurity in Abu Dhabi.

Home Medication List (Medication Name Only)
- aerochamber with medium mask (Misc Prescription)
- albuterol (albuterol 1.25 mg/3 mL (0.042%) inhalation solution)
- cholecalciferol (Vitamin D3 400 intl units/mL oral liquid)
- fluticasone (Flovent HFA 110 mcg/inh inhalation aerosol)
- Nebulizer machine (Misc Prescription)

Allergies: No known allergies

Ambulatory Documentation

The review of systems form, as filled in by the parent, was reviewed and is positive for those symptoms detailed above. It is otherwise negative for cardiac, pulmonary, endocrine, GI, GU, neurologic, dermatologic, hematologic, musculoskeletal, or psychiatric symptoms.

Temperature: 37.1; Heart Rate: 71; Oxygen Saturation (SPO2): 99; Patient In Pain Now: No

Physical exam today demonstrates clear external canals bilaterally. The tympanic membranes are healthy. Middle ear spaces are well aerated. The nose is patent anteriorly. The oral cavity and oropharynx are clear. The tongue and palate are normal in size and appearance. The tonsils are 1+ in size and symmetric. There is no evidence of posterior exudates or lesions. The neck was supple without adenopathy or masses. Trachea is midline. Breathing is quiet at rest without stridor or wheeze. Cranial nerve VII is intact and bilaterally symmetric. Skin is warm, and well perfused for the upper extremities.

Both Abdulla and his brother have been involved in the Cochlear Implant Program for the last several weeks and the family has met several members of our team. We have discussed them on multiple occasions in regards to their candidacy with Dr. Kenna and others. Today Dr. Brodsky and I had a very long discussion with the parents in regards to their candidacy and our expectations for their performance, given their prematurity and somewhat advanced age at the time of implantation. The risk and benefits of surgery were reviewed in detail.

The parents had several questions all answered to their satisfaction. They acknowledge that may only obtain sound awareness and this will perhaps aid them their ability for communication going forward in intensive rehabilitative therapy. It will be critical to their successful use of the implant, and to this end, the mother has indicated that she will be able to stay at least six months in the US so that this can be ensured.

We tentatively have a surgical date later this week for both boys. The parents have indicated they are in agreement with this plan. Abdulla and his brother will be discussed at length at our next cochlear implantation team meeting as well. The parents have indicated they want the Nucleus device.

Sincerely,

Greg R. Licameli MD, FACS

Attending Physician

Otolaryngology and Communication Enhancement

Boston Children's Hospital

Boston Children's Hospital
300 Longwood Avenue
Boston, MA 02115

BCH MRN: **500-20-94**
Patient Name: **ALDHAHERI, ABDULLA KHALIFA**
DOB/Age/Sex: 2/18/2014 3 years Male

Admit Date: 1/26/2017
Discharge Date: 1/26/2017

Patient Location: Otolaryngology Waltham
Patient Type: Outpatient
Financial #: 6120357372

Ambulatory Documentation

DOCUMENT NAME:	Otolaryngology Visit
SERVICE DATE/TIME:	1/26/2017 15:00 EST
PERFORM INFORMATION:	BRODSKY MD,JACOB R (2/2/2017 16:28 EST)
SIGN INFORMATION:	BRODSKY MD,JACOB R (2/2/2017 16:28 EST)
RESULT STATUS:	Auth (Verified)

VESTIBULAR & BALANCE TEST REPORT

DATE OF EVALUATION: 01/26/2017
NAME, DOB & MRN: Abdula Khalifa AlDhaheri, 02/18/2014, #500-20-94
REASON FOR TEST: Bilateral hearing loss. h/o hydropcephalus and CP, Pre-CI, Labyrinthine dysfunction

Videonystagmography (VNG) under observational camera:

Spontaneous nystagmus: none
Pursuit: not smooth
Optokinetic nystagmus: age appropriate

Rotational testing: under observational camera (0.04, and 0.16 Hz)

VOR responses: present with both CW and CCW rotations
Fixation-suppression of the VOR: abnormal

Tympanometry:

Left ear: normal pressure and mobility
Right ear: negative pressure (-170daPa) but normal mobility

Vestibular Evoked Myogenic Potential (VEMP)

Stimuli: 500 Hz tone-bursts via insert phones
Cervical VEMP responses: present on both sides
Cervical VEMP thresholds: left = 75 dB nHL; right = 80 dB nHL

Impression: No indication of peripheral vestibular loss on either side but central loss can’t be ruled out.

Boston Children's Hospital
300 Longwood Avenue
Boston, MA 02115

BCH MRN: **500-20-94**
Patient Name: **ALDHAHERI, ABDULLA KHALIFA**
DOB/Age/Sex: 2/18/2014 3 years Male

Admit Date: 11/7/2016
Discharge Date: 11/7/2016

Patient Location: Otolaryngology Foundation
Patient Type: Outpatient
Financial #: 6119891772

Ambulatory Documentation

DOCUMENT NAME:	Otolaryngology Visit
SERVICE DATE/TIME:	11/7/2016 00:00 EST
PERFORM INFORMATION:	ALBANO CPN,VICTORIA C (11/15/2016 15:09 EST)
SIGN INFORMATION:	KENNA MD,MARGARET A (12/8/2016 12:45 EST); ALBANO CPN,VICTORIA C (11/16/2016 13:12 EST)
RESULT STATUS:	Auth (Verified)

DATE OF BIRTH: 2/18/2014

Dr. Kenna and I had the pleasure of seeing Abdulla and his brother Mohammed in follow-up. They are here today with their mother.

HISTORY OF PRESENT ILLNESS: Abdulla and Mohammed are 2-year-old twins who were born at 25 weeks and five days in the UAE. Abdulla has a history of spastic quadriplegia, cerebral palsy with superimposition of right hemiplegia, global developmental delay, history of intracranial hemorrhage resulting in hydrocephalus requiring shunt placement, hearing loss, and vision impairment.

We first met Abdulla and Mohammed on 10/3/2016. We recommended that they undergo OR ABR as well as MRI of the temporal bones. ABR was performed on 10/31/2016 and revealed bilateral cochlear microphonic consistent with the diagnosis of auditory neuropathy spectrum disorder. MRI of the temporal bones was performed on 10/28 and revealed normal inner ears. Brain MRI showed prior grade IV germinal matrix hemorrhage on the left. Small right cerebellar hemisphere may reflect cross-cerebellar diaschisis vs posterior fossa germinal matrix hemorrhage. There is related volume loss within the corpus callosum. This is unchanged in comparison to previous scans. These results were shared with Abdulla's mother today during clinic. Abdulla and his brother are followed in Neurology Clinic by Dr. Coulter.

Abdulla's mother is very interested in pursuing possible cochlear implant for her children.

Abdulla has been healthy since we last saw him in clinic. He has not had any trouble with otitis media, otorrhea or otalgia. He is scheduled to receive Botox injections on 11/17/2016. She reports he has developed good head control and is Army crawling. He also rolls. He is starting to say mama.

PAST MEDICAL HISTORY: Abdulla was born at 25 weeks, 5 days. He weighed about 800 grams. He was one out of a set of triplets. Unfortunately, one triplet did not survive. He spent approximately four months in the Neonatal Intensive Care Unit. He required mechanical ventilation for approximately six weeks and then was transitioned to CPAP. His hospital course was complicated by intracranial

Ambulatory Documentation

hemorrhage resulting in hydrocephalus and a VP shunt was placed at 40 weeks. He has a history of ROP that required laser treatments.

Abdulla's hearing was initially evaluated in the UAE and then in Thailand. We do not have a copy of these reports. He did initially have hearing aids. However, his parents stopped using them because they did not notice an improvement in responses when their children were wearing hearing aids.

UPDATED SOCIAL HISTORY: Abdulla is receiving occupational therapy here at Boston Children's Hospital. He will be starting physical therapy soon. He does wear bilateral AFOs.

Tobacco exposure: None.

MEDICATIONS: Albuterol as needed.

ALLERGIES: No known medication allergies.

PHYSICAL EXAMINATION: Vitals: Weight 12.75 kg, temperature 36.9 degrees Celsius. General: he is well-appearing and in no acute distress. He is seated in his mother's lap. Ear canals were widely patent. Bilateral tympanic membranes intact, translucent and mobile. There are no preauricular pits or masses. Nose: anterior nares are patent bilaterally, without rhinorrhea. Oropharynx: mucous membranes are moist and pink. Soft palate is mobile with a single midline uvula. Posterior oropharynx is clear. Tonsils are 1+ without exudate or erythema. Oral dentition is in decent repair. Neck: no lymphadenopathy, no thyromegaly. Trachea is midline.

ASSESSMENT: 1. Premature at 25 weeks.
2. Bilateral ANSD.
3. Hydrocephalus, status post shunt.
4. Spastic quadriplegia

PLAN: Our impression is that Abdulla is an approximately 2-1/2-year-old with bilateral auditory neuropathy spectrum disorder in the context of extreme prematurity, hydrocephalus, status post shunt, and a four month course in the NICU. Hearing aids have been attempted in the past without benefit. Abdulla did have an MRI which showed present vestibular cochlear nerves. Abdulla's mother is very interested in moving forward with the cochlear implant process. We had a long discussion of the variability and success with cochlear implants, especially in children with extreme prematurity. We discussed further evaluation by our cochlear implant team which would include an evaluation by a speech and language pathologist and by a psychologist. Abdulla's mother was very interested in moving forward with this process. We have been in touch with the rest of the CI team who will reach out to Abdulla's mother to set those appointments up in the near future.

Ambulatory Documentation

Today's findings and treatment options were discussed with Abdulla and Mohammed's mother who had a chance to ask questions and has an excellent understanding of the plan. We spent approximately 30 minutes in discussion of all these issues with over 50% of the time spent in direct patient counseling. Thank you for allowing us to participate in his care.

Sincerely,

Victoria Albano, MSN, CPNP
Nurse Practitioner in Otolaryngology

I have participated fully in the clinical evaluation, physical examination, diagnostic assessment and management plan for this patient.

Margaret Kenna, MD, MPH
Otolaryngology Attending

Procedure Notes

DOCUMENT NAME:	Operative Note
SERVICE DATE/TIME:	7/21/2017 08:30 EDT
PERFORM INFORMATION:	FOGELMAN MD,DAVID (7/21/2017 08:30 EDT)
SIGN INFORMATION:	FOGELMAN MD,DAVID (7/21/2017 08:30 EDT)
RESULT STATUS:	Auth (Verified)

DATE OF SURGERY: July 21, 2017

PREOPERATIVE DIAGNOSIS: spastic quadriplegia

POSTOPERATIVE DIAGNOSIS: spastic quadriplegia

PROCEDURE:
1. Phenol motor branch blocks to the bilateral lower limbs.
2. Botulinum toxin injections to the bilateral lower limbs and upper limbs.

INDICATIONS: spastic quadriplegia

ANESTHESIA: General.

PHYSICIAN: David Fogelman, MD

ASSISTANT: none

DETAILS OF PROCEDURE AND FINDINGS:

Pre-procedure Exam:

Vitals:

Temperature: 36 L; Heart Rate: 109; Systolic Blood Pressure: 100; Diastolic Blood Pressure: 74; Respiratory Rate: 24; Oxygen Saturation (SPO2): 99

Lower Limbs:

Procedure Notes

Galeazzi: Negative.

Hip Abduction Range: Symmetrical in terms of range without catch

Hips/Knees Flexed R: 70 degrees on both sides

Hips/Knees Extended R: 50 degrees on both sides

Popliteal Angle: 40 degrees on both sides

Ankle Dorsiflexion

Knees Flexed possible to neutral on both sides

Knees Extended possible to neutral on both sides

Hip Rotation:

Internal 45 degrees

External 50 degrees

The consent was signed and placed in the chart. When instructed to do so by Anesthesia the procedure was initiated. All areas to be injected were cleaned with alcohol that was allowed to dry.

First, the phenol motor branch blocks were done using 5% phenol in normal saline. The following nerves were identified using electrical stimulator guidance, with injection of 5% phenol in NS as follows:
Total dose of 5% phenol: 1.4 ml.

R anterior obturator nerve: 0.4 ml.
L anterior obturator nerve: 0.4 ml.
Nerve to R medial hamstrings: 0.3 ml.
Nerve to L medial hamstrings: 0.3 ml.

All aspirations were negative.

Next the botulinum toxin injections were done. Toxin was reconstituted in normal saline, using 2ml saline for each 100 unit vial of toxin.

Using neurostimulator guidance, the following muscles were identified and received the following doses of Botox. All aspirations were negative.

A total of 150 units of Botox was utilized. The following muscles received the following doses of Botox:
BILATERAL UPPER LIMBS:
Finger flexors : 10 units per side

Procedure Notes

BILATERAL LOWER LIMBS:
Gracilis: 30 units per side
Hamstrings: 25 units per side
peroneus brevis: 10 units per side

Abdulla tolerated the procedure well. There were no complications.

Specific orders for post-operative physical therapy were placed in the computer and provided to parents upon discharge.

Follow up in clinic with me within 3-4 months

I attest that I was present for this entire procedure, including consent process and all injections.

David J. Fogelman, MD
Staff Physician, Pediatric Rehabilitation Medicine
Department of Orthopedic Surgery
Boston Children's Hospital

Boston Children's Hospital
300 Longwood Avenue
Boston, MA 02115

BCH MRN: **500-20-94**
Patient Name: **ALDHAHERI, ABDULLA KHALIFA**
DOB/Age/Sex: 2/18/2014 3 years Male

Admit Date: 2/2/2017
Discharge Date: 2/3/2017

Patient Location: 10 NorthWest 1001 A
Patient Type: Observation
Financial #: 6120300773

Procedure Notes

DOCUMENT NAME:	Operative Note
SERVICE DATE/TIME:	2/2/2017 15:13 EST
PERFORM INFORMATION:	ROSENBLATT MD,STEVEN D (2/2/2017 15:29 EST)
SIGN INFORMATION:	LICAMELI MD,GREG R (2/23/2017 12:57 EST); ROSENBLATT MD,STEVEN D (2/3/2017 13:58 EST)
RESULT STATUS:	Auth (Verified)

PRE-OPERATIVE DIAGNOSIS: Bilateral sensorineural hearing loss.

POST-OPERATIVE DIAGNOSIS: Bilateral sensorineural hearing loss.

PROCEDURES PERFORMED: Right Cochlear implantation with mastoidectomy. Facial nerve monitoring x4hrs.

SURGEON: Greg Licameli, MD

ASSISTANTS: Steven Rosenblatt, MD

ANESTHESIA: General.

BRIEF INDICATIONS FOR PROCEDURE: Abdulla is a 2 year old boy ex-25 week preemie with significant developmental delays and bilateral sensorineural hearing loss along with auditory neuropathy. His parents wanted to pursue cochlear implantation. After long discusions regarding expected outcomes, risks, benefits, and alternatives, we decided to proceed and signed consent was obtained.

DESCRIPTION OF PROCEDURE: The patient was identified in the preanesthesia holding area by two identifiers and brought back to the operating room. He was placed on the operating table in the supine position. After the smooth induction of general endotracheal anesthesia a surgical time out was performed and all were in agreement. The right ear was examined under the microscope and the drum was intact and normal without evidence of infection or effusion. The CT scans were available and on the screen in the operating room. The facial nerve monitor was placed in the right orbicularis oris and and orbicularis occuli, along with ground and stimulating leads in the left shoulder. The postauricular incision was marked, and the hair was shaved for elevation of the postauricular incision. Approximately 10cc of 0.5% lidocaine with epinephrine 1:100,000 was infiltrated into the proposed incision site. He was then prepped and draped in a sterile fashion.

The skin was incised with a #15 blade, and the subcutaneous tissue was divided with both sharp and cautery dissection. A Palva flap was elevated anteriorly and a skin flap posteriorly. This was held in place with Weitlaner retractors. Temporalis fascia was harvested for later use around the cochleostomy.

Using a combination of cutting and diamond burrs, a mastoidectomy was performed, with identification of the lateral canal and incus. The facial recess was opened with a combination of 3 and 2 mm diamond burrs. It should be noted that the facial nerve was very anterior making for a challenging facial recess. The facial nerve was partially exposed for 2 mm, though it was not violated. It stimulated with the nerve stimulator appropriately. The stapes was identified, as was the round window niche. Again it was challenging exposure as there was a soft tissue curtain over the round window niche, and the niche was angled in an acute superior/inferior direction. Ultimately after drilling off the round window overhand we were able to appropriately visualize the round window membrane.

Procedure Notes

A well was made approximately 50 degrees off midline 2.5 centimeters from the face of the posterior bony canal with a combination of diamond and cutting burrs. We used a slightly more superior location as he is wheelchair bound and uses lateral headrests. Stay sutures were also secured into the bone around the well using a 2mm burr to make small troughs on either side. While drilling the well there was an approximately 1mm violation of the dura. This was closed with a single interrupted 6-0 nylon suture and sealed with tisseal. A trough was made using a 4mm diamond burr into the mastoid cavidty. The wound was irrigated copiously, and gloves were changed. New sterile towels were placed around the ear.

An extended round window cochleostomy was made with a 1mm burr. Healon was placed over the cochleostomy. The implant was then brought into the field and was secured in the well with 4-0 Vicryl. The ground electrode was placed under the temporalis muscle. The electrode was easily placed without resistance into the cochlea using the angled forceps and claw with full insertion. The cochleostomy was packed with fascia. The exposed facial nerve was covered with previously harvested fascia. The remainder of the facial recess was packed with gel foam. The extra electrode was coiled into the mastoid and covered with a piece of Gelfoam and the periosteum was closed with 3-0 Vicryl.

The subcutaneous tissues were reapproximated with 4-0 Vicryl in a buried interrupted fashion and the skin was closed with a 5-0 Monocryl in running subcuticular fashion. Audiology tested the integrity of the device prior to emergence from anesthesia with NRT's demonstrating full insertion. An x-ray was obtained and it confirmed the position. Bacitracin was applied and a mastoid dressing was placed. The patient tolerated the procedure well, without complication. At this point, the case was concluded. All surgical counts were correct and Dr. Licameli was present and active throughout the entire procedure.

Steven Rosenblatt, MD

Boston Children's Hospital
300 Longwood Avenue
Boston, MA 02115

BCH MRN: **500-20-94**
Patient Name: **ALDHAHERI, ABDULLA KHALIFA**
DOB/Age/Sex: 2/18/2014 3 years Male

Admit Date: 11/17/2016
Discharge Date: 11/17/2016

Patient Location: DSU DSPP NC
Patient Type: Day Surgery
Financial #: 6119830214

Procedure Notes

DOCUMENT NAME:	Operative Note
SERVICE DATE/TIME:	11/17/2016 07:53 EST
PERFORM INFORMATION:	FOGELMAN MD,DAVID (11/17/2016 07:56 EST)
SIGN INFORMATION:	FOGELMAN MD,DAVID (11/17/2016 07:56 EST)
RESULT STATUS:	Auth (Verified)

DATE OF SURGERY: 11/17/2016

PREOPERATIVE DIAGNOSIS: spastic quadriplegia

POSTOPERATIVE DIAGNOSIS: spastic quadriplegia

PROCEDURE:
1. Phenol motor branch blocks to the lower limbs bilaterally.
2. Botulinum toxin injections to the bilateral upper limbs, bilateral lower limbs.

INDICATIONS: spastic quadriplegia

ANESTHESIA: General.

PHYSICIAN: David Fogelman, MD

ASSISTANT: none

DETAILS OF PROCEDURE AND FINDINGS:

Pre-procedure Exam:

Vitals: Weight: 12.28 kg (13%ile)*
*CDC chart used to calculate percentile value.

Temperature: 36.2 L; Heart Rate: 94; Systolic Blood Pressure: 94; Diastolic Blood Pressure: 66; Respiratory Rate: 24; Oxygen Saturation (SPO2): 100; Patient In Pain Now: No

Procedure Notes

Examination of the lower limbs reveals negative Galeazzi bilaterally. Passive hip abduction with the hips flexed is 60 degrees bilaterally. There is no evidence of hip flexion contracture and Thomas test was 0 degrees bilaterally. He has a minimal knee flexion contracture of 5 degrees on the right. Popliteal angle is 70 degrees on the right and 30 degrees on the left. Passive ankle dorsiflexion with the knee flexed has an initial catch at -10 and ranges to -5. On the left, he has an initial catch at -5 and ranges to neutral.

The consent was signed and placed in the chart. When instructed to do so by Anesthesia the procedure was initiated. All areas to be injected were cleaned with alcohol that was allowed to dry.

First, the phenol motor branch blocks were done using 5% phenol in normal saline. The following nerves were identified using electrical stimulator guidance, with injection of 5% phenol in NS as follows:
Total dose of 5% phenol: 1 ml.

R anterior obturator nerve: 0.3 ml.
L anterior obturator nerve: 0.3 ml.
Nerve to R medial hamstrings: 0.2 ml.
Nerve to L medial hamstrings: 0.2 ml.

All aspirations were negative.

Next the botulinum toxin injections were done. Toxin was reconstituted in normal saline, using 2ml saline for each 100 unit vial of toxin.

Using neurostimulator guidance, the following muscles were identified and received the following doses of Botox. All aspirations were negative.

A total of 130 units of Botox was utilized, 200 reconstituted, 70 discarded. The following muscles received the following doses of Botox:
UPPER LIMBS:
finger flexors: 10 units each side

LOWER LIMBS:
gracilis: 25 units each side
hamstrings: 20 units each side
peroneals: 10 units each side

Abdulla tolerated the procedure well. There were no complications.

Procedure Notes

Specific orders for post-operative physical therapy were placed in the computer and provided to parents upon discharge.

Follow up in clinic with me within 12 weeks

I attest that I was present for this entire procedure, including consent process and all injections.

David J. Fogelman, MD
Staff Physician, Pediatric Rehabilitation Medicine
Department of Orthopedic Surgery
Boston Children's Hospital

Boston Children's Hospital
300 Longwood Avenue
Boston, MA 02115

BCH MRN: **500-20-94**
Patient Name: **ALDHAHERI, ABDULLA KHALIFA**
DOB/Age/Sex: 2/18/2014 3 years Male

Admit Date: 10/31/2016
Discharge Date: 10/31/2016

Patient Location: DSU DSPP NC
Patient Type: Day Surgery
Financial #: 6119767494

Procedure Notes

DOCUMENT NAME:	Operative Note
SERVICE DATE/TIME:	10/31/2016 14:21 EDT
PERFORM INFORMATION:	WOLTER MD,NIKOLAUS (10/31/2016 14:30 EDT)
SIGN INFORMATION:	VOLK MD,DMD,MARK S (11/1/2016 08:30 EDT); WOLTER MD,NIKOLAUS (10/31/2016 14:35 EDT)
RESULT STATUS:	Auth (Verified)

Date: October 31, 2016

Procedure: Examination of the ears under anesthetic

SURGEON: Mark Volk, MD

ASSISTANTS: Nikolaus Wolter, MD

ANESTHESIA: General anesthesia

ESTIMATED BLOOD LOSS: nil

COMPLICATIONS: nil

FINDINGS AND DETAILS OF PROCEDURE:

Normal tympanic membranes and external ear canals bilaterally.

INDICATIONS: The patient is a 2-1/2-year-old boy ex-25 weeks old. He was admitted to the NICU after birth on mechanical ventilation and suffered from an intracranial hemorrhage. He also has a history of severe bilateral hearing loss. He is hear today for an ABR.

PROCEDURE: After verifying the history and given consent, the patient was brought to the operating room and placed supine on the operating room table. Anesthesia was induced via mask. A time out performed and all were in agreement.

The otomicroscope was brought in and used throughout the case. Cerumen was removed bilaterally using the wax curette. There was no retraction or evidence of cholesteatoma. The tympanic membrane appeared normal with no signs of middle ear effusion

Procedure Notes

This concluded the procedure. We turned the patient back to anesthesia to undergo the ABR. The patient was awoken without difficulty after the ABR. There were no complications during the case. Dr.Volk was present and scrubbed for the entirety of the case.

Nikolaus E. Wolter MD, MSc, FRCSC
Clinical Fellow, Department of Otolaryngology

Boston Children's Hospital

300 Longwood Avenue
Boston, MA 02115

BCH MRN: **500-20-94**
Patient Name: **ALDHAHERI, ABDULLA KHALIFA**
DOB/Age/Sex: 2/18/2014 3 years Male

Admit Date: 3/1/2017
Discharge Date: 3/1/2017

Patient Location: Ophthalmology Waltham
Patient Type: Outpatient
Financial #: 6119694996

Ambulatory Documentation

DOCUMENT NAME:	Ophthalmology Visit
SERVICE DATE/TIME:	3/1/2017 15:12 EST
PERFORM INFORMATION:	ALKHARASHI MD,MAAN S (3/1/2017 15:17 EST)
SIGN INFORMATION:	ALKHARASHI MD,MAAN S (3/1/2017 15:17 EST)
RESULT STATUS:	Auth (Verified)

DATE OF BIRTH: 02/18/2014

HISTORY OF PRESENT ILLNESS: Today I had the pleasure of seeing Abdulla with his mother in the eye clinic. He follows with us for a history of retinopathy of prematurity. Abdulla has a history of prematurity. He was born at 25 weeks of gestation. He has a history of retinopathy of prematurity that required laser treatment and Avastin eye injection.
Since his last visit, his mom reports that he is not wearing glasses and refuse to keep them on.

He has cerebral palsy and hydrocephalus with a history of intracranial hemorrhage. He takes no medications and has no allergies.

EXAMINATION: On examination, visual acuity was 20/270 with each eye and 20/180 with both eyes using PLT.
On sensorimotor evaluation, he had no nystagmus with full extraocular muscle movements. He had a small intermittent exotropia of 10-16 PD. We attempted but were unable to evaluate his stereopsis. Pupils were equal and reactive. Slit lamp examination of the anterior segment showed a limbal dermoid in the inferior part of the right cornea. Otherwise, normal anterior segment. Intraocular pressure was normal using tactile method. On visual field testing, he was able to look at targets in all four quadrants with both eyes.

ASSESSMENT AND PLAN: In summary, Abdulla has a history of retinopathy of prematurity. He is myopic with significant anisometropia which puts him at risk of amblyopia. He also has a well controlled intermittent exotropia that requires no intervention. He should wear his glasses full time. I would like to see him again in 6 months for reevaluation.

Maan Alkharashi, MD

Boston Children's Hospital
300 Longwood Avenue
Boston, MA 02115

BCH MRN: **500-20-94**
Patient Name: **ALDHAHERI, ABDULLA KHALIFA**
DOB/Age/Sex: 2/18/2014 3 years Male

Admit Date: 5/4/2017
Discharge Date: 5/4/2017

Patient Location: Clinical Nutr
Patient Type: Outpatient
Financial #: 6120751433

Ambulatory Documentation

DOCUMENT NAME:	Nutrition Visit
SERVICE DATE/TIME:	5/4/2017 15:12 EDT
PERFORM INFORMATION:	GRUNKO RD,AMINA (5/4/2017 15:20 EDT)
SIGN INFORMATION:	GRUNKO RD,AMINA (5/4/2017 15:20 EDT)
RESULT STATUS:	Auth (Verified)

DATE OF BIRTH: 02/18/2014
NUTRITION ASSESSMENT

CLIENT HISTORY: Abdulla is a 3 year and 2 month old who presents with his mother, and Mohamed's sibling Abdullah, for a nutrition visit. As you know, Mohamed is one of triplets who was born at 25 weeks and 5. Mohamed has a history of spastic quadriplegia with CP, IVH with a VP shunt and ROP. He was initially seen by me back on 12/6/16. He had an MBS on 4/4/17 which showed no aspirationi with fluids. For additional information please refer to the SLP report of 4/4/17.

A typical day is as follows:
Breakfast: 2c baby oatmeal cereal made with water and sips of thickened water
Lunch: One cup of a combination of rice, some type of meat such as chicken or lamb, tomato sauce, and some soft bread; 1 c yogurt is mixed into this.
Dinner: Very similar to lunch, rice or potatoes with meat and tomato sauce and more yogurt.

Abdulla typically eats better than Mohamed. He usually finishes most meals.

Abdulla is reported to have no vomiting or reflux. He has really good bowel movements daily. His current medications include Baclofen and a few inhalers such as Flovent and Albuterol.

Mom's is mostly concerned about his drinking ability and the lack of his intake. He is not on any additional herbs or vitamins.

ANTHROPOMETRIC MEASUREMENTS:
Weight 13.1 kg, 14 percentile, Z-score -1.06
Length 94.5 cm, 18 percentile, Z-score -0.53
Weight for Length 17 percentile, Z-score -1.00
BMI 14.7 kg/M2, 12 th percentile, Z-score -1.18

Abdulla has gained 640 grams since I saw him in December. He is presenting without wasting or stunting. He has continued to make good progress on the growth curve. His intake seems to provide him an average of 900-1300 cal/day, per rerport.

Comparative Standards:
Schofield x 1.4-1.8: 926-1186 cal/day
1.2 g/kg/day protein
1100-1200 mls/day

NUTRITION DIAGNOSIS: Feeding difficulties related to complicated medical history or prematurity of birth and IVH as evidenced by reports from mother of lack of adequate drinking and chewing skills. (resolving).

Ambulatory Documentation

NUTRITION INTERVENTION:
PRESCRIPTION: May Duocal powder to all his meals as sibling will start

1. Nutrition counseling and education on ways to increase caloric density of meals. Reviewed with mom use of whole milk, butter, oils, cream cheese, hummus, avocado etc. to increase caloric density of meals.
- Discussed trial of Duocal powder added to his meals, 1 tablespoon (42 cal), three x day for an additional 142 cal/day. Given that Abdulla is gaining nicely but his brother need more catch up, I suggested that family continue presenting the same meals with the same additives as Abdulla will benefit from it as well.

2. Collaboration with other providers: Continue to followup with CCS and Nutrition.

NUTRITION MONITORING AND EVALUATION:

1. Weight/BMI
2. Types of foods and meals.

Thank you for allowing me to participate in Abdulla's care. I met with the family for 45 minutes, followup as needed in three months.
Amina Grunko, MS, RD, LDN
Clinical Nutrition Specialist II

Boston Children's Hospital
300 Longwood Avenue
Boston, MA 02115

BCH MRN: **500-20-94**
Patient Name: **ALDHAHERI, ABDULLA KHALIFA**
DOB/Age/Sex: 2/18/2014 3 years Male

Admit Date: 12/1/2016
Discharge Date: 12/1/2016

Patient Location: Clinical Nutr
Patient Type: Outpatient
Financial #: 6119789147

Ambulatory Documentation

DOCUMENT NAME:	Nutrition Visit
SERVICE DATE/TIME:	12/1/2016 00:00 EST
PERFORM INFORMATION:	GRUNKO RD,AMINA (12/6/2016 09:53 EST)
SIGN INFORMATION:	GRUNKO RD,AMINA (12/8/2016 10:47 EST)
RESULT STATUS:	Auth (Verified)

DATE OF BIRTH: 02/18/2014
NUTRITION ASSESSMENT

CLIENT HISTORY: Abdulla is a 33-month-old, or 2-year 9-month-old, (corrected gestational age of 31 months) toddler who is presenting with his mother and brother for a nutrition visit. Interpreter is not needed given the mom can speak English.

As you know, Abdulla is the product of a triplet birth born at 25 weeks' gestation. Unfortunately, one of the triplets died at 40 weeks' gestation due to severe IVH. Abdulla does have a diagnosis of spastic quadriplegia with CP and superimposed right hemiplegia and IVH with VP shunt. He was initially seen by Dr. Laurie Glader from CCS. In regards to his nutrition, mom reports that Abdulla is the better eater of the two siblings. He does get feeding therapy back home and is recently showing good chewing skills when eating.

In the past, Abdulla was able to take Similac formula through a bottle; however, stopped drinking it in the last 2 months. He does not drink any milk or milk substitute. He drinks water. His typical day includes the following:
Breakfast: Baby cereal made with water and some mashed-up bananas.
Lunch: Some type of chicken or meat with rice and a tomato sauce with yogurt and some soft bread.
Dinner: Either similar to lunch or some macaroni or other types of pasta which is all cut up into very small bites.

Abdulla is able to crawl army style. He is able to have regular bowel movements about 2 times per day without difficulty. He is currently not on any medications but uses an inhaler when having an upper respiratory infection.

NUTRITION-FOCUSED PHYSICAL FINDINGS: Alert and happy boy.

Anthropometric Measurements:
Weight: 12.46 kg, 14th percentile, Z-score -1.07.
Length: 86.5 cm, 3rd percentile, Z-score -1.88.
Weight for length: 59th percentile, Z-score 0.23.
BMI: 16.7 kg/m2, 68th percentile, Z-score 0.47.

Abdulla is presenting without wasting or malnutrition, with no stunting. It appears that he has progressed very well despite his prematurity and has shown excellent weight gain and growth.

In regards to his detailed intake, I worry that there is not a calcium-rich beverage and Abdulla is no longer drinking Similac formula, either. I discussed the importance of a calcium and vitamin D rich beverage such as cow's milk as it is important to have an intake of at least 8-12 oz per day. Abdulla does take yogurt with his meals; however, it does not appear that this is a consistent amount.

Ambulatory Documentation

Comparative Standards:
Schofield x 1.4-1.8: 976-1255 cal/day
1.2 g/kg/day protein
~1100 mls/day

NUTRITION DIAGNOSIS: Food and nutrition knowledge deficit related to calcium intake as evidenced by lack of calcium-rich beverage.
NUTRITION INTERVENTION:

Nutrition Prescription: Initiate cow's milk or alternative.
1. Nutrition counseling and education on the importance of calcium-rich beverage such as cow's milk or goat's milk if this is what they have back home. Alternatively, if mom reports Abdulla refuses cow's milk, it will be okay to restart Similac formula. We discussed other devices besides the bottle for Abdulla to drink from including a Rubbermaid litterless juice cup with a straw spout. We also discussed the importance of well-balanced meals including more vegetables and fruits into his daily intake to assure adequate vitamin and mineral intake. If Abdulla continues to show good progress with chewing skills, he will progress nicely without need of further feeding therapy intervention; however, while they are here, I suggested a feeding evaluation to better assess what his abilities are for feeding.
2. Collaboration with other providers: Continue to follow up with CCS, Nutrition, and obtain a feeding evaluation.

NUTRITION MONITORING/EVALUATION:
1. Weight/BMI.
2. Types of foods and meals.
3. Calcium-rich beverage.

Thank you for allowing me to participate in Abdulla's care. I met with the family for 45 minutes. Follow up as needed in 3 months or sooner.
Amina Grunko, MS, RD, LDN

Boston Children's Hospital
300 Longwood Avenue
Boston, MA 02115

BCH MRN: **500-20-94**
Patient Name: **ALDHAHERI, ABDULLA KHALIFA**
DOB/Age/Sex: 2/18/2014 3 years Male

Admit Date: 8/15/2017
Discharge Date: 9/11/2017

Patient Location: 09 NorthWest 9204 A
Patient Type: Inpatient
Financial #: 6121467356

Procedure Notes

DOCUMENT NAME:	Operative Note
SERVICE DATE/TIME:	9/7/2017 00:00 EDT
PERFORM INFORMATION:	FEHNEL MD,KATIE P (9/7/2017 23:51 EDT)
SIGN INFORMATION:	FEHNEL MD,KATIE P (9/8/2017 22:30 EDT)
RESULT STATUS:	Auth (Verified)

DATE OF PROCEDURE: 9/7/2017

PRE-OPERATIVE DIAGNOSIS: Post hemorrhagic hydrocephalus and failure of endoscopic third ventriculostomy.

POST-OPERATIVE DIAGNOSIS: Same as preoperative diagnosis.

PROCEDURES PERFORMED: Left burr hole for ventriculoperitoneal shunt placement, use of stereotactic computer-assisted image guidance navigation.

SURGEON: Katie Fehnel, M.D.

ASSISTANTS: Georgios Alexopoulos, M.D.

INDICATIONS: The patient is a 3-year-old male ex-25 weeker with a history of grade IV IVH of prematurity who subsequently was shunted for hydrocephalus at three months of age and has had multiple prior shunt malfunctions and revisions. He presented this admission with new onset seizure and was ultimately found to have a shunt infection. External ventricular drain was placed by my colleague, Dr. Madsen, and the shunt was externalized by Dr. Madsen as well and he then had an attempted endoscopic third ventriculostomy in an effort to make him shunt independent by my colleague, Dr. Ben Warf. Since his ETV, he failed numerous clamp trials with elevated ICPs and was planned to have a ventriculoperitoneal shunt replacement tomorrow now having completed the appropriate course of antibiotics per our infectious disease colleagues.
Though he was scheduled for shunt placement tomorrow, his shunt placement was expedited in light of the patient having accidentally pulled out his external ventricular drain. Given concern for worsening hydrocephalus with heart rate into the 80s, he was taken urgently to the operating room for placement of a new left ventriculoperitoneal shunt. The procedure was discussed with my colleague, Dr. Ben Warf, and given that I am on call I was available to assist with shunt placement. I discussed the procedure with mom, risks and benefits were discussed. The mother was very familiar with shunting and wished to proceed.

Procedure Notes

DETAILS OF PROCEDURE AND FINDINGS: After satisfactory induction of general endotracheal anesthesia, the patient was positioned supine, head turned to the right. He was registered using our Stealth neuronavigation. Hair was then clipped in a standard fashion. Previous burr hole site for his ETV and prior external ventricular drain was noted and a site anterior to this was selected that would allow for good access to the ventricles. Of note, the patient has an extremely dysmorphic cranial vault with rather atypical landmarks, which is why we ultimately used neuronavigation and therefore the selected burr hole site was more posterior than would be typical of a frontal burr hole. He was then prepped and draped in a standard sterile fashion inclusive of his cranial space down to his abdomen. A JCAHO mandated time out was performed.

Abdominal incision was made two fingerbreadths below the costal margin. This was opened using bipolar cautery and Metzenbaum scissors. The pre-rectus fascia was identified and incised. The rectus abdominis was spread atraumatically and the posterior rectus sheath was opened sharply. The peritoneum was identified and gently teased apart using two snaps. The intraperitoneal fat was apparent and we were able to pass a Penfield 4 very easily into the peritoneal space. This was then removed and the peritoneum was then snapped and set aside.

We then turned our attention to the cranial incision. A U-shaped incision was created and again opened using bipolar cautery and Metzenbaum scissors. A new burr hole was made using an acorn drill bit. We then tunneled quite easily using one pass with the shunt passer down to the peritoneal opening. We then turned our attention to the back table and primed our shunt tubing and our medium pressure valve and checked distal runoff and the valve appropriately ran down to 12. The tubing was then passed cranial to caudal through our shunt passer and this was set aside. We then used our neuronavigation stylet and ventricular catheter and selected a trajectory. We passed this to a depth of 7 cm of the outer table and this was then cut and a Rickham reservoir was attached. This was secured in place using a silk tie. We then secured our shunt to our Rickham reservoir, then again with a 2-0 silk tie also secured our valve to our distal tubing. We then identified good distal flow out the distal catheter tip. We dunked this into the peritoneum without difficulty under direct visualization using hand over hand technique. A 3-0 Vicryl stitch was placed reapproximating the peritoneum.

We then irrigated this out using Bacitracin irrigation and closed our abdominal wound using 3-0 Vicryls and a running Monocryl in the skin with Steri-Strips over the abdominal incision as well. The cranial incision was similarly closed. Bacitracin irrigation irrigated out. We closed the galea using 3-0 Vicryls and given numerous recent externalizations and EVD placement and recent ETV, we excised some of the macerated skin edges and closed using 3-0 nylon vertical mattress for half the incision and a running nylon in the remainder with a good cosmetic result.

Intraoperative CT confirmed our catheter to be in good position. He tolerated the procedure and was extubated uneventfully. As the attending neurosurgeon, I was present for the entire procedure and performed every portion myself.

Procedure Notes

DOCUMENT NAME:	Operative Note
SERVICE DATE/TIME:	8/24/2017 00:00 EDT
PERFORM INFORMATION:	WARF MD,BENJAMIN C (8/25/2017 14:58 EDT)
SIGN INFORMATION:	WARF MD,BENJAMIN C (8/28/2017 16:23 EDT)
RESULT STATUS:	Auth (Verified)

DATE OF SURGERY: 08/24/2017.

PREOPERATIVE DIAGNOSIS: Posthemorrhagic hydrocephalus with shunt infection and external drain.

POSTOPERATIVE DIAGNOSIS: Same.

PROCEDURES: BUR hole for endoscopic third ventriculostomy, placement of external ventricular drain, use of the stereotactic computer-assisted image guidance navigation.

SURGEON: Benjamin Warf, MD

ASSISTANTS: Katie Fehnel, MD, Ph.D.

ANESTHESIA: General endotracheal.

ESTIMATED BLOOD LOSS: Negligible.

SPECIMEN: CSF for routine studies.

INDICATIONS: This youngster had had multiple shunt complications and procedures and had presented here with a shunt malfunction and infection. He had undergone placement of external ventricular drain by my colleague, Dr. Madsen, who also removed the shunt system. The child has been on antibiotic therapy to cover the appropriate organism. The child had very small ventricles initially but with external drainage the ventricles were able to be gradually increased in size with gradual raising of the drainage system such that it became possible to attempt an endoscopic third ventriculostomy. Prior MRI scans had demonstrated that the child had an obstructed aqueduct and also appeared to have an open prepontine cistern. The mother had been hoping to have the shunt removed and an ETV done for a long time but there had not been a reasonable opportunity to do this until now. She wished to proceed with this option understanding that it might fail and also understanding the risks of surgery.

DETAILS OF PROCEDURE AND FINDINGS: The patient was taken to the operating theater and placed under general endotracheal anesthesia. He was positioned supine with head turned to the left. The left pericoronal area was clipped free of hair which allowed for a region of entry. The Stealth image guidance navigation system was registered and the probe was used to select the ideal entry point into his extremely dysmorphic left lateral ventricle which was the larger ventricle. Having selected the point which was well off midline and slightly posterior to a line even with the tragus in this child with a very abnormally shaped head, the scalp was prepped and draped in the usual way. After appropriate operative time-out and local infiltration with 0.25% Marcaine and 1:200,000 epinephrine a small linear incision was made in the scalp. A bur hole was made and the dura was opened. The underlying cortical surface was cauterized with bipolar electrocautery. The child has

Procedure Notes

cochlear implants and monopolar electrocautery was not used at any point during the case.

Next using the Stealth ventricular catheter stylet a Bactiseal external ventricular drain was passed through the bur hole using image guidance to direct it into the left lateral ventricle. There was nice spontaneous flow of clear CSF. The stylet was withdrawn. The catheter was then removed and immediately the 3.7 mm flexible steerable ventriculoscope was guided under direct vision along the resulting tract directly into the ventricular system.

The anatomy was quite dysmorphic but guided by choroid plexus we found the left foramen of Monro and entered the third ventricle. Third ventricular landmarks were able to be identified. The lamina terminalis, optic chiasm, infundibular recess, floor of the third ventricle, and a completely closed aqueduct were identified.

Next, using the Bugbee wire but without the use of any electrocautery the floor was penetrated and then a 3-French Fogarty balloon catheter was used to progressively dilate the ETV. The endoscope was passed easily through the ETV into the prepontine cistern where a naked basilar artery was observed. The Liliequist membrane had been fenestrated and there was no significant arachnoid scar within the cistern.

The endoscope was withdrawn back into the third ventricle and there were nice pulsations across the ETV.

The endoscope was gradually withdrawn and the Bactiseal external ventricular drain was again replaced by soft passing it along the endoscope tract and into the ventricle with good flow. This was tunneled out to a separate stab incision and the catheter was secured to the scalp with stitches and connected to a sterile closed drainage system.

Next the existing external ventricular drain was removed and the exit site closed with a stitch. The scalp over the bur hole was closed in layers with 3-0 Vicryl and 4-0 Monocryl and a Dermabond dressing.

The operation went very and as the attending neurosurgeon I was present for the entire operation.

Boston Children's Hospital
300 Longwood Avenue
Boston, MA 02115

BCH MRN: **500-20-94**
Patient Name: **ALDHAHERI, ABDULLA KHALIFA**
DOB/Age/Sex: 2/18/2014 3 years Male

Admit Date: 8/15/2017
Discharge Date: 9/11/2017

Patient Location: 09 NorthWest 9204 A
Patient Type: Inpatient
Financial #: 6121467356

Procedure Notes

DOCUMENT NAME:	Operative Note
SERVICE DATE/TIME:	8/17/2017 00:00 EDT
PERFORM INFORMATION:	MADSEN MD,JOSEPH R (8/17/2017 18:29 EDT)
SIGN INFORMATION:	MADSEN MD,JOSEPH R (8/18/2017 17:05 EDT)
RESULT STATUS:	Auth (Verified)

DATE OF PROCEDURE: 08/17/2017.

PRE-OPERATIVE DIAGNOSIS: Ventriculoperitoneal shunt infection.

POST-OPERATIVE DIAGNOSIS: Ventriculoperitoneal shunt infection.

PROCEDURES PERFORMED: Removal of entire ventriculoperitoneal shunt.

SURGEON: Madsen, Joseph R, MD.

ASSISTANTS: Moses, Ziev, MD.
Alexopoulos, Georgios, MD.

ANESTHESIA: General endotracheal.

COMPLICATIONS: None noted intraoperatively.

ESTIMATED BLOOD LOSS: 5 milliliters.

INDICATIONS: The patient had placement of a new external ventricular drain after failed ability to get fluid from a shunt tap and a confusing clinical situation that included new onset of seizures after a background history of shunted hydrocephalus from a 25-week pregnancy in United Arab Emirates. Today the fluid from the operating room grew gram-positive rods, which provided at least a tentative explanation for why with relatively low pressures and no change in ventricular size we could be having possible shunt-related symptoms and would also be consistent with occlusion of the shunt, which we had observed in the tap. Because of this finding and the fact that we now had a good working external ventricular drain (EVD), we elected to remove the old infected shunt today.

DETAILS OF PROCEDURE AND FINDINGS: After induction of satisfactory general endotracheal anesthesia through the existing endotracheal tube, the entire course of the shunt was clipped, prepped, and draped, and a surgical pause occurred.

We infiltrated the incision over the burr hole with local anesthetic and cut down on it with a knife, avoiding the use of monopolar electrocautery. This made the procedure more difficult, but it was still doable to retract around the burr hole and eventually to work down to the Codman valve, which could be grasped with a Kelly and pulled up after dissecting more of the tissue around it to free it up. The entire shunt came out from the abdomen, and after disconnecting it proximally and manipulating the catheter a bit, we were able to get a small amount of fluid to come out, but we could not advance it as a soft pass. The fluid was somewhat cloudy and was sent for Gram stain and culture. We then closed the galea with interrupted 3-0 Vicryl sutures and the skin with running 4-0 Monocryl.

Procedure Notes

As attending neurosurgeon, I was present for this entire procedure.

Cc: Madsen, Joseph R, MD.
Moses, Ziev, MD.
Alexopoulos, Georgios, MD.

Boston Children's Hospital
300 Longwood Avenue
Boston, MA 02115

BCH MRN: **500-20-94**
Patient Name: **ALDHAHERI, ABDULLA KHALIFA**
DOB/Age/Sex: 2/18/2014 3 years Male

Admit Date: 8/15/2017
Discharge Date: 9/11/2017

Patient Location: 09 NorthWest 9204 A
Patient Type: Inpatient
Financial #: 6121467356

Procedure Notes

DOCUMENT NAME:	Operative Note
SERVICE DATE/TIME:	8/15/2017 00:00 EDT
PERFORM INFORMATION:	MADSEN MD,JOSEPH R (8/15/2017 19:09 EDT)
SIGN INFORMATION:	MADSEN MD,JOSEPH R (8/16/2017 17:40 EDT)
RESULT STATUS:	Auth (Verified)

DATE OF PROCEDURE: 08/15/2017

PRE-OPERATIVE DIAGNOSIS: Suspected shunt malfunction.

POST-OPERATIVE DIAGNOSIS: Possible shunt malfunction with intracranial pressure issues.

PROCEDURES PERFORMED:
1. Shunt tap in Emergency Department.
2. Left frontal external ventricular drain placement with stereotactic guidance in the operating room.

SURGEONS:
Procedure #1. Joseph R. Madsen, MD and Georgios Alexopoulos, MD
Procedure #2. Joseph R. Madsen, MD and Ziev Moses, MD

INDICATIONS FOR PROCEDURE: We were called urgently to the Emergency Department for a patient who is now 3 years old and came from the United Arab Emirates without any prior surgery here. He was a 25-week premature infant and had a shunt with very small ventricles. He had presented with vomiting followed by seizures with tachycardia and then bradycardia with hypertension so there was significant concern about the possibility of intracranial hypertension.

PROCEDURE #1: I elected to do a shunt tap. The area over the reservoir which was attached directly to the ventricular catheter was prepped and draped and a 23-gauge butterfly needle was securely placed into the reservoir. No spontaneous flow came out and I could by aspiration, get only a few drops. The fluid was clear. Despite the fact that the ventricles which were very dysmorphic, did not seem to be enlarged in size, we were still concerned given the clinical history and vital sign changes that this may be an acute shunt malfunction precipitating seizures. So we made preparations to take him to the operating room which was done forthwith.

A second procedure was then in the operating room.

DETAILS OF PROCEDURE #2 AND FINDINGS: Under general anesthesia he was first registered to the AxiEM stereotactic guidance system. We projected some possible trajectories coming from close to midline and aiming for the left frontal horn of the ventricle which is the largest part. Because the patient had a cochlear implant we did not use Bovie but opened the skin with a knife after local anesthetic and used extensive bipolar electrocautery and then used the MA drill to drill a bur hole. Using the trajectory guidance system we aimed for what we thought would be the ventricle and passed it in to a depth of about 5 cm and at this depth and even with a little bit more of a soft pass, we had at first bloody and then clear fluid that continued to drip quite continuously while we were there but never had a pressure higher than about 10-12 cmH20. We sent some fluid specimens and then tunneled the catheter out posteriorly. Because of the extremely bizarre configuration of the ventricles , we decided to perform an intraoperative CT scan. Provided this scan is reasonably satisfactory, the patient will go to the ICU for recovery.

Procedure Notes

ATTESTATION: As attending neurosurgeon, I was present for both of these procedures.

Boston Children's Hospital

300 Longwood Avenue
Boston, MA 02115

BCH MRN: **500-20-94**
Patient Name: **ALDHAHERI, ABDULLA KHALIFA**
DOB/Age/Sex: 2/18/2014 3 years Male

Admit Date: 9/22/2016
Discharge Date: 9/22/2016

Patient Location: Neurology Foundation
Patient Type: Outpatient
Financial #: 6119488538

Ambulatory Documentation

DOCUMENT NAME:	Neurology Visit
SERVICE DATE/TIME:	9/22/2016 00:00 EDT
PERFORM INFORMATION:	COULTER MD,DAVID L (9/22/2016 17:08 EDT)
SIGN INFORMATION:	COULTER MD,DAVID L (9/26/2016 12:52 EDT)
RESULT STATUS:	Auth (Verified)

DATE OF BIRTH: 02/18/2014

Dear Sir:

I saw Abdulla Aldhaheri in the Neurology Clinic on 09/22/2016. He is a 2-year and 7-month-old boy who was referred because of cerebral palsy. Although I did have the assistance of the Arabic interpreter, his parents actually speak very good English, and we really never had to ask the interpreter for help.

Starting at the beginning, Abdulla was born at 25 weeks gestation as 1 of triplets. He weighed about 800 grams at birth. His brother Mohamed weighed about the same. There was a third brother who died at about 3 months of age of complications from prematurity. In the Neonatal Intensive Care Unit, he experienced an intracranial hemorrhage that eventually caused hydrocephalus and required a shunt. There was an event earlier this year that they thought might have been due to a shunt malfunction. I think he was vomiting and lethargic. They also did an EEG at that time, and his parents provided me with a copy of the EEG report. His parents said that the patient was sedated or under anesthesia for the EEG, although that is not mentioned in the report. They said that he slept pretty much throughout the test. However, the report says "this is a 30-minute video EEG recording during wakefulness and natural sleep." According to the report, his background activity consisted of high amplitude beta which was reactive to eye opening and closing. During sleep there were vertex waves but no sleep spindles, which is a little bit unusual. The report suggests that the EEG was read as being completely normal however.

Because of the question of a shunt malfunction, and an MRI showed that the shunt had moved and was no longer in the right position, the shunt was replaced and moved over to the left side of his head, and he has been fine ever since.

I should note that he also had a pretty severe ear infection at the time.

His mother indicated that Abdulla initiated fairly pretty intensive therapy almost as soon as he came home from the hospital. He has made progress. He does get a lot of therapy. He is able to stand and take steps with assistance. He is beginning to produce some sounds or vocalizations, and is learning to be able to communicate his wants and needs. He seems to be pretty social and enjoys interacting with people.

Past medical history is pretty much as above. I think he did have some retinopathy of prematurity and required therapy for that but I think he has responded pretty well. Mother indicated that there has been some concern about his hearing however, and I note that a hearing test was attempted last week. There was concern about eustachian tube dysfunction and I think the hearing test itself was not considered valid, so that an auditory brainstem response test was recommended. He will be seeing Dr. Kenna in a couple of weeks.

Family history is significant only because of his brother who also has CP.

Ambulatory Documentation

I should note that Abdulla saw Dr. Fogelman last week who prescribed a number of therapies and braces.

On examination, I note that his weight was 12.3 kg last week. His head circumference today was 48 cm which is at about the 20th percentile. He does have the narrow head of prematurity. He really was pretty social and interactive and I heard a fair amount of vocalization, indicating that he probably does really have an intent to communicate.

He had a somewhat obligate tonic neck reflex with his head turned to the right, not so much to the left, and I suspect it probably was not as obligate as his brothers.

General physical examination was otherwise unremarkable and there was no hepatosplenomegaly.

Neurologically, cranial nerve examination showed full ocular movements and normal pupillary reactions. Facial movement was symmetric. I did not see much drooling.

He had good head control on pulling to sit, but was loose under the shoulders in vertical suspension. He was able to stand with support and bear weight pretty well, and I also observed him taking steps again with support, so I think the prospect for him eventually walking with assistance is pretty fair. He had increased tone in the right arm in particular and tended to use the left arm more than the right. I watched him reach for objects with the left which he really did quite well. He was able to reach and grab and hold onto things with the left hand. With the right hand, he clearly made an effort to reach for things, but he was not able to open the fingers as well to be able to grab and hold on.

The tone was certainly increased in both legs on passive range potion and his ankles were really pretty tight. I was not able to get any clonus because he was so tight. Reflexes were brisk all over.

Thus, he is a 31-month-old boy, born very prematurely, who has developed cerebral palsy as described above. It is not clear whether he also has had seizures, and I do question the EEG report that was done earlier this year. I suggested to his parents that we repeat the EEG here, without using any sedation, to see whether he does in fact have a seizure tendency.

His parents have brought the disk with the prior images, which we should be able to load into his chart here. I would like to repeat the MRI scan to evaluate his hydrocephalus and to assess the nature and extent of any associated brain injury. Given his preference for using the left hand, I might wonder whether he would have more significant injury to the left hemisphere.

I told his parents that I think there is a reasonable prospect that Abdulla will eventually be able to walk with assistance. It will take some time and effort in therapy to get to that point. Whether he will ever be able to walk independently is less likely. With regard to his cognition, it is certainly hard to say, but he is showing some encouraging signs as noted above. I pointed out that children with cerebral palsy are often underestimated with regard to their cognitive abilities, so working on communication is really quite important.

I will plan to see him back after the EEG and MRI scan has been accomplished. I appreciate very much the opportunity to see him today.

Sincerely,

David L Coulter, MD
Department of Neurology

CC:

International Office

Ambulatory Documentation

300 Longwood Ave

Boston, MA 02115

Boston Children's Hospital
300 Longwood Avenue
Boston, MA 02115

BCH MRN: **500-20-94**
Patient Name: **ALDHAHERI, ABDULLA KHALIFA**
DOB/Age/Sex: 2/18/2014 3 years Male

Admit Date: 9/26/2017
Discharge Date: 9/26/2017

Patient Location: Neurosurgery Foundation
Patient Type: Outpatient
Financial #: 6121595509

Ambulatory Documentation

DOCUMENT NAME: Neurosurgery Visit
SERVICE DATE/TIME: 9/26/2017 17:34 EDT
PERFORM INFORMATION: BIRCH ,ASHLEY K (10/2/2017 17:40 EDT)
SIGN INFORMATION: BIRCH ,ASHLEY K (10/12/2017 19:24 EDT)
RESULT STATUS: Auth (Verified)

Chief Complaint
Postoperative follow-up and suture removal

History of Present Illness
Dear Doctor,
It was my pleasure to see Abdulla in the clinic today for neurosurgical follow-up. He is accompanied to this appointment today by his mother. As you know Abdullah is a 3-year-old male ex-25 weeker with a history of grade 4 IVH of prematurity subsequently shunted for hydrocephalus at 3 months of age who has had multiple prior shunt malfunctions and revisions. He presented recently with new onset seizure was ultimately found to have a shunt infection. An EVD was placed and the shunt was externalized and an ETV was attempted. After the ETV Abdulla failed numerous clamp trials with elevated ICPs and ultimately required VP shunt placement. He was taken to the operating room urgently for this procedure as he accidentally pulled out his EVD.
His mother tells me that since leaving the hospital he has not had irritability, lethargy, vomiting, and seems back to his baseline. His incision site has been free from signs of infection and he has been free from fever.

Scales and Assessments
Patient In Pain Now: No

Review of Systems
A Complete review of systems was performed with positive systems listed in the history of presenting illness and past medical history with all others negative

Physical Exam

Vitals & Measurements
HR: 124 (Monitored) **RR:** 28
Weight: 14.100 kg (20%ile)*
*CDC chart used to calculate percentile value.

PHYSICAL EXAMINATION: Constitutional: Alert, no distress, cooperative and pleasant. Eyes: Pupils equal and reactive to light bilaterally. HENT: Dolichocephalic, healing scalp incision with sutures in place. Good neck range of motion. Able to palpate trunk valve and catheter with no disconnections and no edema. Cardiovascular: Regular pulse rate and rhythm. Respiratory: No stridor. No use of accessory muscles of inspiration. No cyanosis. Good range of motion of all extremities with no noted joint deformities. Skin warm, dry and pink. Neurologic: Delayed mental status. Symmetric and intact facial movement. Tongue protrusion to the midline. He has good strength of all 4 extremities and he moves all 4 extremities spontaneously. He has increased tone with right

Problem List/Past Medical History
Ongoing
- Acute vomiting
- Bronchopulmonary dysplasia
- Childhood asthma
- Cochlear implant in situ
- Developmental delay
- Dysarthria
- Feeding difficulties and mismanagement
- Hearing loss
- Mixed receptive-expressive language disorder
- Sensorineural hearing loss, bilateral
- Spastic quadriplegic cerebral palsy
- Wheeze

Historical
- Speech delay

Procedure/Surgical History
Cochlear device implantation, with or without mastoidectomy (02/02/2017), Cochlear device implantation, with or without mastoidectomy (02/02/2017).

Medications
- acetaminophen, 160 mg = 5 mL, PO, Q4hr, PRN
- aerochamber with medium mask, See Instructions
- albuterol 1.25 mg/3 mL (0.042%) inhalation solution, 1.25 mg, INH, Q4hr, PRN
- Diastat AcuDial 10 mg rectal kit, 10 mg, PR, As Directed, PRN
- Flovent HFA 110 mcg/inh inhalation aerosol, 2 puff, INH, daily
- Keppra 100 mg/mL oral solution, 200 mg = 2 mL, PO, BID
- Nebulizer machine, See Instructions
- Vitamin D3 400 intl units/mL oral liquid, 400 unit = 1 mL, PO, daily

Ambulatory Documentation

tighter than left and more increased in upper extremities than his lower extremities. He had brisk reflexes that were symmetric throughout.

His sutures were removed during this visit without complication.

Assessment/Plan
In summary, Abdulla is a 3-year-old male with history of hydrocephalus due to IVH of prematurity and VP shunt placement with multiple revisions with his last revision being in September 2017. I was pleased to hear that Abdulla has been well since leaving the hospital. I have no neurosurgical concerns for him at this time. A CT performed today showed stability of the ventricles and that should serve as a new baseline for him going forward. We can see him annually in follow-up if the family wishes to do so. The sutures were removed without complication and I advised the family to follow-up with his primary care provider when they return home to the UAE. I spent spent greater than 50% of this visit in direct face-to-face counseling with the family regarding the CT results, my thoughts and recommendations. It was a pleasure meeting with Abdulla and his mother today. Thank you for allowing us to participate in their care, please do not hesitate to call us with any questions or concerns.
Sincerely,
Ashley K. Birch, CPNP
Department of Neurosurgery
Boston Children´s Hospital

Allergies
No known allergies

Social History
Assistive Technology Right - Audiology
Hearing Device Cochlear Implant. Manufacturer Cochlear Americas. Model Internal: CI522; External: CP950 & CP910. Serial Number Internal: 1020170202749. Date Fit Surgery: 2/2/2017; Activation: 2/21/2017. Battery Size 675. Rechargeable Battery Lithium ion (CP910 only).
Basic Social History
Living Arrangement Parent(s)/Guardian. Legal Guardian: Parent. Lives With: Mother, Father, Brother, nanny. Language Spoken at Home: English and Arabic.
Home/Environment
Living situation: Home with assistance. Devices or Anatomic Adaptations: Ventriculoperitoneal shunt, Glasses, Hearing aides. Home equipment: Adaptive stroller, Ankle foot orthoses (AFO's).

Family History
Developmental delay: Brother.
Seizures: Cousin.

Diagnostic Results
CT-Head w/o Contrast
HISTORY: Hydrocephalus status post ventriculoperitoneal shunt.
COMPARISON: Multiple prior examinations including most recent head CT dated 9/7/2017
TECHNIQUE: The study consists of axial images from the skull base to slightly below the vertex; the vertex of the brain was not included in the field of view. No intravenous contrast was administered.
FINDINGS: Resolved pneumocephalus. Left frontal-approach ventriculostomy catheter terminates in similar position in the foramen of Monro/third ventricle. Asymmetry of the ventricles persists with the right decompressed and the left enlarged, but not significantly changed as compared to 9/7/2017. There is no evidence of acute intracranial hemorrhage. There are no

Ambulatory Documentation

parenchymal density
abnormalities, mass lesions, hydrocephalus, or extracerebral
collections.
IMPRESSION: Ventricular size not significantly changed from 9/7/2017
with interval resolution of pneumocephalus. This exam should serve as
a new baseline for ventricular size.
I, the teaching physician, have reviewed the images with the trainee
and agree with the findings [1]

[1] CT-Head w/o Contrast; Macquilken, Lisa 09/26/2017 12:44 EDT

Boston Children's Hospital
300 Longwood Avenue
Boston, MA 02115

BCH MRN: **500-20-94**
Patient Name: **ALDHAHERI, ABDULLA KHALIFA**
DOB/Age/Sex: 2/18/2014 3 years Male

Admit Date: 12/28/2016
Discharge Date: 12/28/2016

Patient Location: Neurosurgery Foundation
Patient Type: Outpatient
Financial #: 6120093809

Ambulatory Documentation

DOCUMENT NAME:	Neurosurgery Visit
SERVICE DATE/TIME:	12/28/2016 14:47 EST
PERFORM INFORMATION:	WARF MD,BENJAMIN C (1/13/2017 15:01 EST)
SIGN INFORMATION:	WARF MD,BENJAMIN C (1/16/2017 17:37 EST)
RESULT STATUS:	Auth (Verified)

DATE OF BIRTH: 02/18/2014

DATE OF VISIT: 12/28/16
NEUROSURGERY CLINIC

Dear Doctor,

It was our pleasure to see Abdulla in the clinic today for neurosurgical follow-up. He is accompanied to the appointment today by his mother and father. This is done in collaboration with Dr. Benjamin Warf, attending neurosurgeon. As you know Abdulla is a 2-year-old male with a past medical history significant for IVH of prematurity with resultant hydrocephalus. Abdulla was born at 25 weeks and was a triplet. The other surviving triplet was previously seen by Dr. Warf in consultation for hydrocephalus and required no treatment. Abdulla, however, required treatment for hydrocephalus at 2 months of age in the UAE, which is where he and his family are from. He required no operations after placement of his shunt but unfortunately underwent a revision in February of this year. Abdulla has also been diagnosed with spastic quadriplegia, cerebral palsy with superimposition of right hemiplegia, global developmental delay, and hearing loss. He is going to have cochlear implants placed next month. He did have an emergency room visit in November of this year, for lethargy, vomiting, and decreased appetite, a shunt malfunction was ruled out and it was thought to be a virus. An x-ray performed in October as part of his cochlear workup showed that he had a Medos valve and it was set at 70. We saw Abdulla 2 weeks ago in clinic and Dr. Warf thought that the cyclic nature of his symptoms in the beginning of this year and the very small size of the ventricles on MRI we suggestive of slit ventricle syndrome. We reprogrammed Abdulla's shunt valve at that time, to be set to 100 to allow for less flow and therefore less drainage of CSF out of the ventricles. The thought was that this would allow the ventricles to be a bit bigger in size and stop the symptoms of slit ventricles. On review of systems the family denies vomiting, lethargy, irritability, abnormal eye movements, and new weakness of the arms and legs.

His past medical history is listed above. He was born at 25 weeks.

His family medical history is significant for a twin with hydrocephalus that did not require treatment. He is actually one of triplets and the 3rd baby died at approximately 40 weeks from complications from

Ambulatory Documentation

prematurity. His brother also has significant delays, worse than Abdulla's. Other than that, his family members are healthy.

He lives in the UAE with his 3 sisters, 2 brothers, mother and father.

Allergies: No known allergies

Home Medication List (Medication Name Only)

**** List generated 01/13/2017 at 14:50. For updated home medication list with details, consult PowerChart Medication List. ****

- aerochamber with medium mask (Misc Prescription)
- albuterol (albuterol 1.25 mg/3 mL (0.042%) inhalation solution)
- fluticasone (Flovent HFA 110 mcg/inh inhalation aerosol)
- Nebulizer machine (Misc Prescription)

A complete review of systems was performed with positive systems within history of present illness and past medical history and all others negative.

PHYSICAL EXAMINATION: Constitutional: Alert, no distress, cooperative and pleasant. Weight: 13.335 kg. Heart rate 130. Respiratory rate 31. Patient in pain now, no. Eyes: Pupils equal and reactive to light bilaterally. Full extraocular movements. HENT: Dolichocephalic, atraumatic. Good neck range of motion. Able to palpate trunk valve and catheter with no disconnections and no edema. Cardiovascular: Regular pulse rate and rhythm. Respiratory: No stridor. No use of accessory muscles of inspiration. No cyanosis. Good range of motion of all extremities with no noted joint deformities. Skin warm, dry and pink. Neurologic: Delayed mental status. Symmetric and intact facial movement. Tongue protrusion to the midline. He has good strength of all 4 extremities and he moves all 4 extremities spontaneously. He has increased tone with right tighter than left and he is much tighter in his upper extremities than his lower extremities. He had brisk reflexes that were symmetric throughout.

IMAGING: MRI 12/27- Following shunt valve up dialing performed 12/12/2016 (from 30 to 100 mm), there is expected mild increase in size of the shunted left lateral ventricle relative to 10/28/2016 (shunt valve then 70-75mm). Remaining ventricular system remains decompressed in appearance (near ependymal coaptation), and there is no convincing evidence of abnormal CSF mechanics.

IMPRESSION: In summary, Abdulla is a 2-year-old male triplet with a history of significant prematurity and IVH with resultant hydrocephalus, treated with a VP shunt with medos valve. Dr. Warf spent greater than 50% of this visit in direct face-to-face counseling with the family regarding MRI results and recommendations. Dr. Warf explained to the family that the adjustment of the valve setting had the

Ambulatory Documentation

expected results and the ventricles are larger on MRI which was the desired outcome. He was happy to hear that clinically Abdulla has remained well. He explained that he would like to leave the valve at it's current setting for now as this seems to have helped with Abdulla's symptoms. He answered the family's questions about ETV and explained that Abdulla would not be the ideal candidate because his ventricles are so small that it would make the operation very technically difficult. He did say that id Abdulla hd a true malfunction and the ventricles were much larger at that time it could be attempted, but that this was not likely to be a good option for him if he continues to have small ventricles. The family was understanding of this. The family should continue to monitor for signs of hydrocephalus such as vomiting, headache, and lethargy.
It was a pleasure meeting with Abdulla and his family today. Thank you for allowing us to participate in his care. Please do not hesitate to call with any questions or concerns.

Sincerely,
Ashley K. Birch, CPNP
Benjamin Warf, MD
Department of Neurosurgery
Boston Children’s Hospital

Boston Children's Hospital
300 Longwood Avenue
Boston, MA 02115

BCH MRN: **500-20-94**
Patient Name: **ALDHAHERI, ABDULLA KHALIFA**
DOB/Age/Sex: 2/18/2014 3 years Male

Admit Date: 12/12/2016
Discharge Date: 12/12/2016

Patient Location: Neurosurgery Foundation
Patient Type: Outpatient
Financial #: 6119954193

Ambulatory Documentation

DOCUMENT NAME:	Neurosurgery Visit
SERVICE DATE/TIME:	12/12/2016 00:00 EST
PERFORM INFORMATION:	WARF MD,BENJAMIN C (1/4/2017 12:41 EST)
SIGN INFORMATION:	WARF MD,BENJAMIN C (1/4/2017 12:41 EST)
RESULT STATUS:	Auth (Verified)

DATE OF BIRTH: 02/18/2014

DATE OF VISIT: 12/12/16
NEUROSURGERY CLINIC

Dear Doctor,

It was our pleasure to see Abdulla in the clinic today for neurosurgical consult. He is accompanied to the appointment today by his mother and father. This is done in collaboration with Dr. Benjamin Warf, attending neurosurgeon. Abdulla is a 2-year-old male with a past medical history significant for IVH of prematurity with resultant hydrocephalus. Abdulla was born at 25 weeks and was a triplet. The other surviving triplet was previously seen by Dr. Warf in consultation for hydrocephalus and required no treatment. Abdulla, however, required treatment for hydrocephalus at 2 months of age in the UAE, which is where he and his family are from. He required no operations after placement of his shunt but unfortunately underwent a revision in February of this year. He presented initially with symptoms in December of last year, where he had lethargy, vomiting and weakness, and these symptoms continued for 2 months. They would happen for a day and then resolve, and in February he was admitted to the hospital and had continuous symptoms for 5 days. At that time, the decision was made to revise his shunt. Abdulla has also been diagnosed with spastic quadriplegia, cerebral palsy with superimposition of right hemiplegia, global developmental delay, and hearing loss. His parents hope that he will undergo placement of cochlear implants next month. In November of this year, Abdulla presented to the emergency room here at Children's with lethargy, vomiting, and not eating. His parents were concerned he was having another shunt malfunction. He was found to have a fever at this time and it was determined that he had a virus. This did resolve. Other than this event, Abdulla has been well. An x-ray performed in October as part of his cochlear workup showed that he had a Medos valve and it was set at 70 at that time.

His past medical history is listed above. He was born at 25 weeks.

Ambulatory Documentation

His family medical history is significant for a twin with hydrocephalus that did not require treatment. He is actually one of triplets and the 3rd baby died at approximately 40 weeks from complications from prematurity. His brother also has significant delays, worse than Abdulla's. Other than that, his family members are healthy.

He lives in the UAE with his 3 sisters, 2 brothers, mother and father.
HE HAS NO KNOWN ALLERGIES and he takes no medications at this time.

A complete review of systems was performed with positive systems within history of present illness and past medical history and all others negative.

PHYSICAL EXAMINATION: Constitutional: Alert, no distress, cooperative and pleasant. Weight: 13.19 kg. Heart rate 120. Respiratory rate 29. Patient in pain now, no. Eyes: Pupils equal and reactive to light bilaterally. Full extraocular movements. HENT: Dolichocephalic, atraumatic. Good neck range of motion. Able to palpate trunk valve and catheter with no disconnections and no edema. Cardiovascular: Regular pulse rate and rhythm. Respiratory: No stridor. No use of accessory muscles of inspiration. No cyanosis. Good range of motion of all extremities with no noted joint deformities. Skin warm, dry and pink. Neurologic: Delayed mental status. Symmetric and intact facial movement. Tongue protrusion to the midline. He has good strength of all 4 extremities and he moves all 4 extremities spontaneously. He has increased tone with right tighter than left and he is much tighter in his upper extremities than his lower extremities. He has recently had Botox. Parents explain that without the Botox, he would not be able to open his right hand or move his arm well and he is doing both during this, so he is still noted to have increased tone. He had brisk reflexes that were symmetric throughout.

IMAGING: Recent imaging obtained in October 2016 showed a decompressed appearance to the ventricular system.

IMPRESSION: In summary, Abdulla is a 2-year-old male triplet with a history of significant prematurity and IVH with resultant hydrocephalus, treated with a Methocel VP shunt. He presents to us today for discussion of his shunt and his parents would like to hear more about ETV. Dr. Warf spent greater than 50% of this visit in direct face-to-face counseling with the family regarding MRI results and recommendations. Dr. Warf explained that Abdulla's symptoms do sound similar to what is called ventricle syndrome. The cyclic nature of his symptoms in the beginning of this year and the very small size of the ventricles on MRI are suggestive of that. What he would like to do is reprogram Abdulla's shunt valve today, to be set to 100 to allow for less flow and therefore less drainage of CSF out of the ventricles and hopefully to make them a bit bigger. The family was in agreement with this plan. We readjusted his shunt valve after the x-ray. The x-ray showed that it was set at 30, not 100. Abdulla came back. We readjusted the valve. He had another x-ray, which then showed and confirmed the setting of 100 of Abdulla's shunt. Dr. Warf would like to see Abdulla back in 2 weeks' time with MR ventricle check to see the size of the ventricles as we did change the setting today. We also would like the family to

Ambulatory Documentation

continue to monitor him for changes in his symptoms and to call us if there are any changes. The family was in agreement with this plan. Dr. Warf explained that it would be difficult to perform an ETV on a child like Abdulla because he has such small ventricle size. The family was understanding of this. He did explain that if there was a shunt malfunction, he would likely replace the shunt valve to a strata programmable valve rather than a Medos/Codmas as it is easier to adjust. We will see this family again in 2 weeks and discuss a long-term followup plan for Abdulla.

It was a pleasure meeting with Abdulla and his family today. Thank you for allowing us to participate in his care. Please do not hesitate to call with any questions or concerns.

Sincerely,
Ashley K. Birch, CPNP
Benjamin Warf, MD
Department of Neurosurgery
Boston Children’s Hospital

Boston Children's Hospital
300 Longwood Avenue
Boston, MA 02115

BCH MRN: **500-20-94**
Patient Name: **ALDHAHERI, ABDULLA KHALIFA**
DOB/Age/Sex: 2/18/2014 3 years Male

Admit Date: 9/11/2017
Discharge Date: 9/11/2017

Patient Location: Audiology Waltham
Patient Type: Outpatient
Financial #: 6120784940

Ambulatory Documentation

DOCUMENT NAME:	Nutrition Visit
SERVICE DATE/TIME:	7/13/2017 10:19 EDT
PERFORM INFORMATION:	GRUNKO RD,AMINA (7/18/2017 10:26 EDT)
SIGN INFORMATION:	GRUNKO RD,AMINA (7/18/2017 10:26 EDT)
RESULT STATUS:	Auth (Verified)

DATE OF BIRTH: 02/18/2014
NUTRITION ASSESSMENT

CLIENT HISTORY: Abdulla is a 3 year and 4 month old who presents with his mother, and Mohamed's sibling Abdullah, for a nutrition follow up. As you know, Mohamed is one of triplets who was born at 25 weeks and 5. Mohamed has a history of spastic quadriplegia with CP, IVH with a VP shunt and ROP. He was initially seen by me back on 12/6/16. He had an MBS on 4/4/17 which showed **no aspirationi** with fluids. For additional information please refer to the SLP report of 4/4/17. He was last seen by me on 5/4/17.

A typical day is as follows:
Breakfast: 2c baby oatmeal cereal made with water and sips of thickened water
Lunch: One cup of a combination of rice, some type of meat such as chicken or lamb, tomato sauce, and some soft bread; 1 c yogurt is mixed into this.
Dinner: Very similar to lunch, rice or potatoes with meat and tomato sauce and more yogurt.

Abdulla typically eats better than Mohamed. He usually finishes most meals.

Abdulla is reported to have no vomiting or reflux. He has really good bowel movements daily. His current medications include Baclofen and a few inhalers such as Flovent and Albuterol.

Mom's is mostly concerned about his drinking ability and the lack of his intake. He is not on any additional herbs or vitamins.

ANTHROPOMETRIC MEASUREMENTS:
Weight 13.57 kg, 18 percentile, Z-score -0.92
Length 88.0 cm, <3 percentile, Z-score -2.57
Weight for Length 80 percentile, Z-score -0.85
BMI 17.5 kg/M2, 90 th percentile, Z-score -1.28

Abdulla has gained 470 grams since I saw him in May. He is presenting without wasting or stunting. He has continued to make good progress on the growth curve. His intake seems to provide him an average of 900-1300 cal/day, per rerport.
I suspect his lenght measurement may be inaccurate, which makes his BMI and weight/lenght close to being off the cart. We will double check his lenght at his next CCS or GI visit for accuracy.

NUTRITION DIAGNOSIS: Feeding difficulties related to complicated medical history or prematurity of birth and IVH as evidenced by reports from mother of lack of adequate drinking and chewing skills. (resolving).

Ambulatory Documentation

NUTRITION INTERVENTION:
PRESCRIPTION: Diet as tolerated

1. Nutrition counseling and education on ways to increase caloric density of meals. Mom and nanny aware of ways to increase calories and will continue using Duocal powder as it will help in the long run for both siblings.
- Pediasure supplements were provided and Abdulla may have them as part of meals as well.

2. Collaboration with other providers: Continue to followup with CCS and Nutrition.

NUTRITION MONITORING AND EVALUATION:

1. Weight/BMI
2. Types of foods and meals.

Thank you for allowing me to participate in Abdulla's care. I met with the family for 45 minutes, followup as needed in three months.
Amina Grunko, MS, RD, LDN
Clinical Nutrition Specialist II

Boston Children's Hospital
300 Longwood Avenue
Boston, MA 02115

BCH MRN: **500-20-94**
Patient Name: **ALDHAHERI, ABDULLA KHALIFA**
DOB/Age/Sex: 2/18/2014 3 years Male

Admit Date: 12/27/2016
Discharge Date: 12/27/2016

Patient Location: MRI Radiology
Patient Type: Outpatient
Financial #: 6120097689

Radiology

ACCESSION	EXAM DATE/TIME	PROCEDURE	ORDERING PROVIDER	STATUS
RA-16-0238320	12/27/2016 16:44 EST	MR-Brain/Vent Check Limited	WARF MD,BENJAMIN C	Modified

CDM code
2264000067
F70551

Reason For Exam
(MR-Brain/Vent Check Limited) shunt check

Report

This report is flagged for special attention.

MRI BRAIN WITHOUT CONTRAST (VENTRICLE CHECK)

INDICATION: Former 25 week premature triplet with posthemorrhagic hydrocephalus status post ventriculoperitoneal shunt, reportedly last revised February 2016. The shunt valve was reset from 30 to 100 mm of water December 12 due to suspected slit ventricle syndrome.

TECHNIQUE: MRI of the brain was obtained using single shot axial T2 technique. No contrast administered.

COMPARISON: Brain MRI October 28, 2016 and February 17, 2016

FINDINGS:
There is redemonstration of a left occipital approach shunt catheter with tip located in the body of the left lateral ventricle, adjacent to the site of the cavitated left thalamus. This position is unchanged.

In the setting, the ventricles continue to have mild prominence of the left lateral ventricle with near ependymal coaptation in the remaining supratentorial ventricular system. However, the body of the left lateral ventricle has slightly increased as expected with recent updialing of the shunt valve setting. For example, the body of the left lateral ventricle now measures 15 mm transverse compared to 11 mm at the same level October 28 (bodies of the lateral ventricles were 17mm on the right and 32 mm on the left in February 2016 prior to shunt revision) . There remains no abnormal fluid collection.

Radiology

ACCESSION	EXAM DATE/TIME	PROCEDURE	ORDERING PROVIDER	STATUS
RA-16-0238320	12/27/2016 16:44 EST	MR-Brain/Vent Check Limited	WARF MD,BENJAMIN C	Modified

Report

This study is not tailored to evaluate the brain parenchyma in detail and is further hampered by susceptibility artifact from the shunt valve in the left suboccipital scalp. However, there is redemonstration of profound deep/periventricular white matter volume loss, greatest posteriorly where there is periventricular gliosis, with more focal volume loss in the left frontoparietal lobes and left thalamus (related right cerebellar volume loss). These findings are consistent with a combination of white matter injury of prematurity and left hemisphere grade 4 germinal matrix hemorrhage with right crossed cerebellar diaschisis. There is also some signal abnormality along a prior right occipital shunt catheter tract. These findings are grossly stable. There is no gross new parenchymal signal abnormality. Although there is some chronic distortion of the midline due to parenchymal volume loss, there remains no basal cistern effacement or frank brain herniation.

The major intracranial flow voids are segmentally visualized as is common for technique. There is mild to moderate paranasal sinus mucosal thickening and near total opacification of the mastoid air cells and middle ear cavities, the latter having increased since October 2016. Advise correlation for symptoms of ongoing sinusitis/ otomastoiditis versus recent upper respiratory illness. Orbital contents are unremarkable though there is suggestion of optic nerve atrophy.

IMPRESSION:
This study is tailored to evaluate the fluid spaces only. It should not replace a full brain MRI.

Following shunt valve up dialing performed 12/12/2016 (from 30 to 100 mm), there is expected mild increase in size of the shunted left lateral ventricle relative to 10/28/2016 (shunt valve then 70-75mm). Remaining ventricular system remains decompressed in appearance (near ependymal coaptation), and there is no convincing evidence of abnormal CSF mechanics.

Extensive parenchymal sequela of prematurity, unchanged.

Mild to moderate paranasal sinus opacification is now accompanied by increased, near total opacification of the mastoid air cells and middle ear cavities. Advise correlation for recent/ongoing upper respiratory illness or sinusitis/otomastoiditis.

Findings discussed with Dr. Hamzaa of neurosurgery who confirmed a

Radiology

ACCESSION	EXAM DATE/TIME	PROCEDURE	ORDERING PROVIDER	STATUS
RA-16-0238320	12/27/2016 16:44 EST	MR-Brain/Vent Check Limited	WARF MD,BENJAMIN C	Modified

Report

ventricle change of this magnitude is expected for a shunt valve manipulation. Findings also communicated to Dr. Warf by email 12/27/16 5:12 PM (has appointment tomorrow).

***** *Final Report*****

Dictated by: YANG MD, PhD, EDWARD 12/27/2016 16:47

Verified by: YANG MD, PhD, EDWARD 12/27/2016 17:27

Boston Children's Hospital
300 Longwood Avenue
Boston, MA 02115

BCH MRN: **500-20-94**
Patient Name: **ALDHAHERI, ABDULLA KHALIFA**
DOB/Age/Sex: 2/18/2014 3 years Male

Admit Date: 10/28/2016
Discharge Date: 10/28/2016

Patient Location: MRI Radiology
Patient Type: Outpatient
Financial #: 6119696389

Radiology

ACCESSION	EXAM DATE/TIME	PROCEDURE	ORDERING PROVIDER	STATUS
RA-16-0197399	10/28/2016 09:32 EDT	MR-Brain (Temporal Bones) w/o Contrast	COULTER MD,DAVID L	Modified

CDM code
2264000061
F70551

Reason For Exam
(MR-Brain (Temporal Bones) w/o Contrast) ex preemie with shunted hydrocephalus, s/p stem cell infusion

Report

This report is flagged for special attention.

MRI BRAIN AND TEMPORAL BONES WITHOUT CONTRAST

INDICATION: Former 25 week premature triplet with history of intraventricular hemorrhage and shunted hydrocephalus (last revision February 2016). Clinical issues include spastic quadriparesis, global developmental delay, and unclear auditory evaluation (abnormal brainstem reflexes on outside evaluation but behavioral hearing test at BCH elicited responses). Establishing care at this hospital.

TECHNIQUE: MRI of the brain was performed using sagittal T1 weighted, axial FLAIR, DWI, and axial/coronal T2 weighted sequences at 3 Tesla . MRI of the temporal bones was performed using axial T2 SPACE and sagittal oblique T2 SPACE sequences. No intravenous contrast was administered.

COMPARISON: CT of the head 2/18/2016 and brain MRI 2/17/2016

FINDINGS:
BRAIN:
There are extensive sequelae of prematurity.

Specifically, there is profound loss of cerebral white matter, left worse than right and posterior greater than anterior. There is associated decrease of the fractional anisotropy within the retrolental internal capsules and the posterior thalamic radiations. These are typical findings of white matter injury of prematurity. Additionally, there is focal cavitation/porencephaly within the left deep white matter and left thalamus/PLIC consistent with prior grade

Radiology

ACCESSION	EXAM DATE/TIME	PROCEDURE	ORDERING PROVIDER	STATUS
RA-16-0197399	10/28/2016 09:32 EDT	MR-Brain (Temporal Bones) w/o Contrast	COULTER MD,DAVID L	Modified

Report

IV germinal matrix hemorrhage (venous infarction), and small size of the right cerebellum may be related (crossed cerebellar diaschisis versus posterior fossa germinal matrix hemorrhage). There may be some overlapping periventricular gliosis from prior decompensated bouts of hydrocephalus. The above pattern of parenchymal signal abnormality is unchanged since February 2016.

The overall myelination pattern is normal separate from the areas of parenchymal injury. There is no discrete congenital structural abnormality allowing for diffuse stenogyria attributed to prior hydrocephalus. Artifactual appearance of hypothalamic fusion is due to coaptation of the third ventricle (was cleaved in February).

In the setting of probable occlusion of the cerebral aqueduct (i.e. from prior hemorrhage), the ventricles are decompressed with nearly coapted ependyma apart from focal dilation of the left lateral ventricle at the site of porencephaly and some minimal prominence of the common cavity lateral ventricle at the midline. This current appearance represents a marked improvement from the brain MRI/CT from February 2016, consistent with reported shunt revision. Currently, the left occipital shunt catheter terminates near the left thalamus. There is no abnormal fluid collection or evidence of recent intracranial hemorrhage. Although there is distortion of midline due to parenchymal volume loss, there is no generalized mass effect, significant midline shift, or basal cistern effacement.

Midline structures are notable for marked thinning of the corpus callosum and mild thinning of the brainstem proportionate to the supratentorial volume loss mentioned earlier. Cerebellar tonsils terminate at the foramen magnum. Pituitary and pineal glands have a grossly normal appearance for patient age.

The major intracranial flow voids are present. The middle ear cavities and mastoid air cells are partially opacified. There is also diffuse (moderate) mucosal thickening within the paranasal sinuses. These findings may reflect recent upper respiratory illness or ongoing sinusitis/otitis/mastoiditis. Advise clinical correlation.. Orbital contents are unremarkable.

TEMPORAL BONES:
On the right side, the external auditory canal is patent. The mastoid air cells and middle ear cavity are partially opacified as mentioned previously. The vestibulo-cochlear nerves are present and appear normal. The inner ear structures, including the semicircular canals,

Radiology

ACCESSION	EXAM DATE/TIME	PROCEDURE	ORDERING PROVIDER	STATUS
RA-16-0197399	10/28/2016 09:32 EDT	MR-Brain (Temporal Bones) w/o Contrast	COULTER MD,DAVID L	Modified

Report

vestibule, and cochlea have normal morphology and fluid signal. The endolymphatic sac is not enlarged.

On the left side, the external auditory canal is patent. The mastoid air cells and middle ear cavity are partially opacified as mentioned previously. The vestibulo-cochlear nerves are present and appear normal. The inner ear structures, including the semicircular canals, vestibule, and cochlea have normal morphology and fluid signal. The endolymphatic sac is not enlarged.

IMPRESSION:
Severe prematurity sequelae including marked white matter injury of prematurity (left greater than right) and prior grade 4 germinal matrix hemorrhage on the left. Small right cerebellar hemisphere may reflect crossed cerebellar diaschisis versus posterior fossa germinal matrix hemorrhage. Related volume loss within the corpus callosum and brainstem. This pattern of injury is unchanged since February 2016.

Status post February 2016 shunt revision, decompressed appearance of the ventricular system. Probable underlying aqueductal occlusion.

Unremarkable temporal bone MRI.
--Grossly normal appearance of the inner ear structures.
--Vestibulocochlear nerves are present.
--There is partial opacification of the mastoid air cells and middle ear cavities which may contribute to the patient's hearing loss.

There is moderate paranasal sinus mucosal thickening. The mastoid air cell partial opacification and the moderate paranasal sinus disease could reflect recent upper respiratory illness or ongoing sinusitis/ otomastoiditis. Advise clinical correlation.

***** *Final Report*****

Dictated by: YANG MD, PhD, EDWARD 10/28/2016 09:13

Verified by: YANG MD, PhD, EDWARD 10/28/2016 19:46

Boston Children's Hospital

300 Longwood Avenue
Boston, MA 02115

BCH MRN: **500-20-94**
Patient Name: **ALDHAHERI, ABDULLA KHALIFA**
DOB/Age/Sex: 2/18/2014 3 years Male

Admit Date: 9/21/2017
Discharge Date: 9/21/2017

Patient Location: Neurology Foundation
Patient Type: Outpatient
Financial #: 6121667511

Ambulatory Documentation

DOCUMENT NAME: Neurology Visit
SERVICE DATE/TIME: 9/21/2017 15:26 EDT
PERFORM INFORMATION: SROUJI NP,RASHA (9/21/2017 15:44 EDT)
SIGN INFORMATION: SROUJI NP,RASHA (9/21/2017 16:02 EDT)
RESULT STATUS: Auth (Verified)

Chief Complaint
Follow-up for seizure, recent admission

History of Present Illness
Dear Dr.
I had the pleasure of seeing your patient Abdulla Aldhaheri for a follow-up visit in the neurology clinic at Boston Children's Hospital today. Abdulla was accompanied by his mother who provided us with details of his presentation. As you know he is a 3-year-old ex-25 week male triplet with a history of IVH in the NICU with subsequent hydrocephalus status post VP shunt placement and cerebral palsy, hearing loss status post cochlear implant, no prior history of seizures (no AEDs) who presents today for an evaluation after recent hospital admission secondary to shunt malfunction/infection and seizure.
His mother reports that Abdulla was in his normal state of health on August 15, they were driving to Waltham for an audiology appointment. He seemed sleepier than usual and proceeded to have 3 episodes of emesis. Around 1:30 PM she noted intermittent left eye deviation and that Abdulla, head was persistently turned to the left. She describes that he was responsive and would shift his gaze to look at her. He was also noted to have flexion of the left arm and wrist with no rhythmic movements and leg jerking. Given the abnormal movements she decided to bring him directly to the ED. On route Abdulla became less responsive and was unable to break his gaze deviation. They arrived to the ED around 2:40 PM, at that point he had been having abnormal movements for approximately 1-1/2 hours. He was noted to have left eye deviation and bilateral tonic arm extension. He was given 1.4 mg IV Ativan at which point the movements seized. He then became apneic and required bagging. Abdulla was subsequent intubated for a stat CT scan which was read as stable. He was then noted to be hypertensive at 160/100. Neurosurgery attempted a shunt tap at bedside but was unable to draw back CSF. He then went emergently to the OR for left EVD placement. Overnight his respiratory culture returned with abundant polys, x-ray concerning for developing PNA and CSF culture that grew GNR's concerning for shunt/CNS infection. Abdulla went back to the OR on August 17 for a VP shunt removal, EVD left in place. He remained externalized until September 7 at which time he had re-internalization of the VP shunt.
During admission, and EEG was completed without evidence of seizure activity. Given his increased risk, he was started on Keppra 200 mg twice daily.
Abdulla was discharged from the hospital on September 11. Since discharge, his mother notes that he has been doing well. He seems to be tolerating the Keppra well with no excessive drowsiness, abdominal discomfort, changes in temperament or irritability. She does note that due to deconditioning and lack of movements during his hospital stay, his right side appeared weaker and his movement has regressed. He has been getting PT 2-3 times a week since being home and mother notes significant improvement. He is currently back to crawling and can pull himself up to stand. He was using the walker to ambulate prior to admission but has not done so yet. He has been sleeping well and his appetite is back to baseline. His mother's main concern for today was the duration of his Keppra

Problem List/Past Medical History
Ongoing
- Acute vomiting
- Bronchopulmonary dysplasia
- Childhood asthma
- Cochlear implant in situ
- Developmental delay
- Dysarthria
- Feeding difficulties and mismanagement
- Mixed receptive-expressive language disorder
- Sensorineural hearing loss, bilateral
- Spastic quadriplegic cerebral palsy

Historical
- Speech delay

Procedure/Surgical History
Cochlear device implantation, with or without mastoidectomy (02/02/2017), Cochlear device implantation, with or without mastoidectomy (02/02/2017).

Medications
- aerochamber with medium mask, See Instructions
- albuterol 1.25 mg/3 mL (0.042%) inhalation solution, 1.25 mg, INH, Q4hr, PRN
- Diastat AcuDial 10 mg rectal kit, 10 mg, PR, As Directed, PRN
- Flovent HFA 110 mcg/inh inhalation aerosol, 2 puff, INH, daily
- Keppra 100 mg/mL oral solution, 200 mg = 2 mL, PO, BID
- Nebulizer machine, See Instructions
- Vitamin D3 400 intl units/mL oral liquid, 400 unit = 1 mL, PO, daily

Allergies
No known allergies

Social History
Assistive Technology Right - Audiology

Ambulatory Documentation

dosing and plan to wean off.

With regards to his past medical history, Abdulla received care in the UAE prior to coming to the United States for further management. He had an IVH in the NICU leading to hydrocephalus necessitating VP shunt placement to 2 months of age. He has subsequently been followed in neurosurgery by Dr. Warf and was last seen in December 2016 after having his shunt reprogrammed for presumed split ventricle syndrome. His MR vent check showed expected changes after his shunt reprogramming with mildly increased left ventricular size.

He has been followed by Dr. Coulter and neurology since September 2016. He was last seen in clinic on March 13 at which time he was doing well. Per Dr. Coulter's recommendations he had an out patient MRI on October 2016 which showed white matter injury of prematurity left > right, prior grade IV germinal matrix hemorrhage on the left, small right cerebellar hemisphere and volume loss of the corpus callosum and brainstem. He also had a routine outpatient EEG on October 2016 which showed some asymmetry of sleep features that are developed over the left hemisphere.

Scales and Assessments
Patient In Pain Now: No

Review of Systems
Abdulla's mother filled out our comprehensive review of systems questionnaire. Other than symptoms noted above, review is unremarkable and will be scanned into his chart for further reference.

Physical Exam

Vitals & Measurements
HR: 148 (Monitored)
Weight: 14.415 kg (26%ile)*; Height: 91 cm (2%ile)*; Stature Type: Supine; Head Circumference: 50 cm; Body Mass Index: 17.4 kg/m2 (90%ile)*
*CDC chart used to calculate percentile value.

Physical Exam:_
Sitting comfortably in while chair.
Head and face: elongated head , shunt insitu
Neck: Supple.
CVS: regular rhythm, rate, no murmur noted
Chest: clear with good air entry to baseline
Skin: No obvious rash, induration or neurocutaneous stigmata

Neurological exam:
Mental Status: Alert, interactive, vocalizes, engages with examiner
Cranial Nerves: Eye movements intact without clear nystagmus. PERRL, facial symmetric to smile and grimace but with baseline facial hypotonia
Motor: increased tone in bilateral lower extremities, right upper extremity favors Left side
Reflexes: Biceps, Patella, 2+ bilaterally. Babinski upgoing bilaterally.
Sensory: Intact to light touch
Coordination: deferred
Gait: deferred

Assessment/Plan
In summary, Abdulla is a 3-year-old ex-25 week male triplet with a history of intracranial hemorrhage in the NICU with subsequent hydrocephalus status post VP shunt placement and cerebral palsy who was admitted to the hospital on August 15 for seizure likely

Hearing Device Cochlear Implant.
Manufacturer Cochlear Americas. Model Internal: CI522; External: CP950 & CP910. Serial Number Internal: 1020170202749. Date Fit Surgery: 2/2/2017; Activation: 2/21/2017. Battery Size 675. Rechargeable Battery Lithium ion (CP910 only).

Basic Social History
Living Arrangement Parent(s)/Guardian.
Legal Guardian: Parent. Lives With: Mother, Father, Brother, nanny. Language Spoken at Home: English and Arabic.

Home/Environment
Living situation: Home with assistance.
Devices or Anatomic Adaptations: Ventriculoperitoneal shunt, Glasses, Hearing aides. Home equipment: Adaptive stroller, Ankle foot orthoses (AFO's).

Family History
Developmental delay: Brother.
Seizures: Cousin.

Immunizations
Up-to-date

Diagnostic Results
6/6 @ 1912 CT HEAD
Small caliber of the ventricular system with slight reduction in caliber of the shunted left lateral ventricle since December 2016. Therefore, there is no imaging evidence for shunt failure. To the contrary, the observed change could reflect over shunting or down-dialing of shunt valve setting. Advise clinical correlation. No acute intracranial hemorrhage or fluid collection allowing for streak artifact from new cochlear implant (see below).
Extensive but stable sequela of prematurity, possibly with superimposed sequela of prior decompensated bouts of hydrocephalus.
Placement since December 2016 of a right cochlear implant. While this study is not tailored to evaluate the temporal bone, the cochlear implant and associated electrode appear appropriately positioned.

8/15 CT head:
Stable shunt position with stable size and morphology of the ventricular system. No acute intracranial hemorrhage, extra axial fluid

Ambulatory Documentation

secondary to secondary to shunt malfunction/ infection. His EEG did not show any seizure activity but asymmetry (right spindles, left temporal slowing). He was started on Keppra 200 mg twice daily. His exam today is stable.
We discussed that given his increased risk of seizures following his recent infection and shunt re-internalization we recommend that he continue on keppra for now. He seems to be tolerating it well and is on a fairly low dose. We would recommend that Abdulla continue on the Keppra for at least 3 months (November, 15th 2017). If he remains seizure-free, he can then wean off to 100 mg twice daily for 3-5 days and then discontinue.
I provided the family with a prescription for 3 months. Abdulla is clear to travel/ return to the UAE from a neurological perspective. We would like to follow-up with him when he returns to Boston next year.
Thank you for allowing us to participate in Abdulla's care, if you have any questions or new information relevant to his care please do not hesitate to contact us.

Sincerely

Rasha Srouji MN CPNP

Department of neurology

collection or new parenchymal abnormal density allowing for streak artifact from the cochlear implant which obscures portions of the brain. Grossly stable position of a right cochlear implant electrode. New paranasal sinus mucosal disease.

8/15 CT head:
1.New left frontal approach EVD with tip just within the body of the left lateral ventricle. Advise correlation with drain output.
2.Stable left parietal approach shunt catheter.
3.There remains mild distention of the porencephalic left lateral ventricle with ependymal coaptation of the remaining ventricular system. Degree of left lateral ventricle distention is minimally increased in the left occipital horn since the 3:30 PM study, but the ventricular system is otherwise stable
4.Within the limitations of a
partial field-of-view (posterior fossa excluded) and some streak artifact from the right cochlear implant, no acute intracranial hemorrhage or new parenchymal finding after ventriculostomy insertion.
5.Stable sequela of prematurity.

8/18 CT head:
1.Streak artifact limiting complete assessment of the head and
intracranial contents.
2.Removal of the left occipital shunt catheter.
3.Left frontal EVD.
4.Interval increase in the size of the ventricles suggesting
inadequate CSF diversion/inadequate shunting.
5.Fluid accumulation within the left occipital scalp region
suggesting same (CSF expression).
6.Tip of the EVD is suboptimally positioned with most of the side
holes extraventricular.
7.New intraventricular blood.
8.Soft tissue abnormality of the hypothalamus/interpeduncular cistern
. This likely represents midline fusion of the hypothalamus and
frontal lobes rather than hypothalamic hamartoma or mass. Attention
to this on follow-up imaging is recommended.
9.Periventricular leukomalacia, left greater than right.
10.Right-sided cross cerebellar diaschisis.

Ambulatory Documentation

11.Near complete opacification of the mastoid air cells and middle
ear cavities with air-fluid levels possibly representing
otomastoiditis.

Boston Children's Hospital
300 Longwood Avenue
Boston, MA 02115

BCH MRN: **500-20-94**
Patient Name: **ALDHAHERI, ABDULLA KHALIFA**
DOB/Age/Sex: 2/18/2014 3 years Male

Admit Date: 3/13/2017
Discharge Date: 3/13/2017

Patient Location: Neurology Foundation
Patient Type: Outpatient
Financial #: 6120049254

Ambulatory Documentation

DOCUMENT NAME:	Neurology Visit
SERVICE DATE/TIME:	3/13/2017 00:00 EDT
PERFORM INFORMATION:	COULTER MD,DAVID L (3/13/2017 15:52 EDT)
SIGN INFORMATION:	COULTER MD,DAVID L (3/15/2017 13:54 EDT)
RESULT STATUS:	Auth (Verified)

Dear Sir,

I saw Abdulla Aldhaheri back in followup on March 13, 2017. He is a 3-year-old boy with cerebral palsy whom I last saw back in December. I reviewed his history when I first saw him on September 22, 2016. He has hydrocephalus and a shunt, and has also been seen by Dr. Warf, most recently on December 28, 2016. Overall, Dr. Warf thought he was doing pretty well and indicated that he would like to leave the valve at its current setting for now.

We had also done an EEG on October 24, 2016, which did not show any epileptiform or seizure activity.

Since that time, Abdulla has received a cochlear implant on the right, which seems to be working pretty well. His mother said that for the first week, he really did not have much of a response, but since then, he has been responding better. He has only had it for about 3 weeks now and is still learning to recognize sounds, but he does seem to turn to sounds and voices and is making good progress in speech therapy.

His mother did indicate that Abdulla and his brother will be starting preschool in the Dedham public school system next month. She said they will be coming to the house to do the evaluation and expect to have an IEP ready shortly afterward.

Otherwise, I think he has been doing well. He does have a slight cold today.

I reviewed his medication list today. He really does not take much. He does take vitamin D 400 units once a day as well as Flovent once a day. He has albuterol as needed for wheezing.

Today, he was pretty comfortable in the stroller. His mother said that he is making progress with his motor skills. He is using a walker and is beginning to be able to crawl on his hands and knees. He was wearing his bilateral AFO braces today.

I note that his weight was 13.9 kg on March 3, 2016 and his height was 91 cm, also on March 3, 2017. He really maintained good eye contact and fixation, and seemed to respond to voice. His tone was pretty

Ambulatory Documentation

good on passive range of motion today. His mother said that he had gotten Botox last fall and is probably due again this coming summer.

I did not see any abnormal involuntary movements today. He was not in any pain, discomfort or distress.

Thus, overall, I think Abdulla is doing quite well. I did not have any additional suggestions today. I am glad that he will be starting preschool and will look forward to seeing what the IEP provides for him.

I would like to see him back again in July, which should be after he has had some additional services. I appreciate very much the opportunity to see him today.

Sincerely,

David L. Coulter, MD
Department of Neurology

CC:

International Office

Children's Hospital

300 Longwood Avenue

Boston, MA 02115

Boston Children's Hospital

300 Longwood Avenue
Boston, MA 02115

BCH MRN: **500-20-94**
Patient Name: **ALDHAHERI, ABDULLA KHALIFA**
DOB/Age/Sex: 2/18/2014 3 years Male

Admit Date: 12/5/2016
Discharge Date: 12/5/2016

Patient Location: Neurology Foundation
Patient Type: Outpatient
Financial #: 6119856485

Ambulatory Documentation

DOCUMENT NAME:	Neurology Visit
SERVICE DATE/TIME:	12/5/2016 00:00 EST
PERFORM INFORMATION:	COULTER MD,DAVID L (12/5/2016 16:57 EST)
SIGN INFORMATION:	COULTER MD,DAVID L (12/20/2016 18:33 EST)
RESULT STATUS:	Auth (Verified)

DATE OF BIRTH: 02/18/2014

Dear Sir,

I saw Abdulla Aldhaheri back in follow-up on 12/05/2016. He is a 2-year-9-month-old boy with cerebral palsy whom I had seen previously on 09/22/2016. I reviewed his history at that time. Briefly, he was born at 25-1/2 weeks gestation as one of triplets and weighed about 800 grams at birth. He did have some complications and eventually developed hydrocephalus and required a shunt.

When I saw him in September, I was impressed that he was pretty social and interactive and clearly was wanting to communicate. I thought he had a fair amount of cognitive activity which was hard for him to express. Indeed, he was subsequently found to have a pretty dense hearing loss, which probably does account for some of his lack of speech. However, his social interaction was pretty significant. His mother again today confirmed that their observation is that Abdulla really does have a lot of social interaction and clearly has a strong intent to communicate.

When I had seen him in September, I noted he had increased tone in the right arm, but he was making an effort to at least use it. Today, his mother said that as a result of the occupational therapy, he is definitely using both hands much more than before and he is gaining more use of his right hand in particular.

I also had noted that he had increased tone in both legs and his ankles were pretty tight. He subsequently underwent Botox and phenol injections on 11/17/2016, which I think has helped. Today, his mother said that Abdulla is making good progress in physical therapy and is now able to walk with a walker.

He has been healthy otherwise and he does not take any medications. On the departmental review of systems today, his mother did not identify any additional concerns.

When I saw him in September, I requested an MRI scan of the brain to evaluate his hydrocephalus and shunt. I also requested an EEG to see if he was developing a seizure tendency.

The EEG was done on 10/24/2016. It did not show any evidence of seizure tendency. There were no epileptiform discharges. The recording was asymmetric in that sleep features were better formed over the right hemisphere, which certainly corresponds to his right hemiparesis and injury to the left hemisphere.

Indeed, the MRI scan which was done on 10/28/2016 showed that the left hemisphere was significantly more abnormal compared to the right. I reviewed those images with his mother today. One thing that is striking is that the cerebral cortex or the cortical ribbon is pretty intact especially over the right hemisphere. There is definitely some cortical injury in the left hemisphere, which could have an impact on his development of speech and language, but I suspect that the more intact right hemisphere is going to be able to compensate for that. I would caution that there is some abnormality in the right hemisphere,

Ambulatory Documentation

especially in the white matter, which may limit some of his ability to compensate however. The report did note that "the overall myelination pattern is normal apart from the areas of parenchymal injury" which would also indicate some potential for improvement.

The shunt was readily visualized and seems to terminate in the left lateral ventricle near the left thalamus. There was no suggestion of any increased intracranial pressure.

The MRI report did note some moderate mucosal thickening in the sinuses which I pointed out to his mother may have correlated with some congestion at the time.

MRI of the temporal bone was done at the same time and demonstrated pretty much normal auditory structures.

Indeed, his mother pointed out that there is a plan for Abdulla to have a cochlear implant in the very near future, and the intact auditory structures may provide some encouragement in that regard. I am sure he will get intensive speech therapy after that, which I think will also greatly improve his cognitive functioning.

On examination today, once again I did note the increased tone in his right arm, but I also noted him using it appropriately. He was pretty comfortable and was not in any pain, discomfort or distress. He certainly was quite alert and responsive and very much aware of his mother, but then he got hungry later during the visit, and he became a little bit more upset.

Thus, overall, Abdulla is a 2-year-9-month-old boy born very prematurely who has developed an asymmetric form of cerebral palsy as described above. However, I do think he has a great deal of potential for clinical improvement, which I think he is already demonstrating through therapy. Clearly, he will need intensive speech therapy to focus on his communication skills, which I understand is planned after he has the cochlear implant.

I am also pleased that the EEG did not show any sign of seizure activity, so I do not think we need to be concerned about that at this time.

I understand that he will be seeing Dr. Warf in the neurosurgery clinic in the near future to follow up on the hydrocephalus. I would like to see him back again in 3 months' time to review his overall developmental progress.

I appreciate very much the opportunity to see him today.

Sincerely,

David L Coulter, MD
Department of Neurology

CC:

International Office

300 Longwood Ave

Boston, MA 02115

ED Documentation (Text)

DOCUMENT NAME:	Emergency MD
SERVICE DATE/TIME:	6/6/2017 17:38 EDT
PERFORM INFORMATION:	LIN MD,MARGARET (6/6/2017 17:43 EDT)
SIGN INFORMATION:	PERRON MD,CATHERINE E (6/7/2017 09:41 EDT); LIN MD, MARGARET (6/6/2017 23:09 EDT)
RESULT STATUS:	Modified

Vomiting

Patient: **ALDHAHERI, ABDULLA KHALIFA** **MRN: 500-20-94** **FIN: 6121085593**
Age: **3 years** Sex: **Male** DOB: **2/18/2014**
Associated Diagnoses: **Acute vomiting**
Author: **LIN MD, MARGARET**

Basic Information
Time seen: Immediately upon arrival.
History source: Mother.
Arrival mode: Private vehicle.
History limitation: None.

History of Present Illness
The patient presents with vomiting. Complaint: 3yo male from UAE presenting with mom with vomiting since last night. Vomited once then settled and slept overnight. This morning seemed okay and mom sent him to school. Did not eat lunch at school and vomited several times. Abdulla did manage to eat some bread after returning home. Mom concerned re: potential for VP shunt blockage and increased ICP so now presenting to CHB. BG significant for prem at 25 weeks, intracranial hemorrhage, hydrocephalus, placement of VP shunt, spastic quad, LD, cochlear implant 2/17.

On arrival at CHB: smiling, at baseline, interactive. No fever or other abnormal VS. .

Review of Systems
Constitutional symptoms: denies fever, denies chills.
Skin symptoms: denies jaundice, denies abrasions, denies infection.
Eye symptoms: denies photophobia, denies blurred vision.
ENMT symptoms: denies sore throat, denies nasal congestion.
Respiratory symptoms: denies cough, denies wheezing.
Cardiovascular symptoms: denies chest pain.
Gastrointestinal symptoms: Vomiting, no diarrhea.
Genitourinary symptoms: no hematuria.
Neurologic symptoms: no seizure.
Allergy/immunologic symptoms: no food allergies.

Health Status
Allergies:
Allergic Reactions (All)

ED Documentation (Text)

No known allergies.

Medications: (Selected)

Prescriptions

Prescribed

Flovent HFA 110 mcg/inh inhalation aerosol: Dose Amount: 2 puff, INH, daily, Dispense Quantity: 1 EA, Refills: 1, Entered: 11/10/16 13:20:41 EST

Nebulizer machine: Nebulizer machine See Instructions, Special Instructions: Use as needed for albuterol delivery, Dispense Quantity: 1 kit, Entered: 09/29/16 11:30:10 EDT

Vitamin D3 400 intl units/mL oral liquid: Dose: 400 unit, Dose Amount: 1 mL, PO, daily, Dispense Quantity: 30 mL, Refills: 2, Entered: 01/31/17 14:56:54 EST

aerochamber with medium mask: aerochamber with medium mask See Instructions, Special Instructions: Use as directed for administration of Flovent, Dispense Quantity: 1 EA, Refills: 1, Entered: 11/10/16 13:20:48 EST

albuterol 1.25 mg/3 mL (0.042%) inhalation solution: Dose: 1.25 mg, INH, Q4hr, PRN Wheezing, Dispense Quantity: 90 mL, Refills: 2, Entered: 09/29/16 11:47:12 EDT.

Past Medical/ Family/ Social History

Medical history

Birth history: premature at 25 weeks, prematurity complications.

Surgical history: VP shunt, revision of same, cochlear implant.

Family history: Not significant.

Social history: Not significant.

Problem list:

All Problems

Bronchopulmonary dysplasia / SNOMED CT 112216013 / Confirmed
Added by QCC

Childhood asthma / SNOMED CT 350147016 / Confirmed
Added by QCC

Cochlear implant in situ / SNOMED CT 2912474015 / Confirmed

Developmental delay / SNOMED CT 370667011 / Confirmed

Dysarthria / SNOMED CT 14243015 / Confirmed

Feeding difficulties and mismanagement / SNOMED CT 410361018 / Confirmed

Hearing loss / SNOMED CT 25788011 / Confirmed

Mixed receptive-expressive language disorder / SNOMED CT 43176013 / Confirmed

Sensorineural hearing loss, bilateral / SNOMED CT 299259014 / Confirmed

Spastic quadriplegic cerebral palsy / SNOMED CT 3010116017 / Confirmed

Wheeze / SNOMED CT 93176012 / Confirmed
Added by QCC.

Physical Examination

Vital signs: Vital Signs

6/6/2017 16:51 EDT	Heart Rate	110 bpm
	Pulse Source	Automated
	Respiratory Rate	26 br/min
	Oxygen Saturation (SPO2)	96 %
	Oxygen Source	Room air
6/6/2017 16:29 EDT	Temperature	37.2 DegC

ED Documentation (Text)

	Systolic Blood Pressure	115 mmHg
	Temperature Route	Temporal artery
	Diastolic Blood Pressure	64 mmHg
	Heart Rate	**126 bpm HI**
	Pulse Source	Apical
	Respiratory Rate	24 br/min

, Measurements

6/6/2017 16:29 EDT	Weight	13.41 kg
	Weight for calculation	13.41 kg

, Oxygen saturation: Oxygen Saturation (SPO2)
6/6/2017 16:51 EDT Oxygen Saturation (SPO2) 96 % .

General: Smiling. interacting. playing.
Skin: Warm. dry.
Head: long, thin, conical shaped head.
Neck: Trachea midline
Eye: Pupils are equal, round and reactive to light. normal conjunctiva. no discharge.
Ears, nose, mouth and throat: Tympanic membranes clear. Oral mucosa moist.
Cardiovascular: Regular rate and rhythm. No murmur.
Respiratory: Lungs are clear to auscultation
Gastrointestinal: Soft. Nontender.
Genitourinary: Normal genitalia for age. no tenderness.
Back: Nontender. Normal range of motion.
Musculoskeletal: Moves all extremities
Neurological: Normal coordination observed. developmentally delayed. No new focal deficist, baseline right weakness.

Medical Decision Making

Differential Diagnosis: Vomiting.
Rationale Patient with VP shunt and vomiting. Interval improvement on car ride to CHB. Now smiling and interactive. Reassuring exam in the ED but considering hx will contact neurosurgery and obtain imaging. Initially cochlear implant thought to be MRI compatible. Radiology requesting CT scan instead as patient would require sedation, special positioning for MR.

FYI page sent to NeuroSurg to inform of change in imaging modality. .
Radiology results:
IMPRESSION:
Small caliber of the ventricular system with slight reduction in caliber of the shunted left lateral ventricle since December 2016. Therefore, there is no imaging evidence for shunt failure. To the contrary, the observed change could reflect over shunting or down-dialing of shunt valve setting. Advise clinical correlation.

No acute intracranial hemorrhage or fluid collection allowing for streak artifact from new cochlear implant (see below).

Extensive but stable sequela of prematurity, possibly with

ED Documentation (Text)

superimposed sequela of prior decompensated bouts of hydrocephalus.

Placement since December 2016 of a right cochlear implant. While this study is not tailored to evaluate the temporal bone, the cochlear implant and associated electrode appear appropriately positioned.

I, the teaching physician, have reviewed the images with the trainee and agree with the findings

Signature Line
***** Final Report*****

Dictated by: JAIMES COBOS MD, CAMILO E 06/06/2017 19:32

Verified by: YANG MD, PhD, EDWARD 06/06/2017 21:07

.

Reexamination/ Reevaluation

Re-examination/Re-evaluation: Time 06/06/2017 21:45:00, Vital signs Results included from flowsheet : Vital Signs 6/6/2017 20:53 EDT

Temperature	36.8 DegC
Systolic Blood Pressure	90 mmHg
Temperature Route	Temporal artery
Diastolic Blood Pressure	**40 mmHg LOW**
Heart Rate	86 bpm
Pulse Source	Automated
Respiratory Rate	24 br/min
Blood Pressure Method	Automated
Blood Pressure Location	Left lower
Vital Signs Posture	Supine
Oxygen Saturation (SPO2)	97 %
Oxygen Source	Room air
Vital Signs Information	sleeping

, Course Resolved, Pain status Resolved, Assessment Continues to look well. Reassuring vitals. Awaiting final word from neurosurgery regarding dispo. .

Update: 22:35 Neurosurgery reviewed patient and radiology. Happy for patient to be discharged home following extended observation in the ED. Patient continues to look well. No further vomiting. Awoke from nap. Mom and dad agree that he looks well. Tolerated PO fluids and solid foods. Plan for discharge home with strict return criteria delivered by neurosurgery.

Impression and Plan

ED Documentation (Text)

Acute vomiting (ICD10-CM R11.10, Discharge, Medical)
Plan
Condition: Improved.
Disposition: Discharged: to home.
Counseled: Patient, Family, Regarding diagnosis, Regarding diagnostic results, Regarding treatment plan, Regarding prescription, Patient indicated understanding of instructions.

Addendum

Teaching-Supervisory Addendum-Brief
Notes: SECOND YEAR TEACHING FELLOW NOTE:

Patient seen with above trainee in second year teaching role, supervised by Dr. Perron. Briefly, patient is Abdulla is a 3 yo M former 25 wk 6d M with hx of ICH and hydrocephalus s/p VP shunt (shunt revised x1, reprogrammed shunt in 2016), CP, spastic quadriplegia, r hemiplegia, deafness s/p cochlear implant, DD, here today with vomiting starting last night. Vomited x 1 times last night. Went to school today, had 2 episodes of vomiting at school. NBNB. Does not seem to be in pain. No fever. No recent illnesses. No diarrhea.

My exam showed: Gen: well appearing, no acute distress, alert and active, smiling; HEENT: PERRL, EOMI, normal conjunctiva, neck supple without LAN; Card: RRR, no murmur, good perfusion; Lungs: CTAB, good air entry, no increased WOB; Abd: soft, non-tender, non-distended, no masses; GU: normal testicular, no hernia Ext: warm and well perfused, moving all extremities; Skin: no rashes CNII-XII intact with exception of right facial droop which is baseline per mother.

3 yo old M with hx vp shunt here with vomiting. Well appearing here but given conern for possible ICP increase plan for nsurg consult and imaging. Had recent cochlear implants, will confirm MRI compatible. MRI states unable to do MR without kit from company and cannot perform in urgent manner, given this will obtain CT head.

CT head similar to baseline. Neurosurgery recommended discharge home. Patient continues to be well appearing here in the ED and tolerating POs.

Patient safe for discharge to home with supportive care and PCP follow up. Family in agreement with plan and verbalize understanding of signs and symptoms to return to care.

Margaret Lin, MD
Pediatric Emergency Medicine Fellow
ATTENDING NOTE: History adn exam directly by me in supervision fo resident and fellow. 3 yr old with VP shunt, dev delay here now with vomiting since yesteray. No fever.NO diarrhea. No apparent abd pain. On exam alert interacts nonverbal. Assyemticsmile(baseline) otherwise HEENt unremarkable.Neck supple. Chest clear. Cardiac regular. Abd soft. Testicles nontender, no hernias. Baseline hemiparesis. Differential gastro vs shunt malfunction.No indication of obstruction. Given cochlear implant CT performed adn noa cute ventricualr chnage. Neurosurgery feels no acute neurosurgical concerns. Observed at baseline drank no vomiting. Discharged/Perron, MD.

ED Documentation (Text)

DOCUMENT NAME:	Emergency MD
SERVICE DATE/TIME:	2/9/2017 18:06 EST
PERFORM INFORMATION:	ROBERTS MD,MARISA (2/9/2017 18:07 EST)
SIGN INFORMATION:	LEE MD,LOIS K (2/10/2017 08:41 EST); ROBERTS MD, MARISA (2/9/2017 20:33 EST)
RESULT STATUS:	Modified

Fall

Patient: **ALDHAHERI, ABDULLA KHALIFA** **MRN: 500-20-94** **FIN: 6120419546**
Age: **2 years** Sex: **Male** DOB: **2/18/2014**
Associated Diagnoses: **Cerebral palsy; Developmental delay; Sensorineural hearing loss; Head injury 959.01; Contusion of the face 920**
Author: **ROBERTS MD, MARISA**

Basic Information
Time seen: Immediately upon arrival.
History source: Mother.
Arrival mode: Private vehicle.
History limitation: None.

History of Present Illness
2 yo boy ex-25 week preemie with developmental delays, IVH, hydrocephalus s/p VP shunt, CP, and bilateral sensorineural hearing loss along with auditory neuropathy now POD 7 s/p right sided CI and mastoidectomy who presents s/p fall down 4 stairs. Mom states pt was near the top of the 4 stairs using walker when he slipping, falling forwards down the 4 stairs and onto the R side of his face. No LOC. Cried immediately after for about 1-2 minutes, then was consoled by mom. Per mom, maybe acting slightly sleepy mom more towards baseline now. No vomiting. No additional trauma, per mom pt not in pain at this time. Mom checked VP shunt which is on L side and states feels normal. + small abrasion on L side of face per mom but no additional injuries. No additional complaints at this time.

Review of Systems
Constitutional symptoms: Negative except as documented in HPI.
Skin symptoms: Negative except as documented in HPI.
Eye symptoms: Negative except as documented in HPI.
ENMT symptoms: Negative except as documented in HPI.
Respiratory symptoms: denies shortness of breath.
Cardiovascular symptoms: denies syncope.
Gastrointestinal symptoms: no vomiting.
Genitourinary symptoms: Negative except as documented in HPI.
Musculoskeletal symptoms: Negative except as documented in HPI.
Neurologic symptoms: Altered level of consciousness.

Health Status

ED Documentation (Text)

Allergies:
Allergic Reactions (Selected)
No known allergies.
Medications: (Selected)
Prescriptions
Prescribed
Flovent HFA 110 mcg/inh inhalation aerosol: Dose Amount: 2 puff, INH, daily, Dispense Quantity: 1 EA, Refills: 1, Entered: 11/10/16 13:20:41 EST
Nebulizer machine: Nebulizer machine See Instructions, Special Instructions: Use as needed for albuterol delivery, Dispense Quantity: 1 kit, Entered: 09/29/16 11:30:10 EDT
Vitamin D3 400 intl units/mL oral liquid: Dose: 400 unit, Dose Amount: 1 mL, PO, daily, Dispense Quantity: 30 mL, Refills: 2, Entered: 01/31/17 14:56:54 EST
acetaminophen 160 mg/5 mL oral liquid: Dose: 160 mg, Dose Amount: 5 mL, PO, Q4hr, PRN Fever/Pain, Take for 10 day, Dispense Quantity: 300 mL, Entered: 02/03/17 10:07:11 EST, Stop: 02/13/17 10:07:11 EST
aerochamber with medium mask: aerochamber with medium mask See Instructions, Special Instructions: Use as directed for administration of Flovent, Dispense Quantity: 1 EA, Refills: 1, Entered: 11/10/16 13:20:48 EST
albuterol 1.25 mg/3 mL (0.042%) inhalation solution: Dose: 1.25 mg, INH, Q4hr, PRN Wheezing, Dispense Quantity: 90 mL, Refills: 2, Entered: 09/29/16 11:47:12 EDT
cephalexin 250 mg/5 mL oral liquid: Dose: 300 mg, Dose Amount: 6 mL, PO, BID, Take for 7 day, Dispense Quantity: 84 mL, Entered: 02/03/17 10:06:12 EST, Stop: 02/10/17 10:06:12 EST.
Immunizations: Up to date.

Past Medical/ Family/ Social History
Surgical history: Ventriculoperitoneal shunt.
Social history: lives with family.
Problem list:
All Problems
Bronchopulmonary dysplasia / SNOMED CT 112216013 / Confirmed
Added by QCC
Childhood asthma / SNOMED CT 350147016 / Confirmed
Added by QCC
Developmental delay / SNOMED CT 370667011 / Confirmed
Feeding difficulties and mismanagement / SNOMED CT 410361018 / Confirmed
Hearing loss / SNOMED CT 25788011 / Confirmed
Sensorineural hearing loss, bilateral / SNOMED CT 299259014 / Confirmed
Spastic quadriplegic cerebral palsy / SNOMED CT 3010116017 / Confirmed
Speech delay / SNOMED CT 344354016 / Confirmed
Wheeze / SNOMED CT 93176012 / Confirmed
Added by QCC.

Physical Examination
Vital signs: Vital Signs

2/9/2017 17:48 EST	Temperature	36.7 DegC
	Systolic Blood Pressure	100 mmHg
	Temperature Route	Temporal artery
	Diastolic Blood Pressure	64 mmHg
	Heart Rate	88 bpm

ED Documentation (Text)

	Pulse Source	Apical
	Respiratory Rate	22 br/min
	Blood Pressure Method	Automated
	Blood Pressure Location	LUE
	Vital Signs Posture	Sitting
	Oxygen Saturation (SPO2)	98 %
	Oxygen Source	Room air

, Measurements

2/9/2017 17:48 EST	Weight	13.640 kg
	Weight for calculation	13.64 kg

, Oxygen saturation: Oxygen Saturation (SPO2)
2/9/2017 17:48 EST Oxygen Saturation (SPO2) 98 % .

General: Appropriate for age. smiling.
Skin: Warm. dry. pink. small abrasion under R eye.
Eye: Pupils are equal, round and reactive to light. extraocular movements are intact.
Ears, nose, mouth and throat: Oral mucosa moist. No pharyngeal erythema or exudate. L Tm clear, R TM with some erythema and post-op changes near TM.
Neck: Supple
Cardiovascular: Regular rate and rhythm. Normal peripheral perfusion. Extremity pulses equal.
Respiratory: Lungs are clear to auscultation. respirations are non-labored.
Chest wall: No tenderness. No deformity.
Back: Nontender. Normal range of motion. no step-offs.
Musculoskeletal: Normal ROM. no tenderness. no swelling. no deformity.
Gastrointestinal: Soft. Non distended.
Neurological: No focal neurological deficit observed. less tone on L side.
Lymphatics: No lymphadenopathy
Psychiatric: Appropriate mood & affect

Medical Decision Making
2 yo M s/p fall with minor head trauma. No LOC, no major mechanism, no significant vomiting, no significant changes in level of consciousness. Will t/b with ENT given recent surgery. Will observe for 4 hrs after injury.

Reexamination/ Reevaluation
Pt doing well upon re-eval. Tolerating PO. Spoke w/ ENT, aware pt in ED. Will d/c with return precautions for f/u.
Re-examination/Re-evaluation: Vital signs Results included from flowsheet : Vital Signs

2/9/2017 20:20 EST	Temperature	37.7 DegC
	Systolic Blood Pressure	92 mmHg
	Diastolic Blood Pressure	74 mmHg
	Heart Rate	**126 bpm HI**
	Respiratory Rate	28 br/min
	Oxygen Saturation (SPO2)	98 %

.

Impression and Plan

ED Documentation (Text)

Diagnosis

Head injury 959.01 (ICD10-CM S09.90XA, Discharge, Emergency medicine, Medical)
Contusion of the face 920 (ICD10-CM S00.83XA, Discharge, Emergency medicine, Medical)
Cerebral palsy (ICD10-CM G80.9, Discharge, Emergency medicine, Medical)
Developmental delay (ICD10-CM R62.50, Discharge, Emergency medicine, Medical)
Sensorineural hearing loss (ICD10-CM H90.5, Discharge, Emergency medicine, Medical)

Plan

Condition: Stable.

Disposition: Discharged: to home.

Addendum

Teaching-Supervisory Addendum-Brief

I participated in the following activities of this patients care: the medical history, the physical exam, medical decision making.
I personally performed: supervision of the patient's care, the medical history, the physical exam.
The case was discussed with: the resident.
Evaluation and management service: I agree with the evaluation and management decisions made in this patient's care.
Results interpretation: I agree with the study interpretation in this patient's care.

Notes:

SECOND YEAR TEACHING FELLOW NOTE:
Patient seen with above trainee in second year teaching role, supervised by Dr. Lee. Briefly, patient is 2yo ex-25 week infant with history of hydrocephalus s/p VP shunt, also s/p recent R cochlear implant, presenting after fall forward down 4 stairs. No LOC, no vomiting, currently acting his normal self.

My exam showed: Gen: well appearing, no acute distress, alert; HEENT: PERRL, EOMI, macrocephalic, normal conjunctiva, neck supple without LAN, VP shunt palpable over L neck, superficial abrasion over R periorbital area; Card: RRR, no murmur, good perfusion; Lungs: CTAB, good air entry, no increased WOB; Abd: soft, non-tender, non-distended; Ext: warm and well perfused, low tone as epr baseline; Skin: superficial abrasion lateral to R eye, well-healing incision posterior to R ear

Injury mechanism and exam reassuring against ciTBI, atlhough unable to apply PECARN criteria given underlying medical issues. Therefore observed x3-4 hours, continued to be at baseline mental status without vomiting. Tolerated PO intake. Patient safe for discharge to home with supportive care and PCP follow up as needed. Family in agreement with plan and verbalize understanding of signs and symptoms to return to care.

Amanda Stewart MD, MPH
Pediatric Emergency Medicine Fellow p8149, I have seen and examined the patient and supervised the care of the patient as the attending physician responsible for this patient. Lois Lee, MD, MPH., I have reviewed the note above and obtained further history by interview and examined the patient.2 yo ex 25 wk gest male, h/o developmental delay and spastic quadriplegia, s/p VPS for hydrocephalus from IVH, s/p right cochlear implant/mastoidectomy POD 10 presents after falling down 4 stairs and landing on the right side of his face. No h/o LOC or emesis. Was walking with his walker down the stairs. patient was sleepy afterwards, but mother didn't allow patient to fall asleep. patient now back to baseline. My examination revealed the patient to be active, alert, and in no distress. Vital signs as noted above. Hemodynamically stable. The HEENT exam with + mild edema over right upper eyelid and eyebrow and lateral right orbital area with petechiae and erythema, EOMI, pearly TMs, right scalp incision healing well w/o erythema or drainage, MMM, and the neck was supple. Auscultation revealed clear lungs and regular rate and rhythm. The abdomen was nondistended, NABS, soft, non tender throughout. I observed no focal neurological deficits. No focal MSK tenderness or deformity. Patient with minor head trauma. Will observe for 4 hours after after head injury for any signs/symptoms of intracranial hemorrhage. Patient

ED Documentation (Text)

observed and continued to be at baseline. Tolerated po w/o emesis. Discharge instructions discussed with the family; written instructions given and follow-up specifically advised within 24-48 hours as directed or with worsening symptoms..

ED Documentation (Text)

DOCUMENT NAME:	Emergency MD
SERVICE DATE/TIME:	11/14/2016 18:49 EST
PERFORM INFORMATION:	FARRELL MD,CAITLIN A (11/14/2016 18:49 EST)
SIGN INFORMATION:	FARRELL MD,CAITLIN A (11/15/2016 14:20 EST)
RESULT STATUS:	Auth (Verified)

Fever

Patient: **ALDHAHERI, ABDULLA KHALIFA** **MRN: 500-20-94** **FIN: 6119941933**
Age: **2 years** Sex: **Male** DOB: **2/18/2014**
Associated Diagnoses: **Fever 780.60**
Author: **FARRELL MD, CAITLIN A**

Basic Information

Time seen: Date & time 11/14/2016 18:49:00.

History of Present Illness

2yo ex-25wk M w/ hx IVH, hydrocephalus, VPS (last revised in Feb 2016), here w/ concern for fever.

Mother reports for last 3d. She became concerned because Pt appears weak when he's febrile, not wanting to crawl around normally. She also is concerned about ear infection as Pt will intermittently suddenly cry out.

No vomiting. Normal cry. Reaches normally. No rash. No cough.

Tolerating POs without issue. No history of aspiration.

Has been in US for the last 2mo for evaluation for cochlear implant.

Shunt revision in Feb, presenting with intermittent lethargy that became more prolonged.

Review of Systems

Constitutional symptoms: Fever.
Skin symptoms: denies rash.
Eye symptoms: Negative except as documented in HPI.
ENMT symptoms: Nasal congestion.
Respiratory symptoms: Cough, denies wheezing.
Cardiovascular symptoms: Negative except as documented in HPI.
Gastrointestinal symptoms: no vomiting, no diarrhea.
Genitourinary symptoms: Negative except as documented in HPI.
Musculoskeletal symptoms: Negative except as documented in HPI.
Neurologic symptoms: Negative except as documented in HPI.
Additional review of systems information: 10 systems reviewed and negative except as noted above..

Health Status

Allergies:

Allergic Reactions (All)

ED Documentation (Text)

No known allergies.
Medications: None.
Immunizations: Up to date.

Past Medical/ Family/ Social History

Medical history
ex-25wk, BPD, ROP, IVH, hydrocephalus, developmental delay.
Surgical history: Ventriculoperitoneal shunt.
Family history: reviewed and not contributory to the patient's condition.
Social history: Family/social situation: Lives with parent(s).

Physical Examination
Vital signs: Vital Signs

11/14/2016 18:46 EST	Temperature	37.2 DegC
	Systolic Blood Pressure	94 mmHg
	Temperature Route	Temporal artery
	Diastolic Blood Pressure	52 mmHg
	Heart Rate	112 bpm
	Pulse Source	Apical
	Respiratory Rate	28 br/min
	Blood Pressure Method	Automated
	Blood Pressure Location	RUE
	Vital Signs Posture	Supine
	Oxygen Saturation (SPO2)	99 %
	Oxygen Source	Room air

.
General: Appropriate for age. cooperative. smiling. interacting.
Skin: Warm. dry. pink.
Head: Normocephalic. atraumatic.
Neck: Supple
Eye: Pupils are equal, round and reactive to light. extraocular movements are intact.
Ears, nose, mouth and throat: Tympanic membranes clear. Oral mucosa moist. No pharyngeal erythema or exudate.
Cardiovascular: Regular rate and rhythm. No murmur. Normal peripheral perfusion.
Respiratory: Lungs are clear to auscultation. respirations are non-labored. breath sounds are equal.
Gastrointestinal: Soft. Nontender. Non distended.
Musculoskeletal: Moves all extremities
Neurological: No focal neurological deficit observed. symmetric facies, symmetric grimmace, reaches smoothly with symmetric strength.
Psychiatric: Cooperative

Medical Decision Making
2yo M w/ complex history as outlined above, here w/ fever.
Exam reassuring wtih clear TMs. CXR without focal infiltrate. Neuro exam reassuring. Mother agrees, Pt is back to baseline activity and interactiveness when fever is done.

ED Documentation (Text)

Neurosurgery consulted and agrees, history and exam not worrisome for shunt malfunction or infection.
Suspect viral illness, discussed supportive care with parents.
Plan for PMD follow-up as needed, will see Dr. Wharf in NSG clinic next week.

Impression and Plan

Diagnosis

Fever 780.60 (ICD10-CM R50.9, Discharge, Medical)

Extreme prematurity, cerebral palsy, intraventricular hemorrhage, VP shunt

Calls-Consults

- Neurosurgery.

Plan

Condition: Improved.
Disposition: Discharged: to home.
Patient was given the following educational materials: Shunt Malfunction Signs and Symptoms BCH (CUSTOM).
Follow up with: Primary Care Physician, In: as needed.
Counseled: Family.

Boston Children's Hospital
300 Longwood Avenue
Boston, MA 02115

BCH MRN: **500-20-94**
Patient Name: **ALDHAHERI, ABDULLA KHALIFA**
DOB/Age/Sex: 2/18/2014 3 years Male

Admit Date: 1/10/2017
Discharge Date: 1/10/2017

Patient Location: Speech Pathology Longwood
Patient Type: Outpatient
Financial #: 6120025918

Radiology

ACCESSION	EXAM DATE/TIME	PROCEDURE	ORDERING PROVIDER STATUS
RA-17-0005180	1/10/2017 14:48 EST	FL-Barium Swallow Modified	MARTIN MD,THOMAS RModified II

CDM code
2267000037
F74230

Reason For Exam
(FL-Barium Swallow Modified) Dysmorphic ex-premie with hypotonia and BPD, ongoing cough, congestion

Report

.

MODIFIED SWALLOW STUDY

CLINICAL HISTORY: This is a 34-month-old baby boy former 25 week premature triplet presenting with hypotonia, cough, and congestion.

COMPARISON: No prior modified swallow study for comparison.

TECHNIQUE: A swallow study was performed in conjunction with the Speech Pathology Team. The patient was given different consistencies of food or drink containing barium, and swallowing was observed under video fluoroscopy.

FINDINGS:
There was no delay initiation of swallowing.

With thin liquid consistency via cup, there was no laryngeal penetration or aspiration.
With puree consistency via cup, there was no laryngeal penetration or aspiration.
With yogurt consistency via spoon, there was no laryngeal penetration or aspiration.

IMPRESSION:
No evidence of laryngeal penetration or aspiration with thin liquid, puree, and yogurt consistency.

Full report by Speech Pathology to follow. Outpatient reports are found under Documents>Clinics>Communication Enhancement. Inpatient

Radiology

ACCESSION	EXAM DATE/TIME	PROCEDURE	ORDERING PROVIDER STATUS
RA-17-0005180	1/10/2017 14:48 EST	FL-Barium Swallow Modified	MARTIN MD,THOMAS RModified II

Report
reports are found under Documents>Consultations>Feeding Team.

Fluoroscopy time in minutes = 0.40 Estimated dose in mGy = 0.40
Fluoroscopist = Fellow HRK

I, the teaching physician, have reviewed the images with the trainee and agree with the findings

***** *Final Report*****

Dictated by: KIM MD, HELEN H 01/10/2017 15:21

Verified by: BIXBY MD, SARAH D 01/10/2017 16:24

Discharge Documentation

DOCUMENT NAME:	Discharge Summary
SERVICE DATE/TIME:	9/11/2017 14:53 EDT
PERFORM INFORMATION:	KLEIN FNP,JENNIFER M (8/19/2017 15:16 EDT)
SIGN INFORMATION:	WARF MD,BENJAMIN C (9/12/2017 19:31 EDT); KLEIN FNP, JENNIFER M (9/11/2017 15:41 EDT); KLEIN FNP,JENNIFER M (9/11/2017 12:54 EDT)
RESULT STATUS:	Auth (Verified)

Discharge Summary.

Patient: **ALDHAHERI, ABDULLA KHALIFA** **MRN: 500-20-94** **FIN: 6121467356**
Age: **3 years** Sex: **Male** DOB: **2/18/2014**
Associated Diagnoses: **Ventriculoperitoneal shunt malfunction; Seizure; Ventriculoperitoneal shunt malfunction**
Author: **KLEIN FNP, JENNIFER M**

Discharge Information

Discharge Summary Information: Admitted 8/15/17, Discharged 9/11/17.

Attending Physician: WARF MD, BENJAMIN C.
Consulting Provider: Clinical Service (Neurosurgery).
Problems: ADD NEW PROBLEMS
All Problems
Acute vomiting / SNOMED CT 40246014 / Confirmed
Bronchopulmonary dysplasia / SNOMED CT 112216013 / Confirmed
Added by QCC
Childhood asthma / SNOMED CT 350147016 / Confirmed
Added by QCC
Cochlear implant in situ / SNOMED CT 2912474015 / Confirmed
Developmental delay / SNOMED CT 370667011 / Confirmed
Dysarthria / SNOMED CT 14243015 / Confirmed
Feeding difficulties and mismanagement / SNOMED CT 410361018 / Confirmed
Hearing loss / SNOMED CT 25788011 / Confirmed
Mixed receptive-expressive language disorder / SNOMED CT 43176013 / Confirmed
Sensorineural hearing loss, bilateral / SNOMED CT 299259014 / Confirmed
Spastic quadriplegic cerebral palsy / SNOMED CT 3010116017 / Confirmed
Wheeze / SNOMED CT 93176012 / Confirmed
Added by QCC.
Admitting diagnosis: Ventriculoperitoneal shunt malfunction - Discharge, Seizure - Admitting.
Discharge diagnosis: Ventriculoperitoneal shunt malfunction - Discharge.

Hospital Course

Hospital Course

Admitted from: from emergency department.
Were there any major tests or procedures done during this admission?: ADD RESULT OF MAJOR TESTS OR PROCEDURES

Discharge Documentation

PROCEDURES PERFORMED 8/15/17:
1. Shunt tap in Emergency Department.
2. Left frontal external ventricular drain placement with stereotactic guidance in the operating room.

PROCEDURES PERFORMED 8/17/17: Removal of entire ventriculoperitoneal shunt.

PROCEDURES 8/24/17: BUR hole for endoscopic third ventriculostomy, placement of external ventricular drain, use of the stereotactic computer-assisted image guidance navigation.

PROCEDURES PERFORMED 9/7/17: Left burr hole for ventriculoperitoneal shunt placement, use of stereotactic computer-assisted image guidance navigation.

.

OTHER: Abdulla is a 3 yo M ex 25-weeker, grade IV IVH of prematurity with subsequent shunted hydrocephalus at 3 months of age, hx of shunt malfunction at 2 yo of age with one prior revision who presented to ED with fever, altered mental status, and concern for first time seizure. He was intubated for airway protection in the ED. A head CT was obtained w/o significant changes compared to a prior baseline CT scan about two months ago (6/6/2017). A shunt tap was performed urgently with no CSF flow. Concerns for possible new proximal shunt malfunction. Pt was taken urgently to the OR for L sided EVD placement (8/15). Overnight pt. had respiratory culture return with abundant polys, CXR concerning for developing PNA, and CSF culture that grew GNR's concerning for shunt/CNS infection. Pt. went to OR (8/17) for VP shunt removal, EVD left in place. Remained externalized until 9/7/17 at which time pt taken to OR with Neurosurgery for reinternalization of VP shunt

NEURO: Neurology and Neurosurgery consults and following while in the MSICU. Bedside EEG completed without evidence of seizure activity. Remained on Keppra for seizure prophylaxis. Taken to OR for emergent EVD placement on 8/15. CSF cultures positive ****. Due to concern for CNS infection pt taken back to OR on 8/17 for removal of shunt hardware. EVD remained in place with daily CSF cultures. Once CSF cultures negative on *** pt was taken beck to OR for VP shunt placement. Neuroprotective measures, including HOB 30, normal Na, goal pCO2 40 maintained.

SED/PAIN:
-Morphine & Midazolam infusions initiated after intubation and discontinued during extubation phase on 8/18. Received Tylenol PRN fever/pain.

CV: Remained hemodynamically stable.

RESP: Intubated for airway safety and extubated to CPAP on 8/18. Required Decadron and Lasix pre and post extubation. Began sprinting off CPAP on 8/18 and able to sprint off to room air completely on 8/20. Pulmonary toilet PRN

FEN/GI: NPO on MIVF with sump in place. Post extubation sump removed and NJT placed for enteral feeds. Feeds

Discharge Documentation

initiated on 8/19. Remained on GI prophylaxis until tolerating full feeds. Foley placed at time of intubation and since discontinued and voiding in diaper. Placed on bowel regime while in MSICU.

ID: Initially on Ancef while EVD is in place. Antibiotics broadened to meningitic dosing of CTX and Vancomycin with concern for CNS infection. Ceftriaxone discontinued. Currently on Vancomycin. CSF cx sent to State lab.

Neurosurgery FLOOR course

Pt was transferred to the floor on 8/21/17

NEURO: EVD level was slowly increased to help plump her ventricles, she tolerated this well. On 8/22/17 a head CT was obtained that demonstrated intervak enlargment of ventricles. Remained on Keppra for seizure prophylaxis. On Tylenol PRN fever/pain. Taken to the OR on 8/24 for an ETV, removal of old EVD and placement of a new EVD by Dr Warf; tolerated well with no complications, evd weaned and clamped, Abdulla didnt tolerate clamp trial and he returned to the OR on 9/7 for placement of shunt.

CV: Remained hemodynamically stable.

RESP: On room air. Pulmonary toilet PRN

FEN/GI: Continued on Tube feeds, patient had multiple episodes of emesis requiring holding off his tube feeds, He was eventually able to tolerate his feeds without any difficulties. He remained neurologically and hemodynamically stable. Remained on GI prophylaxis until tolerating full feeds. Voiding spontanoeusly with multiple diaper and a regular BM

ID: Continue on Vancomycin per ID recommendations until pod #4 and discontinued on 9/11/17. CSF cx sent to State lab.

Dispo: Abdulla was medically cleared for discharge on 9/11/17 with plans to return to clinic in 2 weeks with MRVC and suture removal.

.

Results Review

General Results

Were there any pending labs and diagnostic tests at the time of discharge?

Yes

Pending Labs (Selected)

Inpatient Orders

InProcess (Preliminary)

CSF Culture and Gram Stain: Cerebrospinal Fluid, recd plated, Stat, Requested on 09/07/17 23:17:00 EDT, Stop 09/07/17 23:45:16 EDT

Discharge Plan

Discharge Summary Plan

Discharge Status: stable.

Discharge Documentation

Discharge instructions given: to caregiver, written discharge instructions **Neurosurgery discharge instructions for:**

Hydrocephalus – Shunt

Please call the Neurosurgery office at 617-355-6008 with any questions or concerns.
After hours please call the 617-355-6363 and page the neurosurgery resident on call.
Incision Care

Keep the incision(s) dry for 1 week post-operatively. You may then rinse the incision(s) with clean running water, but do not soak the wound(s) for 2 weeks post-operatively. If present, you may remove the dressing 1 week after surgery. It may fall off before then.
In some cases your surgeon may have used something called Dermabond on the incision. Dermabond is a Topical Skin Adhesive that holds wound edges together. The film will usually remain in place for 5 to 10 days, and then naturally fall off your skin. Be sure not to pick the dermabond and to let it fall off on its own.
Check the surgical site(s) (including on the head, anywhere over the shunt hardware, down the shunt tubing) for leakage/drainage, breakdown, worsening pain, redness, or swelling. Please call if you see any of these concerns.
There will be a hard bump on the scalp where the shunt is located, and this is normal.

Shunt Instructions

- ð **Your shunt is programmable, and is set at _____.**
- ð **Your shunt is programmable, and the setting must be checked before and after MRI scans.**
- ð **Your shunt is non-programmable, with a fixed _____ pressure setting.**

Suture Instructions

- ð **The sutures (stitches) are not dissolvable and will need to be removed _____9/25___.**

Activity

Gradually increase activity as tolerated. Return to school or similar activities can generally be in 1-2 weeks. Avoid contact sports or gym class for 3 months. To help increase neck range of motion, slowly move your neck from side to side.
For infants/toddlers, normal activity is ok after surgery.
Diet
It is ok to resume usual diet.
Medications
Pain medications should be taken only as needed, and lowered to eventually be stopped over the course of days to roughly a week. Stool softeners should be used with pain medications to prevent constipation or straining.
When to contact us
Please also call for a fever > 101 F (38 C), or if you see any neurologic changes such as new or worsening headache, pain, weakness, numbness, difficulty speaking or understanding, changes in vision, problems swallowing, loss of control of bladder or bowel (such as accidents), persistent vomiting, unusual irritability or

Discharge Documentation

sleepiness, new or unusual seizure activity, full or bulging fontanels (for infants), or any other symptom(s) that concern you.

Follow-up

You will see your surgeon for a follow-up appointment in approximately 2 weeks.

f/u with neurology as an outpatient.

.

Discharge disposition: home.
Discharge Diet: Age appropriate as tolerated.
Orders: Medication List (Selected)

Prescriptions

Prescribed

Diastat AcuDial 10 mg rectal kit: Dose: 10 mg, PR, As Directed, PRN seizure longer than 5 min, Dispense Quantity: 1 kit, Refills: 2, Entered: 09/11/17 11:22:20 EDT

Flovent HFA 110 mcg/inh inhalation aerosol: Dose Amount: 2 puff, INH, daily, Dispense Quantity: 1 EA, Refills: 1, Entered: 11/10/16 13:20:41 EST

Keppra 100 mg/mL oral solution: Dose: 200 mg, Dose Amount: 2 mL, GTUBE, BID, Dispense Quantity: 240 mL, Refills: 2, Entered: 09/11/17 11:20:11 EDT

Nebulizer machine: Nebulizer machine See Instructions, Special Instructions: Use as needed for albuterol delivery, Dispense Quantity: 1 kit, Entered: 09/29/16 11:30:10 EDT

Vitamin D3 400 intl units/mL oral liquid: Dose: 400 unit, Dose Amount: 1 mL, PO, daily, Dispense Quantity: 30 mL, Refills: 2, Entered: 01/31/17 14:56:54 EST

aerochamber with medium mask: aerochamber with medium mask See Instructions, Special Instructions: Use as directed for administration of Flovent, Dispense Quantity: 1 EA, Refills: 1, Entered: 11/10/16 13:20:48 EST

albuterol 1.25 mg/3 mL (0.042%) inhalation solution: Dose: 1.25 mg, INH, Q4hr, PRN Wheezing, Dispense Quantity: 90 mL, Refills: 2, Entered: 09/29/16 11:47:12 EDT

Documented Medications

Documented

acetaminophen: Dose: 160 mg, Dose Amount: 5 mL, PO, Q4hr, PRN Fever/Pain, Entered: 09/11/17 8:51:59 EDT

.

Course

Progressing as expected.

Discharge Planning

Scheduled Appointments: Scheduled Appointments
Scheduled Appointment

Scheduled Appointment 1 Date/Time: 09/11/17 16:00
Scheduled Appointment 1 Resource: AUDIOLOGY/WALTHAM (Dept)

Scheduled Appointment 2 Date/Time: 09/25/17 16:00
Scheduled Appointment 2 Resource: NEUROSURGERY/FOUND (Dept)

.

Boston Children's Hospital
300 Longwood Avenue
Boston, MA 02115

BCH MRN: **500-20-94**
Patient Name: **ALDHAHERI, ABDULLA KHALIFA**
DOB/Age/Sex: 2/18/2014 3 years Male

Admit Date: 2/2/2017
Discharge Date: 2/3/2017

Patient Location: 10 NorthWest 1001 A
Patient Type: Observation
Financial #: 6120300773

Discharge Documentation

DOCUMENT NAME:	Discharge Summary
SERVICE DATE/TIME:	2/3/2017 12:13 EST
PERFORM INFORMATION:	LICAMELI MD,GREG R (2/3/2017 22:37 EST)
SIGN INFORMATION:	LICAMELI MD,GREG R (2/3/2017 22:37 EST); BENO PA, LARA L (2/3/2017 12:13 EST)
RESULT STATUS:	Auth (Verified)

Discharge Summary.

Patient: **ALDHAHERI, ABDULLA KHALIFA** **MRN: 500-20-94** **FIN: 6120300773**
Age: **2 years** Sex: **Male** DOB: **2/18/2014**
Associated Diagnoses: **Sensory-neural hearing loss**
Author: **BENO PA, LARA L**

Discharge Information
Discharge Summary Information: Admitted 2/2/17, Discharged 2/3/17.
Attending Physician: LICAMELI MD, GREG R.
Admitting diagnosis: Sensory-neural hearing loss - Admitting.
Discharge diagnosis: Sensory-neural hearing loss - Discharge.

Hospital Course
Hospital Course
Were there any major tests or procedures done during this admission?: ADD RESULT OF MAJOR TESTS OR PROCEDURES

PRE-OPERATIVE DIAGNOSIS: Bilateral sensorineural hearing loss.

POST-OPERATIVE DIAGNOSIS: Bilateral sensorineural hearing loss.

PROCEDURES PERFORMED: Right Cochlear implantation with mastoidectomy. Facial nerve monitoring x4hrs. .
OTHER: AVSS, stable overnight, no events
Tolerating PO without n/v at time of discharge, pain controlled
Pt was discharged home in stable condition, parents given opportunity to ask any questions and verbalized understanding of discharge instructions..

Results Review
General Results
Were there any pending labs and diagnostic tests at the time of discharge?
No

Physical Examination

Discharge Documentation

AVSS
comfortable
no bleeding from operative site
no stridor, breathing non labored
dressing removed, incision flat, c/d/i

Discharge Plan

Discharge Summary Plan

Discharge Status: stable.
Discharge instructions given: written discharge instructions no baths or swimming
may get area wet but do not soak or scrub
apply bacitracin ointment to incision daily until healed
pat area dry
to keep water out of the ear canal, use a cotton ball covered in Vaseline in the ear canal

monitor for any signs of significant swelling, fevers and/or drainage from the incision site, Discharge instructions were provided to the patient and/or caregiver via the discharge plan.
Discharge disposition: home.
Discharge Diet: Age appropriate as tolerated.
Orders: Medication List (Selected)

Prescriptions

Prescribed

AFO Socks: AFO Socks Special Instructions: Socks for use with AFO braces, please provide 6 pairs Dispense Quantity: 6 EA Stop: 02/08/17 11:32:00 EST See Instructions
Flovent HFA 110 mcg/inh inhalation aerosol: Dose Amount: 2 puff, INH, daily, Dispense Quantity: 1 EA, Refills: 1, Entered: 11/10/16 13:20:41 EST
Nebulizer machine: Nebulizer machine See Instructions, Special Instructions: Use as needed for albuterol delivery, Dispense Quantity: 1 kit, Entered: 09/29/16 11:30:10 EDT
Vitamin D3 400 intl units/mL oral liquid: Dose: 400 unit, Dose Amount: 1 mL, PO, daily, Dispense Quantity: 30 mL, Refills: 2, Entered: 01/31/17 14:56:54 EST
acetaminophen 160 mg/5 mL oral liquid: Dose: 160 mg, Dose Amount: 5 mL, PO, Q4hr, PRN Fever/Pain, Take for 10 day, Dispense Quantity: 300 mL, Entered: 02/03/17 10:07:11 EST, Stop: 02/13/17 10:07:11 EST
aerochamber with medium mask: aerochamber with medium mask See Instructions, Special Instructions: Use as directed for administration of Flovent, Dispense Quantity: 1 EA, Refills: 1, Entered: 11/10/16 13:20:48 EST
albuterol 1.25 mg/3 mL (0.042%) inhalation solution: Dose: 1.25 mg, INH, Q4hr, PRN Wheezing, Dispense Quantity: 90 mL, Refills: 2, Entered: 09/29/16 11:47:12 EDT
cephalexin 250 mg/5 mL oral liquid: Dose: 300 mg, Dose Amount: 6 mL, PO, BID, Take for 7 day, Dispense Quantity: 84 mL, Entered: 02/03/17 10:06:12 EST, Stop: 02/10/17 10:06:12 EST.

Discharge Planning

Scheduled Appointments: Scheduled Appointments
Scheduled Appointment

Scheduled Appointment 1 Date/Time: 02/07/17 08:30
Scheduled Appointment 1 Resource: SPEECH PATHOLOGY WLTHM (Dept)

Scheduled Appointment 2 Date/Time: 02/09/17 11:30

Discharge Documentation

Scheduled Appointment 2 Resource: PHYSICAL THERAPY (Dept)

Scheduled Appointment 3 Date/Time: 02/09/17 13:00
Scheduled Appointment 3 Resource: OCCUPATIONAL THERAPY (Dept)

Scheduled Appointment 4 Date/Time: 02/16/17 11:30
Scheduled Appointment 4 Resource: PHYSICAL THERAPY (Dept)

Scheduled Appointment 5 Date/Time: 02/23/17 09:30
Scheduled Appointment 5 Resource: PHYSICAL THERAPY (Dept)

Scheduled Appointment 6 Date/Time: 02/24/17 09:30
Scheduled Appointment 6 Resource: OCCUPATIONAL THERAPY (Dept)

Scheduled Appointment 7 Date/Time: 03/01/17 10:30
Scheduled Appointment 7 Resource: OCCUPATIONAL THERAPY (Dept)

Scheduled Appointment 8 Date/Time: 03/01/17 14:00
Scheduled Appointment 8 Resource: OPHTHALMOLOGY/WALTHAM (Dept)

Scheduled Appointment 9 Date/Time: 03/03/17 11:30
Scheduled Appointment 9 Resource: CEREBRAL PALSY (Dept)

Scheduled Appointment 10 Date/Time: 03/13/17 09:30
Scheduled Appointment 10 Resource: COMPLEX CARE SERVICE (Dept)

Scheduled Appointment 11 Date/Time: 03/13/17 15:00
Scheduled Appointment 11 Resource: NEUROLOGY FOUNDATION (Dept)

Scheduled Appointment 12 Date/Time: 05/18/17 10:00
Scheduled Appointment 12 Resource: ACP/WALTHAM (Dept)

Scheduled Appointment 13 Date/Time: 05/18/17 10:00
Scheduled Appointment 13 Resource: ACP/WALTHAM (Dept)

.

EEG Report

ACCESSION:	EG-17-0003521	COLLECTED DATE/TIME:	8/15/2017 09:27 EDT
RESPONSIBLE PATHOLOGIST:	ROTENBERG MD, ALEXANDER	RECEIVED DATE/TIME:	8/15/2017 09:27 EDT
ORDERING PHYSICIAN	TROWBRIDGE MD,SARA		

EEG Report – 8/24/2017 12:29 EDT – Auth (Verified)

CHILDREN'S HOSPITAL BOSTON
Division of Epilepsy and Clinical Neurophysiology
300 Longwood Ave
Boston, MA 02115 USA
phone 617-355-7970 fax 617-730-0463
www.childrenshospital.org

AUDIOVISUAL BEDSIDE MONITORING REPORT

This procedure was requested by Dr. Sara Trowbridge at Children's Hospital Boston.

Abdulla is a 3 year old male with a questionable prolonged seizure in setting of possible VP shunt malfunction. Patient just returned from the OR for emergency EVD placement.

Medications:Keppra, Lorazepam, Kdazolam
Previous EEGs:yes
Location of recording: 7S

PROCEDURE

A 21 channel digital audiovisual electroencephalogram was performed at the patient's bedside on 8/15/2017. The 10/20 International System of electrode placement was used and both bipolar and referential electrode montages were

EEG Report

ACCESSION:	EG-17-0003521	COLLECTED DATE/TIME:	8/15/2017 09:27 EDT
RESPONSIBLE PATHOLOGIST:	ROTENBERG MD, ALEXANDER	RECEIVED DATE/TIME:	8/15/2017 09:27 EDT
ORDERING PHYSICIAN	TROWBRIDGE MD,SARA		

monitored. The patient was not sleep deprived. No sedation was administered. The patient was recorded during the waking drowsy and sleep states. Continuous EEG monitoring began on 8/15/2017 at 22:23 hours and ended on 8/16/2017 at 08:00 hours, constituting a total of 10 hours recording time.

DESCRIPTION

During the awake state, there is no well-defined posterior dominant rhythm or anterior-posterior gradient. The awake recording is continuous. No significant asymmetries of background activity are noted. There is excessive beta range activity over the right hemisphere and midline region. There is also continuous 2-3 Hz polymorphic delta slowing over the left temporal region that at times has a sharply contoured morphology. Of note, evaluation of the left hemisphere is limited due to absence of C3, P3, O1 electrodes around the surgical site.

Sleep State:
As the patient enters stage II of sleep, well-formed spindles and vertex sharp waves are present over the midline and right hemisphere, but are absent over the left frontal region. Arousal is unremarkable.

There is no clear change in the EEG background associated with tactile stimulation.

INTERICTAL ACTIVITY:
There are no epileptiform abnormalities.

ICTAL ACTIVITY:
No seizures are captured during this portion of the monitoring session.

MARKED EVENTS:
There are no marked events.

Activation Procedures:
Hyperventilation and photic stimulation are not performed.

EKG:

EEG Report

ACCESSION:	EG-17-0003521	COLLECTED DATE/TIME:	8/15/2017 09:27 EDT
RESPONSIBLE PATHOLOGIST:	ROTENBERG MD, ALEXANDER	RECEIVED DATE/TIME:	8/15/2017 09:27 EDT
ORDERING PHYSICIAN	TROWBRIDGE MD,SARA		

A prolonged Lead I EKG rhythm strip revealed normal sinus rhythm at approximately 120 beats/minute.

EEG INTERPRETATION

This long term video EEG monitoring in the awake and asleep states is abnormal due to:

1. Continuous slowing over the left temporal region
2. Absent normal elements of waking background
3. Absent normal sleep architecture over the left hemisphere, although array over the left hemisphere is limited
4. Excessive fast frequencies over the midline and right hemisphere

CLINICAL CORRELATION

This EEG is suggestive of lesft hemisphere cortical dysfunction, involving at least the left temporal region in the setting of a moderate, diffuse encephalopathy.

The preliminary findings of this EEG were relayed to the Neurology ICU Team on 8/16/17 at 10 AM.

Melissa Tsuboyama, MD
Epilepsy Fellow

I, the teaching physician, have reviewed this EEG recording with the fellow and agree with the findings above.

SAMONTE , MARIA C/MCS
08/24/17

ROTENBERG MD, ALEXANDER
(electronic signature)

Boston Children's Hospital
300 Longwood Avenue
Boston, MA 02115

BCH MRN: **500-20-94**
Patient Name: **ALDHAHERI, ABDULLA KHALIFA**
DOB/Age/Sex: 2/18/2014 3 years Male

Admit Date: 10/24/2016
Discharge Date: 10/24/2016

Patient Location: Neurophys Lab
Patient Type: Outpatient
Financial #: 6119687503

EEG Report

ACCESSION:	EG-16-0003592	COLLECTED DATE/TIME:	10/24/2016 09:48 EDT
RESPONSIBLE PATHOLOGIST:	HARINI MD,CHELLAMANI	RECEIVED DATE/TIME:	10/24/2016 09:48 EDT
ORDERING PHYSICIAN	COULTER MD,DAVID L		

EEG Report – 10/31/2016 05:50 EDT – Auth (Verified)

CHILDREN'S HOSPITAL BOSTON
Division of Epilepsy and Clinical Neurophysiology
300 Longwood Ave
Boston, MA 02115 USA
phone 617-355-7970 fax 617-730-0463
www.childrenshospital.org

AUDIOVISUAL EEG REPORT

This procedure was requested by Dr. Dsvid Coulter at Children's Hospital Boston.
Abdulla is a ex 25 week premie with cerebral palsy. This EEG is to evaluate for epileptiform activity.
The Patient slept for 4 hours on the night before this test.
Medications: None
Previous EEGs: None
Exam room: 4

PROCEDURE

A 21 channel digital audiovisual electroencephalogram was performed in the Clinical Neurophysiology Laboratory. The 10/20 International System of electrode placement was used and both bipolar and referential electrode montages were monitored. The patient was sleep deprived. No sedation was administered. The patient was recorded during the waking drowsy and sleep

EEG Report

ACCESSION:	EG-16-0003592	COLLECTED DATE/TIME:	10/24/2016 09:48 EDT
RESPONSIBLE PATHOLOGIST:	HARINI MD,CHELLAMANI	RECEIVED DATE/TIME:	10/24/2016 09:48 EDT
ORDERING PHYSICIAN	COULTER MD,DAVID L		

states. Continuous EEG monitoring began on 10/24/2016 at 8:46 hours and ended on 10/24/2016 at 9:38 hours, constituting a total of 45 minutes recording time.

DESCRIPTION

During the awake state with eyes closed the background consists of a 7 Hz posterior dominant rhythm with an amplitude of approximately 40-50 microvolts which attenuates appropriately with eye opening. The recording is continuous. There is a well-developed anterior-posterior gradient.

With drowsiness, there is waxing and waning of the dominant rhythm with eventual replacement by a mixture of beta, alpha and theta activity. As the patient enters stage II of sleep, rudimentary spindles are present. Vertex waves appear to be predominantly in the right. There are notched features noted in sleep. Arousal is unremarkable.

Epileptiform activity: No epileptiform activity is noted.

Seizures: No seizures were captured during the recording.

Hyperventilation: Not performed

Photic stimulation: Using a step-wise increase in photic frequency results in no driving responses or activation of epileptiform activity.

EKG: A prolonged lead I EKG rhythm strip demonstrated a heart rate of approximately 120 beats/minute.

INTERPRETATION

This EEG recorded in the awake and asleep states is abnormal because:

1. Asymmetry of recording in that sleep features are better formed over the right hemisphere as compared to the right

EEG Report

ACCESSION:	EG-16-0003592	COLLECTED DATE/TIME:	10/24/2016 09:48 EDT
RESPONSIBLE PATHOLOGIST:	HARINI MD,CHELLAMANI	RECEIVED DATE/TIME:	10/24/2016 09:48 EDT
ORDERING PHYSICIAN	COULTER MD,DAVID L		

CLINICAL CORRELATION

Asymmetry of sleep features may suggest left hemispheric dysfunction although there are no other supporting features such as slowing over the left hemisphere. There are no epileptiform features in this recording to suggest decreased seizure threshold. Clinical correlation is recommended.

Samata Singhi, MD
Epilepsy Fellow

I, the teaching physician, have reviewed this EEG recording with the fellow and agree with the findings above.

Edwards , Herman/HE
10/31/16

HARINI MD, CHELLAMANI
(electronic signature)

ED Documentation (Text)

DOCUMENT NAME:	Emergency MD
SERVICE DATE/TIME:	8/15/2017 15:42 EDT
PERFORM INFORMATION:	LEE MD,MICHAEL A JR (8/15/2017 15:43 EDT)
SIGN INFORMATION:	NAGLER MD,JOSHUA (8/16/2017 17:32 EDT); LEE MD, MICHAEL A JR (8/15/2017 18:29 EDT)
RESULT STATUS:	Modified

Seizure

Patient: **ALDHAHERI, ABDULLA KHALIFA** **MRN: 500-20-94** **FIN: 6121467356**
Age: **3 years** Sex: **Male** DOB: **2/18/2014**
Associated Diagnoses: **Ventriculoperitoneal shunt malfunction; Spastic quadriplegic cerebral palsy; Hypertension; Tonic seizure**
Author: **LEE MD, MICHAEL A JR**

History of Present Illness

Abdulla is a 3 year old male, former 25 weeker triplet with VP shunt in place, presenting with concern for seizure and shunt malfunction. About an hour prior to arrival, Abdullah threw up several times and afterwards did not return to baseline per mother. She noted eye deviation and continued vomiting.

On arrival here, we noted that he had eye deviation to the left and tonic flexion of the left upper extremity with desaturations to the 80s. We gave lorazepam, which relieved eye deviation and tonic flexion but prompted apnea. We intubated and proceeded to CT scan..

Review of Systems

Constitutional symptoms: denies fever, denies chills.
Skin symptoms: denies rash, denies hives.
ENMT symptoms: denies sore throat, denies nasal congestion.
Respiratory symptoms: denies shortness of breath, denies wheezing.
Cardiovascular symptoms: Negative.
Gastrointestinal symptoms: Vomiting, no diarrhea.
Genitourinary symptoms: no dysuria, no hematuria.
Neurologic symptoms: Seizure, altered level of consciousness.
Hematologic/Lymphatic symptoms: bleeding tendency negative, no petechiae.
Allergy/immunologic symptoms: no food allergies, no impaired immunity.
Additional review of systems information: 10 systems reviewed and negative except as noted above..

Health Status

Allergies:
Allergic Reactions (All)
No known allergies.
Medications: (Selected)
Inpatient Medications
Ordered

ED Documentation (Text)

midazolam: IV 1.4 mg, 1time, Stop 08/15/17 16:00:00 EDT
rocuronium: IV 10 mg, 1time, Dose Form = Injection, Stop 08/15/17 16:00:00 EDT

Prescriptions

Prescribed

Flovent HFA 110 mcg/inh inhalation aerosol: Dose Amount: 2 puff, INH, daily, Dispense Quantity: 1 EA, Refills: 1, Entered: 11/10/16 13:20:41 EST
Nebulizer machine: Nebulizer machine See Instructions, Special Instructions: Use as needed for albuterol delivery, Dispense Quantity: 1 kit, Entered: 09/29/16 11:30:10 EDT
Vitamin D3 400 intl units/mL oral liquid: Dose: 400 unit, Dose Amount: 1 mL, PO, daily, Dispense Quantity: 30 mL, Refills: 2, Entered: 01/31/17 14:56:54 EST
aerochamber with medium mask: aerochamber with medium mask See Instructions, Special Instructions: Use as directed for administration of Flovent, Dispense Quantity: 1 EA, Refills: 1, Entered: 11/10/16 13:20:48 EST
albuterol 1.25 mg/3 mL (0.042%) inhalation solution: Dose: 1.25 mg, INH, Q4hr, PRN Wheezing, Dispense Quantity: 90 mL, Refills: 2, Entered: 09/29/16 11:47:12 EDT.

Immunizations: Up to date, per UAE schedule.

Past Medical/ Family/ Social History

Medical history

Birth history: prematurity complications.
see hpi.

Surgical history: past VP shunt placement.

Family history: siblings also triplets. One in good health and one passed away..

Social history: Lives with family in UAE.

Problem list:

All Problems

Acute vomiting / SNOMED CT 40246014 / Confirmed
Bronchopulmonary dysplasia / SNOMED CT 112216013 / Confirmed
Added by QCC
Childhood asthma / SNOMED CT 350147016 / Confirmed
Added by QCC
Cochlear implant in situ / SNOMED CT 2912474015 / Confirmed
Developmental delay / SNOMED CT 370667011 / Confirmed
Dysarthria / SNOMED CT 14243015 / Confirmed
Feeding difficulties and mismanagement / SNOMED CT 410361018 / Confirmed
Hearing loss / SNOMED CT 25788011 / Confirmed
Mixed receptive-expressive language disorder / SNOMED CT 43176013 / Confirmed
Sensorineural hearing loss, bilateral / SNOMED CT 299259014 / Confirmed
Spastic quadriplegic cerebral palsy / SNOMED CT 3010116017 / Confirmed
Wheeze / SNOMED CT 93176012 / Confirmed
Added by QCC.

Physical Examination

Vital signs: Vital Signs

8/15/2017 15:30 EDT	**Systolic Blood Pressure**	**174 mmHg HI**
	Diastolic Blood Pressure	**129 mmHg HI**
	Heart Rate	70 bpm
	Respiratory Rate	24 br/min

ED Documentation (Text)

Oxygen Saturation (SPO2) 100 % (Modified)

.

General: on first arrival, eyes deviated to the left, tonic flexion of the left upper extremity. Not responsive.
Skin: Warm. dry. no rash.
Head: dolichocephalic
Neck: Supple
Eye: Pupils are equal, round and reactive to light. normal conjunctiva.
Ears, nose, mouth and throat: Oral mucosa moist
Cardiovascular: Regular rate and rhythm. Normal peripheral perfusion.
Respiratory: Respiratory effort but with poor air movement
Gastrointestinal: Soft. Nontender. Non distended.
Musculoskeletal: Moves all extremities
Lymphatics
Psychiatric: not appropriate mood & affect

Medical Decision Making
Rationale 3 year old male former 25 weeker now with VPS presenting with vomiting, altered mental status, hypertension and bradycardia concerning for VP Shunt malfunction and seizure.

Now intubated. CT done. Labs drawn. Neurosurgery & Neurology consulted..
Results review: Lab results : Lab View

8/15/2017 14:48 EDT

pH Venous	**7.138 CRIT**
pCO2 Venous	**77.6 mmHg HI**
WBC	**11.65 K cells/uL HI**
Hemoglobin	12.3 g/dL
Hematocrit	**38.4 % HI**
Platelet	317 K cells/uL
PT (Prothrombin)	12.2 sec
INR	0.90 NA
PTT (Partial Thromboplastin)	28.1 sec
Sodium	143 mmol/L
Potassium	4.14 mmol/L
Chloride	104 mmol/L
CO2	24 mmol/L

.
Radiology results: XR-Skull 3 Views or Less Event Date: 08/15/2017 17:18:36 EDT Updated: 8/15/2017 17:27 EDT
XR-Skull 3 Views or Less
This document has an image
Reason For Exam
evaluate shunt
Report

****

PRELIMINARY REPORT:

ED Documentation (Text)

Images and report may not have been reviewed by an attending

Attending: Connolly MD, Susan

****

SKULL RADIOGRAPH

INDICATION: 3-year-old male with concern for shunt. Additional information obtained from electronic medical record. Patient with history of ventriculoperitoneal shunt for posthemorrhagic hydrocephalus patient presenting with seizure, with concern for shunt malfunction, with left eye deviation, ptotic flexion, and desaturation in the ED.

COMPARISON: CT head 8/15/2017, CT head 6/6/2017, skull radiograph 2/2 /2017, skull radiograph 12/27/2016

TECHNIQUE: AP view of the skull

FINDINGS:
There is redemonstration of a left posterior approach ventriculoperitoneal shunt catheter. There is no kinking or discontinuity. The valve is set to approximately 100 cm H2O. In addition, there is an again seen cochlear implant projecting at the right temporal region.

IMPRESSION:
Left posterior approach ventriculoperitoneal shunt without evidence of kinking/discontinuity.
Signature Line
******* Preliminary Report *******

Dictated by: MISKIN MD, NITYANAND P 08/15/17 17:21

Note:
CT-Head w/o Contrast Event Date: 08/15/2017 15:44:13 EDT Updated: 8/15/2017 15:51 EDT
CT-Head w/o Contrast
This document has an image
Reason For Exam
VP shunt, seizing
Report

.

ED Documentation (Text)

STUDY: CT BRAIN WITHOUT CONTRAST

INDICATION: "vomiting, VP shunt, seizing"

TECHNIQUE: Axial CT of the head was obtained without contrast and multiplanar reformatted images were generated.

COMPARISON: CT head dated 6/6/17.

FINDINGS:
Again seen is a right sided cochlear implant receiver with electrode taking an expected course through the right mastoidectomy into the right round window and terminating in the cochlea. This study does not optimally assess the course/integrity of the cochlear implant hardware though there is no visible discontinuity. The cochlear implant introduces streak artifact on the head CT but diagnostic information is still obtained.

Again seen is a left parietal shunt catheter that terminates within the body of the left lateral ventricle, unchanged in position. The ventricular system is unchanged in size and morphology. There is no abnormal fluid collection or acute intracranial hemorrhage.

There is stable appearance of severe left and mild-moderate right cerebral white matter volume loss, volume loss of the left thalamus, and small size of the right cerebellar encephalomalacia. There is also thinning of the corpus callosum and brainstem. Within the limitations of artifact, there is no new parenchymal finding. Gray-white matter differentiation appears preserved outside areas of focal volume loss. There is no mass effect or basal cistern effacement.

There is small scattered fluid within the right mastoidectomy bowl and middle ear cavity. There is moderate to severe mucosal thickening in the partially visualized paranasal sinuses, new since the prior exam.

IMPRESSION:
Stable shunt position with stable size and morphology of the ventricular system.

No acute intracranial hemorrhage, extra axial fluid collection or new parenchymal abnormal density allowing for streak artifact from the cochlear implant which obscures portions of the brain.

Grossly stable position of a right cochlear implant electrode.

ED Documentation (Text)

New paranasal sinus mucosal disease.
Signature Line
******* Final Report*******

Dictated by: VAUGHN MD, JENNIFER A 08/15/2017 15:39

Verified by: VAUGHN MD, JENNIFER A 08/15/2017 15:49

Note:
XR-Chest 1 View Event Date: 08/15/2017 15:26:57 EDT Updated: 8/15/2017 15:39 EDT
XR-Chest 1 View
This document has an image
Reason For Exam
3 yo intubated for seizure
Report

PORTABLE CHEST RADIOGRAPH, 08/15/2017

HISTORY: The patient is a 3-year-old boy who has been intubated for seizures.

FINDINGS: A single frontal image of the chest was obtained portably and compared with chest radiograph of 11/14/2016. The lungs are hypoinflated, with related bronchovascular crowding. Streaky bibasilar opacities are seen, at least in part related to atelectasis . There is no pleural effusion or pneumothorax. The cardiomediastinum is normal for technique.

The endotracheal tube terminates in the mid to lower thoracic trachea . An enteric tube extends to the gastric antrum/pylorus. Ventriculoperitoneal shunt tubing is visualized over the left neck, chest, and upper abdomen.

IMPRESSION:

1. The lungs are hypoinflated, with related bronchovascular crowding. Bibasilar opacities are seen, at least in part related to atelectasis.

2. The endotracheal tube is in good position in the mid to lower thoracic trachea.

3. An enteric tube extends to the region of the gastric antrum/ pylorus.
Signature Line

ED Documentation (Text)

******* Final Report*******

Dictated by: WALTERS MD, MICHELE M 08/15/2017 15:33

Verified by: WALTERS MD, MICHELE M 08/15/2017 15:36

Note:

.

Reexamination/ Reevaluation

Re-examination/Re-evaluation: Time 08/15/2017 18:23:00, Vital signs Results included from flowsheet : Vital Signs

8/15/2017 17:06 EDT	Temperature	37 DegC
8/15/2017 16:59 EDT	Systolic Blood Pressure	99 mmHg
	Diastolic Blood Pressure	54 mmHg
	Heart Rate	95 bpm
	Respiratory Rate	24 br/min
	Oxygen Saturation (SPO2)	100 %

, Notes CT scan did not show gross change in ventricle size, but given vital sign abnormalities neurosurgery tapped the shunt. They found minimal flow from shunt tap and agreed with our assessment that the patient should be taken to the operating room for a new shunt placement. Afterwards will go to MSICU. .

Impression and Plan

Ventriculoperitoneal shunt malfunction (ICD10-CM T85.09XA, Discharge, Medical)
Spastic quadriplegic cerebral palsy (ICD10-CM G80.8, Discharge, Emergency medicine, Medical)
Hypertension (ICD10-CM I10, Discharge, Emergency medicine, Medical)
Tonic seizure (ICD10-CM G40.409, Discharge, Emergency medicine, Medical)

Calls-Consults

- Neurosurgery, neurology.

Plan

Condition: Critical.

Disposition: Admit: to Surgery.

Counseled: Family, Regarding diagnosis, Regarding diagnostic results, Regarding treatment plan.

Addendum

Teaching-Supervisory Addendum-Brief

I participated in the following activities of this patients care: the medical history, the physical exam, medical decision making.
I personally performed: supervision of the patient's care, the medical history, the physical exam.
The case was discussed with: Fellow.
Evaluation and management service: I agree with the evaluation and management decisions made in this patient's care.
Results interpretation: I agree with the study interpretation in this patient's care.

ED Documentation (Text)

Notes: I have obtained the history and examined the patient I agree with the findings described in the note above. Management of the patient has been carried out in accordance with my plans. . The patient is a 3 1/2 year odl former 25 weeker with IVH and hydrocpehalus s/p VP shunt (in UAE and THailand) evaluated 2 months ago for altered mental status and vomiting, work up for shunt negative, today again with acute onset ot altered mental status and vomiting, on arrival noted to be tonic positioning with stiff left arm, eyes deviated to left, hypoxic, No hx of seizures. No ingestion. No trauma. No clear trigger. Previously evaluated by neuro and neurosurgery and treated as above.

I aw the patient immedaite on arrival,, the patient is tonic, eye deviated by pupils reactive, concerning for tonic seizure actiibyt, non-responseive/purposeful, sats to low 80's HEENT exam wsomewhat dysmoprhic, no swelling over shutn reservoir on left lower pariteal/occipital area. The neck was supple, no breaks in tubuing. the lungs clear to auscultation, no abnormal cardiac sounds, the abdomen was nontender throughout. Neuro exam as described above, tonic, no purposeful movement, eyes deviated. .

History and exam concerning for seizure, les slikley posuring given eye deivation, O2 applied and sats improved, given Ativan 1 dose with near immeidate resolution of motoro movement and eye deviation but loss of spontaneous respiratory effort, requiring bag mask ventillation. Vital signs notable for profound HTN and assocated bradycardia, with continued inadequate respiratory effort. In patient with known shunt and CNA abnl, moved immdately to intubaiton to allow for CT scan. I assisted in the intubation using etiomodiate and rocuronium, initial tube size unable to pass, successful downsized tube, 14 cm at teeth, confirmed position by ETCO2, breath sounds, and later CXR. BP initially refractory to verse and fenatnyl and associated bradycardia more c/w nicreased ICP than agitation or seizure. CT with no change in ventricle size, no mass, no bleed. Neuro and neurosurgery present throughout. Labs normal as reported above, excpte significant respiratory acidosis in setting of seizure. Reasured by CT but vital concerning and repeated bradycardic in ED, though with improving BPs. Neurosurgical staff tapped shunt in ED, minimal fluid return. VP shutn valvle check, appropriate setting per neurosurgery. Continued sedation with fentanfyl and versed boluses, prior to transfer to the OR for EVD by Dr. Madsen. Case also discussed with Dr. Geva, accepting ICU attending. I spent 60 minutes of critical care time with this patient with life threatening respiratory failure, and concern for pending neurological disaster. Admitted in guarded condition (Nagler, MD).

Boston Children's Hospital
300 Longwood Avenue
Boston, MA 02115

BCH MRN: **500-20-94**
Patient Name: **ALDHAHERI, ABDULLA KHALIFA**
DOB/Age/Sex: 2/18/2014 3 years Male

Admit Date: 8/15/2017
Discharge Date: 9/11/2017

Patient Location: 09 NorthWest 9204 A
Patient Type: Inpatient
Financial #: 6121467356

Radiology

ACCESSION	EXAM DATE/TIME	PROCEDURE	ORDERING PROVIDER	STATUS
RA-17-0147836	8/18/2017 09:20 EDT	CT-Head w/o Contrast	WALTON CPNP,TRACY MARIE	Modified

CDM code
2262000108
F70450

Reason For Exam
(CT-Head w/o Contrast) 3 yo CPMH with CNS infection, intubated, concern for increased ICPs this AM.

Report

EXAM TYPE: CT-Head without Contrast

INDICATION: "3 yo CPMH with CNS infection, intubated, concern for increased ICPs this AM.". Per EMR: Dysarthria, prematurity, intracranial hemorrhage and hydrocephalus s/p VP, spastic quadriplegia developmental delay, hearing loss s/p cochlear implant, and retinopathy of prematurity s/p laser treatment. Status post placement of a left frontal external ventricular drain on 8/15/2017.

TECHNIQUE: Axial images from the skull base to vertex were obtained. 2-D sagittal and coronal reformatted images were generated. No intravenous contrast was administered.

COMPARISON: Limited, directed comparison is made to the prior head imaging including the most recent CT head examination dated 8/15/2017.

FINDINGS:

Significant beam hardening artifact arises from the right cochlear implant.

There is dolichocephaly.

There is a left frontal EVD that courses along the interhemispheric fissure and terminates along the medial margin of the left lateral ventricle and may or may not be intraventricular in location. Most of the side holes are extraventricular in location. The previously noted left occipital catheter has been removed.

The left lateral ventricle is mildly enlarged and increased in size.

Radiology

ACCESSION	EXAM DATE/TIME	PROCEDURE	ORDERING PROVIDER	STATUS
RA-17-0147836	8/18/2017 09:20 EDT	CT-Head w/o Contrast	WALTON CPNP,TRACY MARIE	Modified

Report

The right lateral ventricle is mildly enlarged and increased in size. The third interval is normal in size and slightly increased in size. The fourth ventricle is slightly enlarged and stable in size. New intraventricular blood is present within the lateral ventricles.

There is generalized parenchymal atrophy, left greater than right. Known left-sided white matter gliosis is not well appreciated on this examination. The left basal ganglia and left thalamus are small. The right cerebellar hemisphere is small consistent with crossed cerebellar diaschisis.

There is compensatory leftward midline shift. No subdural fluid collection is seen.

Soft tissue fullness is seen within the interpeduncular cistern and hypothalamus. This likely represents midline fusion of the hypothalamus and frontal lobes rather than hypothalamic hamartoma or mass. Attention to this on follow-up imaging is recommended.

There is marked mucosal thickening within the right middle ear cavity and right mastoid air cells. Right cochlear implant leads traverse the right mastoid bone and is coiled within the right cochlea. An air -fluid level is present within the left mastoid air cells. There is marked mucosal thickening within the paranasal sinuses. A nasogastric tube is present.

Scalp swelling in the left occipital parietal region. This is where a prior left occipital catheter was removed. The scalp swelling currently may reflect expression of CSF through the prior catheter tract and burr hole into the subgaleal space.

IMPRESSION:

1.Streak artifact limiting complete assessment of the head and intracranial contents.
2.Removal of the left occipital shunt catheter.
3.Left frontal EVD.
4.Interval increase in the size of the ventricles suggesting inadequate CSF diversion/inadequate shunting.
5.Fluid accumulation within the left occipital scalp region suggesting same (CSF expression).
6.Tip of the EVD is suboptimally positioned with most of the side holes extraventricular.
7.New intraventricular blood.

Radiology

ACCESSION	EXAM DATE/TIME	PROCEDURE	ORDERING PROVIDER	STATUS
RA-17-0147836	8/18/2017 09:20 EDT	CT-Head w/o Contrast	WALTON CPNP,TRACY MARIE	Modified

Report

8.Soft tissue abnormality of the hypothalamus/interpeduncular cistern . This likely represents midline fusion of the hypothalamus and frontal lobes rather than hypothalamic hamartoma or mass. Attention to this on follow-up imaging is recommended.
9.Periventricular leukomalacia, left greater than right.
10.Right-sided cross cerebellar diaschisis.
11.Near complete opacification of the mastoid air cells and middle ear cavities with air-fluid levels possibly representing otomastoiditis.

These findings were discussed with Dr. Hames by Dr. Sarma at approximately 9:15 AM on 8/18/2017 by telephone.
Final report findings were discussed with Dr. Hames by Dr. Sarma at approximately 11:15 AM on 8/18/2017 by telephone.

I, the teaching physician, have reviewed the images with the trainee and agree with the findings

***** *Final Report*****

Dictated by: SARMA MD, ASHA 08/18/2017 09:21

Verified by: SILVERA MD, VICTORIA M 08/18/2017 13:20

Boston Children's Hospital
300 Longwood Avenue
Boston, MA 02115

BCH MRN: **500-20-94**
Patient Name: **ALDHAHERI, ABDULLA KHALIFA**
DOB/Age/Sex: 2/18/2014 3 years Male

Admit Date: 8/15/2017
Discharge Date: 9/11/2017

Patient Location: 09 NorthWest 9204 A
Patient Type: Inpatient
Financial #: 6121467356

Radiology

ACCESSION	EXAM DATE/TIME	PROCEDURE	ORDERING PROVIDER STATUS
RA-17-0145749	8/15/2017 15:44 EDT	CT-Head w/o Contrast	DRIBIN MD,TIMOTHY E Auth (Verified)

CDM code
2262000009
F70450

Reason For Exam
(CT-Head w/o Contrast) VP shunt, seizing

Report

.

STUDY: CT BRAIN WITHOUT CONTRAST

INDICATION: "vomiting, VP shunt, seizing"

TECHNIQUE: Axial CT of the head was obtained without contrast and multiplanar reformatted images were generated.

COMPARISON: CT head dated 6/6/17.

FINDINGS:
Again seen is a right sided cochlear implant receiver with electrode taking an expected course through the right mastoidectomy into the right round window and terminating in the cochlea. This study does not optimally assess the course/integrity of the cochlear implant hardware though there is no visible discontinuity. The cochlear implant introduces streak artifact on the head CT but diagnostic information is still obtained.

Again seen is a left parietal shunt catheter that terminates within the body of the left lateral ventricle, unchanged in position. The ventricular system is unchanged in size and morphology. There is no abnormal fluid collection or acute intracranial hemorrhage.

There is stable appearance of severe left and mild-moderate right cerebral white matter volume loss, volume loss of the left thalamus, and small size of the right cerebellar encephalomalacia. There is also thinning of the corpus callosum and brainstem. Within the limitations of artifact, there is no new parenchymal finding. Gray-white matter differentiation appears preserved outside areas of focal

Radiology

ACCESSION	EXAM DATE/TIME	PROCEDURE	ORDERING PROVIDER STATUS
RA-17-0145749	8/15/2017 15:44 EDT	CT-Head w/o Contrast	DRIBIN MD,TIMOTHY E Auth (Verified)

Report
volume loss. There is no mass effect or basal cistern effacement.

There is small scattered fluid within the right mastoidectomy bowl and middle ear cavity. There is moderate to severe mucosal thickening in the partially visualized paranasal sinuses, new since the prior exam.

IMPRESSION:
Stable shunt position with stable size and morphology of the ventricular system.

No acute intracranial hemorrhage, extra axial fluid collection or new parenchymal abnormal density allowing for streak artifact from the cochlear implant which obscures portions of the brain.

Grossly stable position of a right cochlear implant electrode.

New paranasal sinus mucosal disease.

***** *Final Report*****

Dictated by: VAUGHN MD, JENNIFER A 08/15/2017 15:39

Verified by: VAUGHN MD, JENNIFER A 08/15/2017 15:49

Boston Children's Hospital

300 Longwood Avenue
Boston, MA 02115

BCH MRN: **500-20-94**
Patient Name: **ALDHAHERI, ABDULLA KHALIFA**
DOB/Age/Sex: 2/18/2014 3 years Male

Admit Date: 6/6/2017
Discharge Date: 6/6/2017

Patient Location: Emergency Department 38
Patient Type: Emergency
Financial #: 6121085593

Radiology

ACCESSION	EXAM DATE/TIME	PROCEDURE	ORDERING PROVIDER	STATUS
RA-17-0099334	6/6/2017 19:12 EDT	CT-Head w/o Contrast	MAHONEY MB,Bch, LIAM	Modified

CDM code
2262000009
F70450

Reason For Exam
(CT-Head w/o Contrast) VP shunt check. patient with vomiting and hx of hydrocephalus. Cochlear implant

Report

.

STUDY: CT BRAIN WITHOUT CONTRAST

INDICATION: Former 25 week premature triplet status post ventriculoperitoneal shunt (last surgically revised February 2016, last known shunt valve manipulation December 2016=updialing). Presentation to the emergency room with vomiting

TECHNIQUE: Axial CT of the head was obtained without contrast and multiplanar reformatted images were generated.

COMPARISON: MRI vent check from 12/27/2016.

FINDINGS:
Concordant with history of February 2017 cochlear implantation, there is a new cochlear implant receiver secured to the outer table of the right temporoparietal bone with electrode taking an expected course through the right mastoidectomy into the right round window and the cochlea. This study does not optimally assess the course/integrity of the cochlear implant hardware though there is no visible discontinuity/kinking. The cochlear implant introduces streak artifact on the head CT but diagnostic information is still obtained.

Specifically, there is redemonstration of a left parietal shunt catheter that terminates within the body of the left lateral ventricle, unchanged. Cephalic course of the shunt valve/catheter system appears intact. In this setting, the ventricular system is small with near ependymal coaptation apart from mild distention of the body of the left lateral ventricle. This left lateral ventricular

Radiology

ACCESSION	EXAM DATE/TIME	PROCEDURE	ORDERING PROVIDER	STATUS
RA-17-0099334	6/6/2017 19:12 EDT	CT-Head w/o Contrast	MAHONEY MB,Bch, LIAM	Modified

Report

distention has slightly decreased since December 2016: It currently measures up to 11 mm transverse compared to 16 mm in December. While this change could suggest over shunting or change in shunt valve setting, there is no abnormal fluid collection or acute intracranial hemorrhage.

The brain parenchyma redemonstrates extensive sequela of prematurity. Specifically, there is severe left and mild-moderate right cerebral white matter volume loss, cavitation and volume loss of the left thalamus, and right cerebellar encephalomalacia. Related thinning of the corpus callosum and brainstem. These findings are consistent with sequela of supratentorial and infratentorial germinal matrix hemorrhage, white matter injury of prematurity and possibly prior decompensated bouts of hydrocephalus. Within the limitations of CT and new streak artifact from the cochlear implant, there is no new parenchymal finding. Gray-white matter differentiation appears preserved outside areas of focal volume loss. Although there is some chronic bowing of the midline to the left due to left hemisphere volume loss, there is no positive mass effect or basal cistern effacement.

The mastoid air cells, middle ear cavities, and visualized paranasal sinuses are clear apart from scattered fluid within the right mastoidectomy bowl and middle ear cavity which is to be expected 3 months after surgery. Orbital contents are unremarkable.

IMPRESSION:
Small caliber of the ventricular system with slight reduction in caliber of the shunted left lateral ventricle since December 2016. Therefore, there is no imaging evidence for shunt failure. To the contrary, the observed change could reflect over shunting or down-dialing of shunt valve setting. Advise clinical correlation.

No acute intracranial hemorrhage or fluid collection allowing for streak artifact from new cochlear implant (see below).

Extensive but stable sequela of prematurity, possibly with superimposed sequela of prior decompensated bouts of hydrocephalus.

Placement since December 2016 of a right cochlear implant. While this study is not tailored to evaluate the temporal bone, the cochlear implant and associated electrode appear appropriately positioned.

Radiology

ACCESSION	EXAM DATE/TIME	PROCEDURE	ORDERING PROVIDER	STATUS
RA-17-0099334	6/6/2017 19:12 EDT	CT-Head w/o Contrast	MAHONEY MB,Bch, LIAM	Modified

Report

I, the teaching physician, have reviewed the images with the trainee and agree with the findings

***** *Final Report*****

Dictated by: JAIMES COBOS MD, CAMILO E 06/06/2017 19:32

Verified by: YANG MD, PhD, EDWARD 06/06/2017 21:07

Boston Children's Hospital
300 Longwood Avenue
Boston, MA 02115

BCH MRN: **500-20-94**
Patient Name: **ALDHAHERI, ABDULLA KHALIFA**
DOB/Age/Sex: 2/18/2014 3 years Male

Admit Date: 11/29/2016
Discharge Date: 11/29/2016

Patient Location: Dental Department
Patient Type: Outpatient
Financial #: 6119789967

Ambulatory Documentation

DOCUMENT NAME:	Dental Visit
SERVICE DATE/TIME:	11/29/2016 13:32 EST
PERFORM INFORMATION:	ROSS DDS,ELIZABETH J (11/29/2016 13:42 EST)
SIGN INFORMATION:	ROSS DDS,ELIZABETH J (12/15/2016 13:40 EST); REARDON DMD,JEFFREY (11/29/2016 13:42 EST)
RESULT STATUS:	Auth (Verified)

Problems (Active Only):

Active Problems:
- Bronchopulmonary dysplasia ()
- Childhood asthma ()
- Developmental delay
- Hearing loss
- Speech delay
- Wheeze ()

Home Medication List (Medication Name Only)

**** List generated 11/29/2016 at 13:33. For updated home medication list with details, consult PowerChart Medication List. ****
- aerochamber with medium mask (Misc Prescription)
- albuterol (albuterol 1.25 mg/3 mL (0.042%) inhalation solution)
- fluticasone (Flovent HFA 110 mcg/inh inhalation aerosol)
- Nebulizer machine (Misc Prescription)

Allergies: No known allergies

Chief complaint/concern: Referred from CCS for dental exam.

2 year old male presented for initial exam with mother, brother, and nanny. Patient identified. Medical history reviewed and updated.

Dental History: First dental visit; referred from BCH CCS.

Trauma history: N

Ambulatory Documentation

Medical history : see above

Social History (Guardian/Lives with): parents; international patient.

Exam position (charting- in dental chair, knee-to-knee): knee to knee

Radiographs obtained: unable to take due to behavior

Prophylaxis toothbrush/ rubber cup: toothbrush

Scaling: N

Fluoride varnish: Y

Assisted by: Sandra

Examination Findings:

Extraoral: WNL

Intraoral

Soft Tissues: WNL; no gingivitis

Hard Tissues: Generalized yellow intrinsic discoloration of enamel with some white/brown hypomineralization of cusp tips; some enamel pitting on facial of incisors. No caries.

Dentition:

Age appropriate dentition: Y

Dental age (primary/mixed/permanent dentition): Primary

Ambulatory Documentation

Oral Habits (past/current digit/bruxism): N

Orthodontic Assessment:

Not assessed due to precooperative behavior; generalized interdental spacing on all teeth.

Radiographic Findings:

not indicated

Caries Risk Assessment performed?

Yes

Dental diagnosis: Likely developmental defect of enamel, related to premature birth.

Behavior: F2-3: Age appropriate

Pain: N

Recommendations/Plan: Reviewed diet and hygiene goals below. Recommended to return for 3 month recall.

Oral hygiene instructions given

Sedation planning: No

Type of Visit: Initial.

BIOLOGIC FACTORS

Ambulatory Documentation

Child has history of active caries	N
Mother has active caries	N
Siblings have active caries	N - four older siblings are all caries-free per mom
Continuous bottle use	N
Sleeps with bottle or nurses on demand	N
Juice/milk in Sippy cup	N - only drink water, from cup; does not use bottle anymore
Frequent snacking	2x/day - Bread, coffee cakes, fruit yogurt
SHCN	Y
Potential caries causing medications	N

PROTECTIVE FACTORS

Toothbrushing /frequency	1x/day in AM
Assistance with brushing	Y
Fluoride toothpaste	Y
Topical fluoride (Gelkam, Prevident, ACT)	N
Floss	N
Drinks fluoridated water	N - bottled water

DISEASE INDICATORS/RISK FACTORS (FROM CLINICAL EXAM)

Cavitation	N
New cavitation [NC001]	N
Demineralization/New Demin (WS)	N

Ambulatory Documentation

Radiographic decay	n/a
Enamel defects	Generalized yellow intrinsic discoloration
Visible plaque	N Plaque score: 1111
Gingivitis/Calculus	N
Deep pits/fissures	N

INDICATORS OF IMPROVED CARIES RISK

Remineralization	n/a
New remineralization	n/a
Meeting self-management goals	n/a
Gelkam staining	n/a

Other

Pain due to untreated caries [PN001]	N
Referral to OR/sedation	N

OVERALL CARIES RISK Medium

3 months for Recall/DM/F Varnish

Self management goals

1) Limit sweets to 1x/day max (eg, coffee cake, sweetened yogurt)

Ambulatory Documentation

2) Brush at night as well as in the morning

F-toothpaste 2/day

NV: 3 month recall

Attending: Ross

Resident: Reardon

Assistant: Sandra

Boston Children's Hospital
300 Longwood Avenue
Boston, MA 02115

BCH MRN: **500-20-94**
Patient Name: **ALDHAHERI, ABDULLA KHALIFA**
DOB/Age/Sex: 2/18/2014 3 years Male

Admit Date: 11/29/2016
Discharge Date: 11/29/2016

Patient Location: Dental Department
Patient Type: Outpatient
Financial #: 6119789967

Ambulatory Documentation

DOCUMENT NAME:	Dental Visit
SERVICE DATE/TIME:	11/29/2016 13:09 EST
PERFORM INFORMATION:	REARDON DMD,JEFFREY (11/29/2016 13:11 EST)
SIGN INFORMATION:	ROSS DDS,ELIZABETH J (2/27/2017 11:56 EST); REARDON DMD,JEFFREY (2/12/2017 23:07 EST)
RESULT STATUS:	Auth (Verified)

Problems (Active Only):

Active Problems:
- Bronchopulmonary dysplasia ()
- Childhood asthma ()
- Developmental delay
- Hearing loss
- Speech delay
- Wheeze ()

Home Medication List (Medication Name Only)

**** List generated 11/29/2016 at 13:10. For updated home medication list with details, consult PowerChart Medication List. ****
- aerochamber with medium mask (Misc Prescription)
- albuterol (albuterol 1.25 mg/3 mL (0.042%) inhalation solution)
- fluticasone (Flovent HFA 110 mcg/inh inhalation aerosol)
- Nebulizer machine (Misc Prescription)

Allergies: No known allergies

Chief complaint/concern: Referred from CCS for dental exam.

2 year old male presented for initial exam with parent, brother, and Arabic interpreter. Patient identified. Medical history reviewed and updated.

Dental History: First dental visit; referred from BCH CCS.

Ambulatory Documentation

Trauma history: N

Medical history : see above

Social History (Guardian/Lives with): parents; international patient.

Exam position (charting- in dental chair, knee-to-knee): knee to knee

Radiographs obtained: unable to take due to behavior

Prophylaxis toothbrush/ rubber cup: toothbrush

Scaling: N

Fluoride varnish: Y

Assisted by: Sandra

Examination Findings:

Extraoral: WNL

Intraoral

Soft Tissues: WNL; good oral hygiene.

Hard Tissues: Full primary dentition present with E's partially erupted. No caries noted.

Dentition:

Ambulatory Documentation

Age appropriate dentition: Yes

Dental age (primary/mixed/permanent dentition): primary

Oral Habits (past/current digit/bruxism): _

Orthodontic Assessment:

not assessed due to precooperative behavior

Radiographic Findings:

not indicated

Caries Risk Assessment performed?

Yes

Dental diagnosis: Normal dentition

Behavior: F2-3: Age appropriate for lap to lap

Pain: N

Recommendations/Plan: Reviewed diet and hygiene goals below. Recommended to return for 3 month recall.

Oral hygiene instructions given

Sedation planning: No

Ambulatory Documentation

Type of Visit: Initial.

BIOLOGIC FACTORS

Child has history of active caries	N
Mother has active caries	N
Siblings have active caries	N - four older siblings are all caries-free per mom
Continuous bottle use	N
Sleeps with bottle or nurses on demand	N
Juice/milk in Sippy cup	N - only drink water, from cup; does not use bottle anymore
Frequent snacking	2x/day - Bread, coffee cakes, fruit yogurt
SHCN	Y
Potential caries causing medications	N

PROTECTIVE FACTORS

Toothbrushing /frequency	1x/day in AM
Assistance with brushing	Y
Fluoride toothpaste	Y
Topical fluoride (Gelkam, Prevident, ACT)	N
Floss	N
Drinks fluoridated water	N - bottled water

Ambulatory Documentation

DISEASE INDICATORS/RISK FACTORS (FROM CLINICAL EXAM)

Cavitation	N
New cavitation [NC001]	N
Demineralization/New Demin (WS)	N
Radiographic decay	n/a
Enamel defects	N
Visible plaque	N Plaque score: 1111
Gingivitis/Calculus	N
Deep pits/fissures	N

INDICATORS OF IMPROVED CARIES RISK

Remineralization	n/a
New remineralization	n/a
Meeting self-management goals	n/a
Gelkam staining	n/a

Other

Pain due to untreated caries [PN001]	N
Referral to OR/sedation	N

OVERALL CARIES RISK Medium - SHCN

Ambulatory Documentation

3 months for Recall/DM/F Varnish

Self management goals

1) Limit sweets to 1x/day max (eg, coffee cake, sweetened yogurt)

2) Brush at night as well as in the morning

F-toothpaste 2/day

NV: 3 month DMV/recall, assess changes in home care

Attending: Ross

Resident: Reardon

Assistant: Sandra

Boston Children's Hospital
300 Longwood Avenue
Boston, MA 02115

BCH MRN: **500-20-94**
Patient Name: **ALDHAHERI, ABDULLA KHALIFA**
DOB/Age/Sex: 2/18/2014 3 years Male

Admit Date: 9/29/2016
Discharge Date: 9/29/2016

Patient Location: Complex Care/Waltham
Patient Type: Outpatient
Financial #: 6119525994

Ambulatory Documentation

DOCUMENT NAME:	Complex Care Visit
SERVICE DATE/TIME:	9/29/2016 00:00 EDT
PERFORM INFORMATION:	GLADER MD,LAURIE J (9/29/2016 12:55 EDT)
SIGN INFORMATION:	GLADER MD,LAURIE J (10/3/2016 23:47 EDT)
RESULT STATUS:	Auth (Verified)

Identifying information: Abdulla is a 31-month-old male from the UAE here in Boston with his family for evaluation of his spastic quadriplegic cerebral palsy and associated medical and developmental concerns. His parents are interested in optimizing his medical and developmental health.

Medical concerns:
Spastic quadriplegic cerebral palsy with superimposition of right hemiplegia.
Global developmental delay
History of intracranial hemorrhage resulting in hydrocephalus now shunted
Concern for hearing loss.

Past medical history: Abdulla is here today with his twin brother, who is also being evaluated, both of his parents and his maternal uncle. Arabic interpretation was offered however the family felt very comfortable in English and denied need for support.

Abdulla is one of triplets born at 25 weeks 5 days gestation and weighing about 800 grams. Abdulla spent approximately 4 months in the neonatal intensive care unit. The third sibling unfortunately died at approximately age 40 weeks from complications of prematurity. Abdulla required mechanical ventilation for approximately 6 weeks, was transitioned to CPAP and then off. By the time he was discharged from the hospital he had no residual active respiratory concerns. His hospital course was also complicated by intracranial hemorrhages resulting in hydrocephalus and ventriculoperitoneal shunt placement at 40 weeks. Additional issues addressed in the NICU included the development of retinopathy of prematurity requiring laser treatment and second stage surgery, as well as herniorrhaphy.

Over time, Abdulla's development has been delayed. He is a very social boy who vocalizes and responds to voice and facial expression and generally communicates by nonspecific vocalizations and facial expression or gesture. He is not yet pointing to communicate his needs. From a motoric standpoint Abdulla has been rolling in both directions since approximately age 12 months and sitting independently since age 2 years. He is not able to get into a seated position independently and is not yet pulling to stand. He has been combat crawling since 18 months and enjoys taking steps with assistance or in a gait trainer. Abdulla has a strong preference for his left hand but is able to grasp objects with either hand and transfer. He is not able to self feed; he tries to hold the bottle but needs assistance.

Ambulatory Documentation

From a medical standpoint, Abdulla has been relatively stable. He has undergone stem cell treatment on two occasions in Thailand to treat his cerebral palsy. The family feels the stem cell therapy has been very helpful for Abdulla as well as his brother and they feel that they have witnessed motoric and cognitive changes after each treatment.

Abdulla did have an episode last winter of marked lethargy and vomiting without fever for which he was hospitalized approximately 5 days in the UAE. The etiology of his symptoms were unclear. The family subsequently went to Thailand where his symptoms persisted and he was hospitalized for several days there and diagnosed with a severe ear infection. He required antibiotics for 3 weeks and cleared. One month later he underwent revision of his VP shunt (February 2016).

Review of systems
Cardiology: No concerns.

Pulmonary: Abdulla seems susceptible to regular respiratory illnesses and as soon as he develops symptoms he uses albuterol. He has also used another inhaled medication which his mother could not identify but may well be in inhaled steroid as at times he has taken another inhaler for a month on a twice daily basis. He has had intermittent courses of antibiotics for respiratory infections, although he has not been formally diagnosed with pneumonias. He is here in the United States without a nebulizer or access to bronchodilator treatment.

ENT/audiology: Abdulla evidently had an ABR early on that revealed a markedly abnormal response however with repeat behavioral testing it sounds as if he was felt to be somewhat responsive. His course has waxed and waned. He was given hearing aids but subsequently was felt to improve and has not been using aids. However, in the months since his severe ear infection his parents feel that he is less responsive to sound. He is scheduled to be seen by Dr. Kenna in the Otolaryngology Program in the next few days.

FEN/GI: Abdulla over time has made very nice progress with his chewing and swallowing skills. His parents report that they cut table food up into small bites but that they do not any longer have to puree or mash foods and he is able to lateralize his tongue, moving food from side to side. He does not cough choke or gag while drinking or eating if food is prepared appropriately for him. He has recently started refusing the bottle which has made it challenging for him to take milk. He is not on any supplemental formula. Abdulla stools daily to twice daily without difficulty. He is not on any laxative or stool softening agents. He does not vomit with any regularity and has no evidence of GI discomfort or gastroesophageal reflux disease at this point.

Neurology: There is no past history of overt seizure activity. I understand that MRI and EEG studies have been obtained previously. Dr. Coulter of neurology has seen Abdulla and is ordering updated MRI and EEG studies and will see Abdulla after those tests are back.

Genetics: In the extended family there is a cousin who has cerebral palsy on the basis of hypoxic ischemia in the neonatal period and who also has a seizure disorder. There was a pregnancy on the maternal side of the family that terminated at 9 months secondary to nuchal cord. Abdulla's parents are not consanguineous.

Renal/Urology: There is no history or concern about Abdulla's kidney function. There have been no urinary tract infections nor any evidence of urinary retention.

Ambulatory Documentation

Musculoskeletal: Abdulla has been seen by Dr. Fogelman of Physiatry who has prescribed bilateral solid AFOs which the family is currently awaiting. Additionally he referred Abdulla to the equipment clinic for an adaptive stroller as well as for PT, OT and speech therapies. At this point there is no indication for systemic or focal tone management but he will be observed. X-rays of the spine were negative for any evidence of early scoliosis and his hip films revealed well-formed femoral heads and slight uncovering of the right head that resolved in abduction.

Endocrine: No history of fracture. No thyroid concerns. No problems with glucose regulation.

Ophthalmology: Abdulla is status post treatment for retinopathy of prematurity. His parents report that he has good visual acuity. He is to be seen by ophthalmology tomorrow.

Dental: Abdulla's parents are concerned about discoloration of his teeth and would very much like for him to be seen in the Dental Program.

Hematology: No identified concerns.

Infectious disease: No identified concerns.

Home Medication List

albuterol 1.25 mg/3 mL (0.042%) inhalation solution
1.25 mg INH Q4hr PRN:Wheezing
Nebulizer machine (Misc Prescription)
Use as needed for albuterol delivery

Allergies: No known allergies

Surgeries:
VP shunt at 40 weeks, revision 2/16
Laser treatment for ROP and second stage surgery.
Herniorrhaphy.

Hospitalizations:
Lethargy and vomiting January 2016 followed by repeat hospitalization for what ultimately proved to be a severe ear infection.

Devices:
Hearing aids not actively using
Ventriculoperitoneal shunt

Provider team
Complex Care Service Dr. Laurie Glader
Neurology Dr. David Coulter
Physiatry Dr. David Fogelman.

Ambulatory Documentation

Otolaryngology Dr. Margaret Kenna
Ophthalmology Dr. Alkharashi

Supports and services
Therapies: At home in the UAE Abdulla has received PT, OT and speech three times weekly for 3 hours. Additionally he has received home-based services of speech and feeding. He also participates in aqua therapy.

Equipment: Ankle-foot orthoses (awaiting new), stander.

Physical exam
Heart Rate: 127 H; Systolic Blood Pressure: 80 L; Diastolic Blood Pressure: 51; Respiratory Rate: 24; Oxygen Saturation (SPO2): 98; Patient In Pain Now: No
Weight: 12.1 kg (12%ile)*; Length: 87.0 cm (6%ile)*; Stature Type: Standing; Head Circumference: 48 cm (19%ile)*; Body Mass Index: 16 kg/m2 (43%ile)*
*CDC chart used to calculate percentile value.

General: Abdulla was an adorable and alert young boy with dolichocephaly who vocalized frequently throughout the assessment and sought attention. He had excellent reciprocal eye gaze and responded to ambient sound.
Skin: No rashes, lesions or areas of breakdown.
HEENT: Tympanic membranes were gray bilaterally, ocular conjunctivae were anicteric noninjected, there was no rhinorrhea, oropharynx was pink and moist with slightly high palate normal uvula. No pooling of secretions. No posterior oropharyngeal findings.
Neck: No lymphadenopathy or thyroid irregularity.
Cardiac: Normodynamic precordium regular rate and rhythm without murmur. No cyanosis, clubbing or edema.
Chest: Clear to auscultation.
Abdomen: Well-healed incision from VP shunt placement soft, nontender, nondistended with good bowel sounds. No organomegaly or appreciable masses.
GU: Normal external male genitalia with bilaterally descended testes.
Back: Is straight without a sacral dimple.
Neuromotor moves all 4 extremities spontaneously. Increased appendicular tone was apparent with substantial asymmetry right being tighter than left particularly in the upper extremities.

Impression and plan: In summary, Abdulla is an adorable triplet with history of significant prematurity and intraventricular hemorrhage resulting in shunted hydrocephalus and global developmental delay who presents today for baseline evaluation in the Complex Care Service and recommendations regarding mechanisms to optimize his health and development while here in Boston. Overall he appears to be stable and is undergoing assessment by neurology and physiatry with regards to need for further diagnostic testing as well as interventions to assist with his motoric development.

Abdulla has global developmental delay and will benefit not only from motoric and speech intervention but assessment of his global communication skills. It is imperative that we understand his vision and hearing as we consider ways to optimize his communication and those appointments have been set up. I strongly recommend that he be evaluated in the Augmentative Communication Program to determine additional mechanisms for promoting autonomy in his communication.

Ambulatory Documentation

From a medical standpoint Abdulla has a history of intermittent bronchospasm which sounds like at times has been troublesome enough to warrant sustained periods of steroid treatment either inhaled are enteral. I have prescribed a nebulizer machine as well as albuterol and recommend referral to the Pulmonary Program.

Additionally from a nutrition and GI standpoint Abdulla appears to be building on his feeding skills. He is, however, refusing the bottle and I have stressed the importance of having him have access to milk and the importance of vitamin D and calcium in his diet to promote bone health. A Feeding Team evaluation to examine the feeding patterns and any interventions which might further enhance his skills would be quite helpful.

Care Coordination
Recommended referrals:
Pulmonary medicine.
Nutrition
Augmentative Communication Program
Feeding Team
Dental

Studies: With first blood draw recommend 25-hydroxyvitamin D level.

Medication prescriptions and or other interventions.
Albuterol 0.125 mg every 4-6 hours as-needed
Flu shot was given today

It was my pleasure to see Abdulla. Requests for albuterol and a nebulizer machine have been sent to the International Case Management office. I very much appreciate the opportunity to be involved in Abdullah's care.

Sincerely,

Laurie Glader, MD
Attending Pediatrician
Complex Care Services

Boston Children's Hospital

300 Longwood Avenue
Boston, MA 02115

BCH MRN: **500-20-94**
Patient Name: **ALDHAHERI, ABDULLA KHALIFA**
DOB/Age/Sex: 2/18/2014 3 years Male

Admit Date: 9/26/2017
Discharge Date: 9/26/2017

Patient Location: CT Radiology
Patient Type: Outpatient
Financial #: 6121693414

Radiology

ACCESSION	EXAM DATE/TIME	PROCEDURE	ORDERING PROVIDER	STATUS
RA-17-0173421	9/26/2017 12:44 EDT	CT-Head w/o Contrast	BIRCH ,ASHLEY K	Modified

CDM code
2262000009
F70450

Reason For Exam
(CT-Head w/o Contrast) hydrocephalus s/p vp shunt placement

Report

.

CT-Head w/o Contrast

HISTORY: Hydrocephalus status post ventriculoperitoneal shunt.

COMPARISON: Multiple prior examinations including most recent head CT dated 9/7/2017

TECHNIQUE: The study consists of axial images from the skull base to slightly below the vertex; the vertex of the brain was not included in the field of view. No intravenous contrast was administered.

FINDINGS: Resolved pneumocephalus. Left frontal-approach ventriculostomy catheter terminates in similar position in the foramen of Monro/third ventricle. Asymmetry of the ventricles persists with the right decompressed and the left enlarged, but not significantly changed as compared to 9/7/2017. There is no evidence of acute intracranial hemorrhage. There are no parenchymal density abnormalities, mass lesions, hydrocephalus, or extracerebral collections.

IMPRESSION: Ventricular size not significantly changed from 9/7/2017 with interval resolution of pneumocephalus. This exam should serve as a new baseline for ventricular size.

I, the teaching physician, have reviewed the images with the trainee and agree with the findings

Radiology

ACCESSION	EXAM DATE/TIME	PROCEDURE	ORDERING PROVIDER	STATUS
RA-17-0173421	9/26/2017 12:44 EDT	CT-Head w/o Contrast	BIRCH ,ASHLEY K	Modified

Report
***** *Final Report*****

Dictated by: GUENETTE MD, JEFFREY 09/26/2017 12:43

Verified by: DANEHY MD, AMY R 09/26/2017 13:32

Boston Children's Hospital
300 Longwood Avenue
Boston, MA 02115

BCH MRN: **500-20-94**
Patient Name: **ALDHAHERI, ABDULLA KHALIFA**
DOB/Age/Sex: 2/18/2014 3 years Male

Admit Date: 8/15/2017
Discharge Date: 9/11/2017

Patient Location: 09 NorthWest 9204 A
Patient Type: Inpatient
Financial #: 6121467356

Radiology

ACCESSION	EXAM DATE/TIME	PROCEDURE	ORDERING PROVIDER	STATUS
RA-17-0160818	9/7/2017 16:55 EDT	CT-Head w/o Contrast	BIRCH ,ASHLEY K	Auth (Verified)

CDM code
2262000009
F70450

Reason For Exam
(CT-Head w/o Contrast) hydrocephalus, pt self dc'd EVD

Report

This report is flagged for special attention.

EXAM TYPE: CT-Head w/o Contrast

INDICATION: "VP shunt. Hydrocephalus. Patient self dc'ed EVD".

TECHNIQUE: Axial images from the skull base to vertex were obtained using a fast imaging technique after consultation with NP Birch regarding necessity for sedation for longer stealth imaging protocol. 2-D sagittal and coronal reformatted images were generated. No intravenous contrast was administered.

COMPARISON: Limited, directed comparison is made to the prior CT head dated 9/5/17.

FINDINGS:
Significant beam hardening artifact arises from the right cochlear implant.

There is dolichocephaly.

The left frontal EVD catheter has been removed with air along the catheter tract.

The left lateral ventricle is mildly enlarged and allowing for differences in slice angulation, remains stable in size compared to prior. The right lateral ventricle is mildly enlarged and stable in size. The third ventricle is not enlarged and minimally decreased in size. The fourth ventricle is slightly enlarged and stable in size. There is new large intraventricular air in the frontal horns.

Radiology

ACCESSION	EXAM DATE/TIME	PROCEDURE	ORDERING PROVIDER	STATUS
RA-17-0160818	9/7/2017 16:55 EDT	CT-Head w/o Contrast	BIRCH ,ASHLEY K	Auth (Verified)

Report

Decreased volume of blood layers within the occipital horns.

There is generalized parenchymal atrophy, left greater than right. Known left-sided white matter gliosis is not well appreciated on this examination. The left basal ganglia and left thalamus are small. The right cerebellar hemisphere is small. There is stable mild compensatory leftward midline shift. No subdural fluid collection is seen. No herniation.

Right cochlear implant leads traverse the right mastoid bone and is coiled within the right cochlea. The mastoid air cells are clear.

Mild paranasal sinus mucosal thickening. A nasogastric tube is present.

Scalp swelling in the left occipital parietal region, is again decreased from prior.

IMPRESSION:
Interval removal of the left frontal EVD with new air along the catheter tract and within the lateral ventricles.
Allowing for differences in slice angulation, the left lateral ventricle and third ventricle remain stable in size.
Decreased intraventricular blood.

***** *Final Report*****

Dictated by: VAUGHN MD, JENNIFER A 09/07/2017 16:56

Verified by: VAUGHN MD, JENNIFER A 09/07/2017 17:06

Boston Children's Hospital
300 Longwood Avenue
Boston, MA 02115

BCH MRN: **500-20-94**
Patient Name: **ALDHAHERI, ABDULLA KHALIFA**
DOB/Age/Sex: 2/18/2014 3 years Male

Admit Date: 8/15/2017
Discharge Date: 9/11/2017

Patient Location: 09 NorthWest 9204 A
Patient Type: Inpatient
Financial #: 6121467356

Radiology

ACCESSION	EXAM DATE/TIME	PROCEDURE	ORDERING PROVIDER	STATUS
RA-17-0158502	9/5/2017 05:47 EDT	CT-Head w/o Contrast	ALEXOPOULOS MD, GEORGIOS	Modified

CDM code
2262000009
F70450

Reason For Exam
(CT-Head w/o Contrast) hydrocephalus s/p ETV; L frontal EVD clamped; plan for EVD removal, check vent status

Report

EXAM TYPE: CT-Head w/o Contrast

INDICATION: "VP shunt. Hydrocephalus status post ETV. Left frontal EVD clamped. Plan for EVD removal. Check vent status". Per EMR: Premature infant with history of posthemorrhagic hydrocephalus with prior shunt infection and external drain placement with malfunction. Most recently status post left frontal external ventricular drain revision and endoscopic third ventriculostomy on 8/24/2017. EVD has been clamped with plans of removing drain.

TECHNIQUE: Axial images from the skull base to vertex were obtained. 2-D sagittal and coronal reformatted images were generated. No intravenous contrast was administered.

COMPARISON: Limited, directed comparison is made to the prior head imaging including the most recent CT head examination dated 8/25/2017.

FINDINGS:

Significant beam hardening artifact arises from the right cochlear implant.

There is dolichocephaly.

The left frontal EVD catheter has been repositioned and now terminates more posteriorly within the posterior aspect of the left lateral ventricle.

The left lateral ventricle is mildly enlarged and allowing for differences in slice angulation is minimally decreased in size

Radiology

ACCESSION	EXAM DATE/TIME	PROCEDURE	ORDERING PROVIDER	STATUS
RA-17-0158502	9/5/2017 05:47 EDT	CT-Head w/o Contrast	ALEXOPOULOS MD, GEORGIOS	Modified

Report

compared to prior. The right lateral ventricle is mildly enlarged and stable in size. The third ventricle is not enlarged and minimally decreased in size. The fourth ventricle is slightly enlarged and stable in size.

The previously seen intraventricular pneumocephalus has resolved. Decreased volume of blood layers within the occipital horns.

There is generalized parenchymal atrophy, left greater than right. Known left-sided white matter gliosis is not well appreciated on this examination. The left basal ganglia and left thalamus are small. The right cerebellar hemisphere is small consistent with crossed cerebellar diaschisis.

There is compensatory leftward midline shift. No subdural fluid collection is seen.

The known fullness within the interpeduncular cistern and hypothalamus is not apparent on this CT examination but could be better assessed with MRI.

Right cochlear implant leads traverse the right mastoid bone and is coiled within the right cochlea.

Mild paranasal sinus mucosal thickening. A nasogastric tube is present.

Scalp swelling in the left occipital parietal region, is decreased from prior.

There is minor mucosal thickening within the paranasal sinuses. The mastoid air cells are clear. The adenoids are enlarged.

IMPRESSION:

1.Repositioning of the left frontal EVD.
2.Allowing for differences in slice angulation, the left lateral ventricle and third ventricle are slightly decreased in size. The remainder of the ventricles are stable.
3.Decreased intraventricular blood and resolved intraventricular pneumocephalus.

Radiology

ACCESSION	EXAM DATE/TIME	PROCEDURE	ORDERING PROVIDER	STATUS
RA-17-0158502	9/5/2017 05:47 EDT	CT-Head w/o Contrast	ALEXOPOULOS MD, GEORGIOS	Modified

Report

I, the teaching physician, have reviewed the images with the trainee and agree with the findings

***** *Final Report*****

Dictated by: JOHNSON MD, OREN W 09/05/2017 05:17

Verified by: SILVERA MD, VICTORIA M 09/05/2017 08:20

Boston Children's Hospital
300 Longwood Avenue
Boston, MA 02115

BCH MRN: **500-20-94**
Patient Name: **ALDHAHERI, ABDULLA KHALIFA**
DOB/Age/Sex: 2/18/2014 3 years Male

Admit Date: 8/15/2017
Discharge Date: 9/11/2017

Patient Location: 09 NorthWest 9204 A
Patient Type: Inpatient
Financial #: 6121467356

Radiology

ACCESSION	EXAM DATE/TIME	PROCEDURE	ORDERING PROVIDER	STATUS
RA-17-0152153	8/25/2017 03:34 EDT	CT-Head w/o Contrast	ALEXOPOULOS MD, GEORGIOS	Modified

CDM code
2262000108
F70450

Reason For Exam
(CT-Head w/o Contrast) s/p ETV , EVD placement; desaturations postop r/o acute hydrocephalus

Report

Change to the original report

Exam: Noncontrast head CT

INDICATION: 3 year 6-month-old boy now postop for ventricular drain revision. Patient also has third ventriculostomy.

COMPARISON: Multiple priors. Most recent study 8/22/2017.

TECHNIQUE: Noncontrast 5 mm helical CT images from skull base through skull vertex with multiplanar reformats

FINDINGS:
There have been interval shunt revision with a shunt catheter which enters through the left frontal approach and terminates within the medial body of the left lateral ventricle. There has been no interval change in the size of the right lateral ventricle. There has been minimal decrease in size of the left lateral ventricle.The third ventricle measures approximately 5 mm across, previously 7. There is postprocedural pneumocephalus. Small amount of fluid is noted around the extracalvarial aspect of the new ventricular drain.

There is persistent intraventricular blood layering dependently.

Patient has a right-sided cochlear implant.

Soft tissue density is noted in the interpeduncular cistern. As previously recommended, continued attention is recommended on future studies.

Radiology

ACCESSION	EXAM DATE/TIME	PROCEDURE	ORDERING PROVIDER	STATUS
RA-17-0152153	8/25/2017 03:34 EDT	CT-Head w/o Contrast	ALEXOPOULOS MD, GEORGIOS	Modified

Report

There is soft tissue thickening over the left parietal bone over a site of prior calvarial burr hole. The amount of fluid tracking in the subgaleal space at this location is diminished when compared with study from August 18, 2017.

Patient has dolichocephaly.

There is volume loss in the left cerebral hemisphere, as well as white matter gliosis. There is porencephalic dilatation of the left lateral ventricle. There is a small left basal ganglia, left thalamus , left midbrain and pons consistent with Wallerian degeneration. Gliotic changes are better demonstrated on previous MRI. There is also asymmetrically diminished right cerebellar hemispheric volume, compatible with crossed cerebellar diaschisis.

IMPRESSION:

1. Study is technically limited due to patient motion, cochlear implant beam hardening, and portable low-dose CT technique.
2. New shunt catheter entering via the left frontal approach which terminates within the body of the left lateral ventricle. There has been no interval change in size of the right lateral ventricle. There has been minimal decrease in size of the left lateral ventricle and third ventricle. There is postprocedural pneumocephalus. There is a small amount of fluid within the soft tissue around the new drain. Small focus of gas is noted in the calvarial burr hole following prior shunt removal.
3. Stable intraventricular hemorrhage.
4. Chronic findings likely related to prior left-sided grade 4 germinal matrix hemorrhage with porencephalic dilatation of the left lateral ventricle, Wallerian degeneration and crossed cerebellar diaschisis.

Findings regarding stable dilated ventricular configuration despite drain revision were conveyed to Dr. DeSouza at 0415 hours.

Revised interpretation was conveyed via phone by Dr. Tina Young Poussaint to Dr. Martina Mustroph of neurosurgery at 7:41 AM on August 25, 2017.

I, the teaching physician, have reviewed the images with the trainee and agree with the findings

Radiology

ACCESSION	EXAM DATE/TIME	PROCEDURE	ORDERING PROVIDER	STATUS
RA-17-0152153	8/25/2017 03:34 EDT	CT-Head w/o Contrast	ALEXOPOULOS MD, GEORGIOS	Modified

Report
****** Final Report******

Dictated by: DONOHUE MD, TIMOTHY J 08/25/2017 03:52

Verified by: YOUNG POUSSAINT MD, TINA 08/25/2017 07:46

Boston Children's Hospital
300 Longwood Avenue
Boston, MA 02115

BCH MRN: **500-20-94**
Patient Name: **ALDHAHERI, ABDULLA KHALIFA**
DOB/Age/Sex: 2/18/2014 3 years Male

Admit Date: 8/15/2017
Discharge Date: 9/11/2017

Patient Location: 09 NorthWest 9204 A
Patient Type: Inpatient
Financial #: 6121467356

Radiology

ACCESSION	EXAM DATE/TIME	PROCEDURE	ORDERING PROVIDER	STATUS
RA-17-0150178	8/22/2017 12:48 EDT	CT-Head w/o Contrast	ISIBOR FNP, CHRISTOPHER	Modified

CDM code
2262000009
F70450

Reason For Exam
(CT-Head w/o Contrast) hx of shunted hydrocephalus s/p L sided EVD placement 8/15/2017, and subsequent VP shunt removal for CSF infection on 8/17/2017, by Dr Madsen. Please assess vent size

Report

EXAM TYPE: PORTABLE CT OF THE HEAD WITHOUT CONTRAST

INDICATION: "History of shunted hydrocephalus status post left-sided external ventricular drain placement on 8/15/2017 and subsequent ventriculoperitoneal shunt removal for CSF infection on 8/17/2017. Please assess vent size.

TECHNIQUE: Axial images from the skull base to vertex were obtained. 2-D sagittal and coronal reformatted images were generated. No intravenous contrast was administered.

COMPARISON: Limited, directed comparison is made to the prior head examinations including the most recent dated 8/18/2017.

FINDINGS:

Streak artifact arises from the cochlear implant.

The left frontal catheter is pulled back and now terminates within the interhemispheric fissure. The catheter does not traverse the ventricular system.

The left lateral ventricle is moderately enlarged and increased in size. The right lateral ventricle is mildly enlarged and increased in size. The third ventricle is mildly enlarged and increased in size. The fourth ventricle is mildly enlarged and stable in size.

Intraventricular blood layers within the occipital horns.

Radiology

ACCESSION	EXAM DATE/TIME	PROCEDURE	ORDERING PROVIDER	STATUS
RA-17-0150178	8/22/2017 12:48 EDT	CT-Head w/o Contrast	ISIBOR FNP, CHRISTOPHER	Modified

Report

There is generalized parenchymal volume loss, left greater than right.

A left-sided porencephalic cyst is present within the left frontal parietal region. Additionally, there is atrophy of the left basal ganglia, left thalamus and left-sided Wallerian degeneration with crossed right-sided cerebellar diaschisis.

Note is made of an old surgical tract and burr hole within the left occipital region.

The skull is dolichocephalic.

Streak artifact arises from the right cochlear implant. Post surgical changes are present status post right cochlear implant placement. The right cochlear lead is stable when compared to the most recent head CT dated 8/18/2017. A nasogastric tube is present.

There is mild to moderate mucosal thickening within the paranasal sinuses. The adenoids are enlarged.

IMPRESSION:

1.Pulled back left frontal catheter.
2.The catheter does not traverse the ventricular system.
3.Interval enlargement of the ventricles. In the appropriate clinical setting this represents shunt malfunction.
4.Findings related to prior probable left grade 4 germinal matrix hemorrhage unchanged.

These findings were discussed with Dr. Isibor of neurosurgery by Dr. George at 1:00 PM on 8/22/2017 by telephone.

I, the teaching physician, have reviewed the images with the trainee and agree with the findings

***** *Final Report*****

Dictated by: GEORGE MD, MICHAEL P 08/22/2017 12:28

Verified by: SILVERA MD, VICTORIA M 08/22/2017 14:30

Ambulatory Documentation

DOCUMENT NAME:	Communication Enhancement Visit
SERVICE DATE/TIME:	1/3/2017 11:10 EST
PERFORM INFORMATION:	CLARK PhD,TERRELL A (1/6/2017 11:11 EST)
SIGN INFORMATION:	CLARK PhD,TERRELL A (1/6/2017 11:11 EST)
RESULT STATUS:	Auth (Verified)

COCHLEAR IMPLANT TEAM CONSULTATIVE REPORT

Abdulla AlDhaheri and his brother (Mohamed) and their mother were seen for consultation with three members of the Cochlear Implant team - pediatric psychologist, Terrell A. Clark, PhD; speech-language pathologist, Nicole Salamy, MS, CCC-SLP; and occupational therapist, Susanne Russell, OT-R . This consultative visit through the Boston Children's Hospital at the Waltham site was arranged as components of the process of investigating whether Abdulla would be a “candidate” for cochlear implantation and to address the mother’s questions, offer information, and provide anticipatory guidance.

Diagnosed with bilateral, auditory neuropathy (a condition also referred to as auditory dys-synchrony) and functioning basically as having hearing loss of profound degree, his parents apparently came to Boston Children’s Hospital seeking consideration of cochlear implantation for Abdulla . The family is from the UAE. Abdulla has been seen by otolaryngologist, Dr. Margaret Kenna and audiologists Jennifer Butler and Ashleigh Lewkowitz, AuD, CCC-A. While here, Abdulla also has been seen through

Born at 25 weeks gestation, complications of such extreme prematurity resulted in a complex neonatal medical course. He is one of two surviving boys from a triplet pregnancy. Abdulla was admitted to the NICU, suffered intracranial hemorrhage with hydrocephalus and is status post VP shunt and bronchopulmonary dysplasia. Sequelae to this history includes encephalopathy, spastic quadriplegic cerebral palsy, retinopathy of prematurity status post laser treatment, bilateral auditory dys-synchrony, and global developmental compromise.

Seen by pediatric neurologist, Dr. David Coulter, he reported that “the MRI scan which was done on 10/28/2016 showed that the left hemisphere was significantly more abnormal compared to the right. One thing that is striking is that the cerebral cortex or the cortical ribbon is pretty intact especially over the right hemisphere. There is definitely some cortical injury in the left hemisphere, which could have an impact on his development of speech and language, but I suspect that the more intact right hemisphere is going to be able to compensate for that. I would caution that there is some abnormality in the right hemisphere, especially in the white matter, which may limit some of his ability to compensate however.” The report goes on to describe, “The shunt was readily visualized and seems to terminate in the left lateral ventricle near the left thalamus. There was no suggestion of any increased intracranial pressure.”

During this visit, the process of determining “candidacy” for cochlear implantation was discussed with his mother. She was assured that planning for both Abdulla, and his brother Mohamed, would be considered jointly. There are many factors to be considered, not the least of which is the Cochlear Implant team’s expectation of families and obligation to patients that a child receiving a cochlear implant must be followed closely for at least 6 months directly by members of this hospital’s team. Beyond the medical and surgical considerations, there is considerable

Ambulatory Documentation

follow along that must be provided to assure proper calibration and consistent use of the device and to assure support during the child's adjustment to using the device and to support progress with development of receptive and expressive communication.

OBSERVATIONS:

Abdulla's mother reports that he is social and he will warm up to and smile with strangers after he becomes more comfortable with them. This certainly proved to be observed. Abdulla arrived seated in his stroller and was soon transferred to a Rifton chair with a tray, providing support for his sitting erect. Abdulla was able to sit upright and engage with toys on his tray. Initially, he seemed rather serious, but after interacting with the clinician for several minutes, he began to smile with her, especially when engaging in a turn taking game with the ball.

Abdulla will reach for toys and clearly made a choice when given two toy options (demonstrated by reaching for and looking at the desired item). When the clinician hid the ball, Abdulla was clearly looking for it. He definitely demonstrated mastery of the concept of object permanence. Furthermore, when one of the clinicians left the room during the session, Abdulla turned his head towards the door to look for her.

His mother indicated that she does not observe Abdulla being responsive to any sounds. She feels he used to show some auditory responsiveness, but no longer does. During the session, he produced vocalizations (primarily vowels) to gain attention and to indicate he wanted a toy that his brother was playing with. Per parent report, he will produce vocalizations to express his wants and needs (such as when he is hungry). Mother reports that approximately one to two months ago, he began producing the vocalization "mama;" however, this is a babble cvcv vocalization that does not reference his mother per se. Abdulla's mother reports that he will wave "bye bye," but this was not observed today.

He preferentially and nearly exclusively used his left hand. He can reach for and pick up and hold onto and throw objects. While not observed in this setting, he is described as rolls and pulling himself along in a "combat crawl" when placed on the floor. He does not push up into a sitting position.

Abdulla becomes excited when novel stimuli are presented to him through the visual modality and he was responsive to hand movements and gestures. She also reports that Abdulla becomes "jealous" when other adults pay attention to his brother Mohamed and he will vocalize, bite and even attempt to hit his brother. At home, Abdulla's mother has observed him attending to and understanding facial expressions (such as for expressing *happy* or *angry*). Before coming to the United States, Abdulla was receiving services from a speech-language pathologist, as well as OT and PT.

PLAN:

Now 35 months of age, Abdulla will be three years of age next month (in February of 2017). While here in Massachusetts, the boys, their mother, and their nanny are residing in Dedham. In their home country of the UAE, Abdulla had been receiving physical therapy (PT) and services from a speech-language therapist with a focus on developing his communication skills . While here in Massachusetts, he is receiving occupational therapy (OT) and PT services through Children's Hospital clinical services currently. He is not enrolled in any Early Intervention programming. Since his mother anticipates that they will continue to reside in Massachusetts for many more months, she was encouraged to contact the Dedham school district and begin the process of enrolling Abdulla in preschool-level special education services for which he should be eligible.

Ambulatory Documentation

His mother impressed as clearly compelled to move forward as quickly as possible with cochlear implantation. If Abdulla is determined to be a candidate for cochlear implantation, auditory stimulation could be feasible after activation of the device, but how well he may be able to attach meaning to sounds delivered through the device is impossible to predict. It would be imperative that Abdulla participates in appropriate supportive , habilitative, and therapeutic services in order to expect any benefit from a cochlear implant and to address his multiple special needs.

After this visit, Abdullah was descriptively presented to the full Cochlear Implant team which met later during this week. Continuing to proceed was approved by the team and the next step in this process of determining "candidacy" is for Abdulla to be seen by one of the surgeons on the Cochlear Implant team.

The following stipulations were also outlined:

- The surgeon will consult with colleagues in neurology and neurosurgery and ultimately weigh in on medical considerations; scheduling single sided cochlear implantation if Abdulla is a "candidate" for surgery.
- Members of his care team at Children's would include Ashleigh Lewkowitz, audiologist and Nicole Salamy, speech-language pathologist. Several visits over the six months following surgery should be anticipated. His mother was given an informational sheet listing at least:
    - Two appointments in the same week about a month after surgery for initial stimulation and mapping of the processor and instruction for the parents about the use, operation, and maintenance of the device.
    - Subsequent monthly programming or mapping sessions with the audiologist.
    - Periodic sessions with the speech-language pathologist during the adjustment phase as the sound is introduced through the device – every two to three weeks.
    - Twice weekly aural habilitation therapy, hopefully delivered in the context of Abdulla's enrollment in preschool level programming for him as a youngster with multiple special educational needs.
    - Consultations between hospital-based clinicians and those providing service and special education with Abdulla.
    - Audiological re-evaluation and speech- language re-evaluation at six months post implantation.

In this department, there is a specialty program (the Augmentative Communication Program) staffed by speech-language pathologists who work with youngsters who do not speak to develop and implement communication strategies. We strongly recommend that Abdulla be referred to and seen by our colleague, Elizabeth Rose, CCC-SLP through ACP and that Nicole Salamy, CCC-SLP join that evaluation appointment as

Ambulatory Documentation

well, here at the Waltham site. Referral to ACP can be made by contacting Lynn Moran (Lynn.Moran@childrens.harvard.edu) who is the intake and scheduling coordinator for that program.

Members of the Cochlear Implant team remain available to the family and to Mohamed's other care providers should there be questions or a desire for further consultation. It was our pleasure to meet him and his brother and their mother. Should there be questions for any member of the Cochlear Implant team, corresponding with the International Office and the Cochlear Implant team's administrative coordinator, Sarah Thomas (Sarah.Thomas@childrens.harvard.edu) is advised.

Boston Children's Hospital

300 Longwood Avenue
Boston, MA 02115

BCH MRN: **500-20-94**
Patient Name: **ALDHAHERI, ABDULLA KHALIFA**
DOB/Age/Sex: 2/18/2014 3 years Male

Admit Date: 6/19/2017
Discharge Date: 6/19/2017

Patient Location: Complex Care Service
Patient Type: Outpatient
Financial #: 6120761426

Ambulatory Documentation

DOCUMENT NAME: Complex Care Visit
SERVICE DATE/TIME: 6/19/2017 16:12 EDT
PERFORM INFORMATION: BAUK MSN,KATHRYN M (6/19/2017 16:21 EDT)
SIGN INFORMATION: GLADER MD,LAURIE J (7/4/2017 12:56 EDT)
RESULT STATUS: Auth (Verified)

Dear Medical Team,

We had the pleasure of seeing your patient Abdulla in the Complex Care Service. He was accompanied to the appointment today by his mother who provided history. Our last visit was on 4/7/17. The purpose of today's visit was comprehensive assessment of medical concerns and coordination of care. [1]

Unifying diagnosis
Abdulla is a 3 year old boy with a history of 25-5/7 weeks' prematurity, intracranial hemorrhage and hydrocephalus s/p VP shunt, who has spastic quadriplegia with superimposition of right hemiplegia, developmental delay, hearing loss s/p cochlear implant, and retinopathy of prematurity s/p laser treatment. [2]

INTERIM HISTORY/CONCERNS FOR TODAY'S VISIT
Since his last visit, Abdulla was doing well but was seen in the ER for vomiting on 6/6/17. He has MRI which was negative for shunt malfunction and the vomiting was felt to be viral. He has since recovered and is now doing well. Mother would like to set up the dental visit discussed at the last visit.

Review of Systems/Historical Overview
Cardiology: No concerns.

Pulmonary: Abdulla has a history of respiratory illnesses and mild asthma previously treated with Flovent 220. MBSS on 1/10/17 identified no aspiration. He was having no issues so mother stopped his flovent and Dr. Martin agreed with that decision on 5/11/17, recommended continuing albuterol as needed and follow up as needed.

ENT/audiology: Abdulla has a history of bilateral hearing loss and auditory dyssynchrony s/p cochlear implant placed on 2/2/17. He had follow up with Dr. Licameli who felt he was dong well and there has been no pain, fever, swelling or other issues. He is followed regularly for mapping and speech therapy in the Deaf and Hard of Hearing Program. He is making progress with more sounds, saying "baba" and "mama" when he wears the hearing aid attached to the implant. He continues to cry when they initially attach the aid but eventually they can distract him and he stops crying. He attempts to pull the aid off and bite it and also pulls off his brother's hearing aid.

FEN/GI: Abdulla is doing well with progressing in his chewing and swallowing skills. He had MBSS on 1/10/17 which identified no aspiration. He had a clinical feeding evaluation on 4/4/17 at which time he was continuing to progress. He now has a good appetite and eats regular soft foods mixed with yogurt and more dissolvable solids like crackers, chips, etc. He does not drink milk or formula, but he eats at least 3 servings of yogurt per day, total of about 500 mL per day which was their goal from nutrition on 12/1/16. He has no abdominal pain, vomiting, diarrhea or constipation. He swa nutrition on 5/4/17 and his weight was

Problem List/Past Medical History
- Ongoing
  - Acute vomiting
  - Bronchopulmonary dysplasia
  - Childhood asthma
  - Cochlear implant in situ
  - Developmental delay
  - Dysarthria
  - Feeding difficulties and mismanagement
  - Hearing loss
  - Mixed receptive-expressive language disorder
  - Sensorineural hearing loss, bilateral
  - Spastic quadriplegic cerebral palsy
  - Wheeze
- Historical
  - Speech delay

Medications
- aerochamber with medium mask, See Instructions
- albuterol 1.25 mg/3 mL (0.042%) inhalation solution, 1.25 mg, INH, Q4hr, PRN
- Flovent HFA 110 mcg/inh inhalation aerosol, 2 puff, INH, daily
- Nebulizer machine, See Instructions
- Vitamin D3 400 intl units/mL oral liquid, 400 unit = 1 mL, PO, daily

Allergies
No known allergies

Social History
- Assistive Technology Right - Audiology
  - Hearing Device Cochlear Implant. Manufacturer Cochlear Americas. Model Internal: CI522; External: CP950 & CP910. Serial Number Internal: 1020170202749. Date Fit Surgery: 2/2/2017; Activation: 2/21/2017. Battery Size 675. Rechargeable Battery Lithium ion (CP910 only).

Ambulatory Documentation

good, but they started Duocal because his brother was gaining slowly and they were attempting to encourage both to eat the same foods for simplicity.

Neurology: Abdulla has a history of IVH and hydrocephalus with VP shunt. Dr. Warf with neurosurgery saw him on 12/12/16 and diagnosed ventricle syndrome, reset his shunt. He had repeat MRI on 12/28 for vent check and follow up with Dr. Warf and Ashley Birch, NP. The shunt was thought to be at a good level with no other concerns reported. No symptoms of shunt malfunction and family is monitoring for those signs. There is no past history of overt seizure activity. 12/5/16 EEG showed no seizures. Dr. Coulter saw him 3/13/17 and he was doing well, follow up planned in July.

Genetics: In the extended family there is a cousin who has cerebral palsy on the basis of hypoxic ischemia in the neonatal period and who also has a seizure disorder. There was a pregnancy on the maternal side of the family that terminated at 9 months secondary to nuchal cord. Abdulla's parents are not consanguineous.

Renal/Urology: There is no history or concern about Abdulla's kidney function. There have been no urinary tract infections nor any evidence of urinary retention.

Musculoskeletal: Abdulla has spastic quadriplegia with superimposed right hemiplegia. Abdulla has been seen by Dr. Fogelman of Physiatry and had Botox/phenol injections on 11/17/16 which was very helpful with spasticity. Repeat injections are planned for August prior to traveling home. He also has AFOs and is able to crawl independently and use his walker, starting to pull up but refuses to do so when wearing the braces. He continues to work on OT and PT through a therapist at school. They are very pleased with his progress. He has follow up with Dr. Fogelman planned on 9/1/17.

Previous X-rays of the spine were negative for any evidence of early scoliosis and his hip films revealed well-formed femoral heads and slight uncovering of the right head that resolved in abduction.

Endocrine: No history of fracture. Vitamin D level 29 on 1/24/17 and he has since started 400 IU once daily. No thyroid concerns. No problems with glucose regulation.

Ophthalmology: Abdulla is status post treatment for retinopathy of prematurity. He saw Dr. Alkharashi on 3/1/17 who noted that he is myopic and has anisometropia as well as well-controlled exotropia. No surgical intervention was recommended but he was to wear glasses full time. Mother reports that it is incredibly difficult to get him to wear his glasses and they were told they did not need to force it, so he has not been wearing them. Follow up scheduled 8/30/17.

Dermatology: Mother has noticed some dark skin on her ankle under the AFO. There is occasional redness in that area but the redness usually resolves.

Dental: He was seen in the Dental clinic where they reviewed hygiene, recommended brushing twice daily, follow up in 3 months. This appointment has not yet been scheduled.

Hematology: No identified concerns.

Infectious disease: No identified concerns.

Developmental: He started school in April and has been doing very well. He receives services including OT, PT and Speech and is making developmental progress. He is now pulling up to stand but will not pull up when wearing his AFOs. His PT suggested that a hinged design might be better than the solid AFOs he has currently. He is also babbling

Basic Social History

Living Arrangement Parent(s)/Guardian. Legal Guardian: Parent. Lives With: Mother, Father, Brother, nanny. Language Spoken at Home: English and Arabic.

Home/Environment

Living situation: Home with assistance. Devices or Anatomic Adaptations: Ventriculoperitoneal shunt, Glasses, Hearing aides. Home equipment: Adaptive stroller, Ankle foot orthoses (AFO's).

Family History

Developmental delay: Brother.
Seizures: Cousin.

Ambulatory Documentation

more and says mama and baba when he has the hearing aid connected to his cochlear implant but only grunts when he is not wearing it.

Further 12 point review of systems was non-contributory. [3]

Provider List
Physiatry: Dr. Fogelman
Neurology: Dr. Coulter
Neurosurgery: Dr. Warf
ORL: Dr. Kenna [4]

Physical Exam

Vitals & Measurements
T: 36.9 °C **HR:** 122 (Monitored) **BP:** 88/60 **SpO2:** 97%
WT: 13.7 kg
General: He is awake, alert and interactive in no acute distress. He is smiling and playful during today's visit.
Skin: No rashes or lesions.
HEENT: Dolicohcephalic. He has a cochlear implant on right temporal area without evidence of pain, swelling, redness or other abnormality. PERRL, sclera clear. Gaze appears conjugate. No nystagmus. Moist mucus membranes, normal posterior oropharynx. TMs pearly gray without effusion.
Neck: Supple, good head control. No LAD.
COR: RRR, no murmur.
Chest: Lungs CTA, no rhonchi or wheezes. No cough.
Abd: Soft, nontender, nondistended. No HSM. Bs x4.
Musculoskeletal/Spine: He has central hypotonia which is improving, able to sit unsupported in his stroller. He has increased tone in the right leg greater than left. Increased tone in right arm, normal to very mild increased tone in left arm. Bilateral dorsiflexion to just short of 90 degrees and his is not wearing AFOs today. Spine appears straight.
Neurologic: DTRs 2+ and equal, CN 2-10 intact grossly.
Developmental: He vocalized and made some babbling sounds as well as grunting during the exam. He reaches and plays with medical equipment and follows some commands.

Summary:
Abdulla is a 3 year old boy with a history of 25-5/7 weeks' prematurity, intracranial hemorrhage and hydrocephalus s/p VP shunt, who has spastic quadriplegia with superimposition of right hemiplegia, developmental delay, hearing loss s/p cochlear implant, and retinopathy of prematurity s/p laser treatment.

Assessment/Plan
1. Spastic quadriplegic cerebral palsy
   He will be undergoing repeat Botox injections in the late summer and I spoke with Dr. Fogelman who does not need to see him prior to injections but will follow up as planned on 9/1/17.
   His outside PT recommended a hinged AFO and I discussed that with Dr. Fogelman who provided an order.
2. Cochlear implant in situ
   Continue to follow up with Audiology as planned.
   Because of the implant he needs PCV 13 x2 doses and PCV 23 at least 8 weeks apart. We administered the PCV 13 and he should have the next dose of PCV 13 on/after August 14

3. He is in need of routine dental cleaning and evaluation and I will again request that visit.

Ambulatory Documentation

Care Coordination
Referrals Requested: Dental Clinic

CCS follow-up: 2-3 months

Studies/Labs Requested: none

Medications Prescribed or Changed: PCV 13

Communication: Amy Cohen, BCH International Center

Thank you for allowing me to participate in Abdulla's care.
Sincerely,
Kathryn Bauk, MSN, RN, CPNP
Complex Care Service

Today's visit was 35 minutes in duration and greater than 50% of time was dedicated to counseling, education and coordination of care. This patient was discussed with and seen by Dr. Glader who was the attending physician at the time of this visit.

I provided direct, on-site supervision for Abdulla's visit. I reviewed the interval history, review of systems, and findings as outlined above, and supervised the development of the management plan. I have reviewed and edited the above note.

Laurie Glader, MD
Attending Pediatrician
Complex Care Service

[1]CCS Return Visit; BAUK MSN, KATHRYN M 04/07/2017 12:31 EDT
[2]CCS Return Visit; BAUK MSN, KATHRYN M 04/07/2017 12:31 EDT
[3]CCS Return Visit; BAUK MSN, KATHRYN M 04/07/2017 12:31 EDT
[4]CCS Return Visit; BAUK MSN, KATHRYN M 04/07/2017 12:31 EDT

Boston Children's Hospital
300 Longwood Avenue
Boston, MA 02115

BCH MRN: **500-20-94**
Patient Name: **ALDHAHERI, ABDULLA KHALIFA**
DOB/Age/Sex: 2/18/2014 3 years Male

Admit Date: 4/7/2017
Discharge Date: 4/7/2017

Patient Location: Complex Care Service
Patient Type: Outpatient
Financial #: 6120179904

Ambulatory Documentation

DOCUMENT NAME: Complex Care Visit
SERVICE DATE/TIME: 4/7/2017 12:31 EDT
PERFORM INFORMATION: BAUK MSN,KATHRYN M (4/7/2017 12:53 EDT)
SIGN INFORMATION: BAUK MSN,KATHRYN M (4/18/2017 08:06 EDT); EMARA MD, NORAH (4/14/2017 17:01 EDT)
RESULT STATUS: Auth (Verified)

Dear Medical Team,

I had the pleasure of seeing your patient Abdulla in the Complex Care Service. He was accompanied to the appointment today by his mother who provided history. Our last visit was on 12/30/16. The purpose of today's visit was comprehensive assessment of medical concerns and coordination of care.

Unifying diagnosis
Abdulla is a 3 year old boy with a history of 25-5/7 weeks' prematurity, intracranial hemorrhage and hydrocephalus s/p VP shunt, who has spastic quadriplegia with superimposition of right hemiplegia, developmental delay, hearing loss s/p cochlear implant, and retinopathy of prematurity s/p laser treatment. [1]

INTERIM HISTORY/CONCERNS FOR TODAY'S VISIT
Since his last visit, Abdulla received a right cochlear implant on 2/2/2017. He has been making progress in language and motor development. They have no new medical concerns.

Review of Systems/Historical Overview
Cardiology: No concerns.

Pulmonary: Abdulla has regular respiratory illnesses and uses albuterol which is helpful. He was seen by Dr. Martin on 11/9/16 who felt he had mild asthma and recommended Flovent 220 mcg QD. Dr. Martin also recommended MBSS on 1/10/17 which identified no aspiration. He is not coughing, no oxygen requirement. He does not have pulmonary follow up scheduled.

ENT/audiology: Abdulla has a history of bilateral hearing loss and auditory dyssynchrony. He had the cochlear implant placed on 2/2/17 and they plan to be in the US for 6 months after that surgery. He had follow up with Dr. Licameli who felt he was dong well and there has been no pain, fever, swelling or other issues. He is followed regularly for mapping and speech therapy in the Deaf and Hard of Hearing Program. He is making progress with more sounds, saying "baba" now which is very exciting for his family.

FEN/GI: Abdulla is doing well with progressing in his chewing and swallowing skills. He had MBSS on 1/10/17 which identified no aspiration. He had a clinical feeding evaluation on 4/4/17 at which time he was continuing to progress. He now has a good appetite and eats regular soft foods mixed with yogurt and some dissolvable solids like crackers. He does not drink milk or formula, but he eats at least 3 servings of yogurt per day, total of about 500 mL per day which was their goal from nutrition on 12/1/16. He has no abdominal pain, vomiting, diarrhea or constipation.

Problem List/Past Medical History
Ongoing
- Bronchopulmonary dysplasia
- Childhood asthma
- Cochlear implant in situ
- Developmental delay
- Dysarthria
- Feeding difficulties and mismanagement
- Hearing loss
- Mixed receptive-expressive language disorder
- Sensorineural hearing loss, bilateral
- Spastic quadriplegic cerebral palsy
- Wheeze

Historical
- Speech delay

Medications
- aerochamber with medium mask, See Instructions
- albuterol 1.25 mg/3 mL (0.042%) inhalation solution, 1.25 mg, INH, Q4hr, PRN
- Flovent HFA 110 mcg/inh inhalation aerosol, 2 puff, INH, daily
- Nebulizer machine, See Instructions
- Vitamin D3 400 intl units/mL oral liquid, 400 unit = 1 mL, PO, daily

Allergies
No known allergies

Immunization Status
Immunization record is not legible so it is unclear if he is up to date

Social History
Assistive Technology Right - Audiology
- Hearing Device Cochlear Implant. Manufacturer Cochlear Americas. Model Internal: CI522; External: CP950 & CP910. Serial Number Internal:

Ambulatory Documentation

Neurology: Abdulla has a history of IVH and hydrocephalus with VP shunt. Dr. Warf with neurosurgery saw him on 12/12/16 and diagnosed ventricle syndrome, reset his shunt. He had repeat MRI on 12/28 for vent check and follow up with Dr. Warf and Ashley Birch, NP. The shunt iwa thought to be at a good level with no other concerns reported. No symptoms of shunt malfunction and family is monitoring for those signs.

There is no past history of overt seizure activity. 12/5/16 EEG showed no seizures, recommended follow up in thee months. Dr. Coulter saw him 3/13/17 and he was doing well, follow up planned in July.

Genetics: In the extended family there is a cousin who has cerebral palsy on the basis of hypoxic ischemia in the neonatal period and who also has a seizure disorder. There was a pregnancy on the maternal side of the family that terminated at 9 months secondary to nuchal cord. Abdulla's parents are not consanguineous.

Renal/Urology: There is no history or concern about Abdulla's kidney function. There have been no urinary tract infections nor any evidence of urinary retention.

Musculoskeletal: Abdulla has spastic quadriplegia with superimposed right hemiplegia. Abdulla has been seen by Dr. Fogelman of Physiatry and had Botox/phenol injections on 11/17/16 which was very helpful with spasticity. Repeat injections are planned for July prior to traveling home. He also has AFOs and is able to crawl and use his walker in the braces. He continues to work on OT and PT through a therapist at home and will be transitioning these services to school in the near future. They are very pleased with his progress. He has follow up with Dr. Fogelman planned on 9/1/17.

Previous X-rays of the spine were negative for any evidence of early scoliosis and his hip films revealed well-formed femoral heads and slight uncovering of the right head that resolved in abduction.

Endocrine: No history of fracture. Vitamin D level 29 on 1/24/17 and he has since started 400 IU once daily. No thyroid concerns. No problems with glucose regulation.

Ophthalmology: Abdulla is status post treatment for retinopathy of prematurity. He saw Dr. Alkharashi on 3/1/17 who noted that he is myopic and has anisometropia as well as well-controlled exotropia. No surgical intervention was recommended but he was to wear glasses full time. Mother reports that it is incredibly difficult to get him to wear his glasses and they were told they did not need to force it, so he has not been wearing them.

Dermatology: Mother has noticed some dark skin on her ankle under the AFO. There is occasional redness in that area but the redness usually resolves.

Dental: He was seen in the Dental clinic where they reviewed hygiene, recommended brushing twice daily, follow up in 3 months. This appointment has not yet been scheduled.

Hematology: No identified concerns.

Infectious disease: No identified concerns.

Further 12 point review of systems was non-contributory. [2]

Provider List
Physiatry: Dr. Fogelman
Neurology: Dr. Coulter

1020170202749. Date Fit Surgery: 2/2/2017; Activation: 2/21/2017. Battery Size 675. Rechargeable Battery Lithium ion (CP910 only).

Basic Social History
Living Arrangement Parent(s)/Guardian. Legal Guardian: Parent. Lives With: Mother, Father, Brother, nanny. Language Spoken at Home: English and Arabic.

Home/Environment
Living situation: Home with assistance. Devices or Anatomic Adaptations: Ventriculoperitoneal shunt, Glasses, Hearing aides. Home equipment: Adaptive stroller, Ankle foot orthoses (AFO's).

Family History
Developmental delay: Brother.
Seizures: Cousin.

Ambulatory Documentation

Neurosurgery: Dr. Warf
ORL: Dr. Kenna [3]

Physical Exam

Vitals & Measurements
T: 36.5 °C **HR:** 115 (Monitored) **BP:** 82/56 **SpO2:** 97%
HT: 89.5 cm **WT:** 13.2 kg **BMI:** 16.5

General: He is awake, alert and interactive in no acute distress.
Skin: He has redness without break in the skin on the left medial malleolus as well as hyperpigmentation on right medial malleolus from rubbing from his AFOs. No other rashes or lesions.
HEENT: Dolicohcephalic. He has a cochlear implant on right temporal area without evidence of pain, swelling, redness or other abnormality. PERRL, sclera clear. Gaze appears conjugate. No nystagmus. Moist mucus membranes, normal posterior oropharynx. TMs pearly gray without effusion.
Neck: Supple, good head control. No LAD.
COR: RRR, no murmur.
Chest: Lungs CTA, no rhonchi or wheezes. No cough.
Abd: Soft, nontender, nondistended. No HSM. Bs x4.
Musculoskeletal/Spine: He has central hypotonia but is able to sit unsupported and is stronger since the last visit. He has increased tone in the right leg greater than left. Increased tone in right arm, normal tone in left arm. Bilateral dorsiflexion to 90 degrees in his braces. Spine appears straight.
Neurologic: DTRs 2+ and equal, CN 2-10 intact grossly. Babinski upgoing on the right, downgoing on the left.
Developmental: He vocalized but does not actually babble during the exam. He is expressive and has good understanding, follows command to give High-5.

Summary:
Abdulla is a 3 year old boy with a history of 25-5/7 weeks' prematurity, intracranial hemorrhage and hydrocephalus s/p VP shunt, who has spastic quadriplegia with superimposition of right hemiplegia, developmental delay, hearing loss s/p cochlear implant, and retinopathy of prematurity s/p laser treatment. He is doing very well and making developmental progress. He does have an area of redness under the AFO which would benefit from modification to the brace.

Assessment/Plan
1. Spastic quadriplegic cerebral palsy
   Follow up as planned with Dr. Fogelman including repeat Botox injections before returning home in September
   Evaluation of AFOs at NOPCO given mild skin breakdown under the braces
2. Developmental delay
   Continue current therapies at home including OT and PT
   He will be starting school shortly and should receive OT, PT and Speech Therapy
3. Hearing loss
   Continue plans as recommended by ORL and Audiology
4. Cochlear implant in situ
   Continue plans as recommended by ORL and Audiology
5. Bronchopulmonary dysplasia
   He has been doing well but is due for follow up with Pulmonology. We will help schedule this.
6. Feeding difficulties and mismanagement
   He is making progress with oral feeds but has not been seen by nutrition recently. We will request reevaluation to discuss healthy diet.

Ambulatory Documentation

He has had borderline low Vitamin D and been on supplemental 400 IU daily. We will recheck this level and family would like to wait until Botox appointment which I agreed to do.

7. Immunization due
His immunization record is not legible, but he is likely due for at least his 3 year old immunizations. We will request immunization visit in CHPCC to review and provide necessary immunizations.

8. He is in need of routine dental care including evaluation and cleaning. We will request follow up visit with the Dental clinic.

Care Coordination
Referrals Requested: Pulmonary, Nutrition, NOPCO, Dental, CHPCC
CCS follow-up: 2-3 months
Studies/Labs Requested: Vitamin D
Medications Prescribed or Changed: none
Communication: Amy Cohen, BCH International Center

Thank you for allowing me to participate in Abdulla's care.
Sincerely,
Kathryn Bauk, MSN, RN, CPNP
Complex Care Service

Today's visit was 40 minutes in duration and greater than 50% of time was dedicated to counseling, education and coordination of care. This patient was discussed with Dr. Emara who was the attending physician at the time of this visit.

Attending Addendum:
I provided direct supervision for this patient's CCS visit. I reviewed the interval history, review of systems, and findings as outlined above, and supervised the development of the management plan. I have reviewed and agree with the documentation with these additions/exceptions: none

Norah Emara, MD
Attending Pediatrician
Complex Care Service
Department of Medicine
Boston Children’s Hospital

[1]CCS Return Visit; BAUK MSN, KATHRYN M 12/30/2016 14:05 EST
[2]CCS Return Visit; BAUK MSN, KATHRYN M 12/30/2016 14:05 EST
[3]CCS Return Visit; BAUK MSN, KATHRYN M 12/30/2016 14:05 EST

Boston Children's Hospital

300 Longwood Avenue
Boston, MA 02115

BCH MRN: **500-20-94**
Patient Name: **ALDHAHERI, ABDULLA KHALIFA**
DOB/Age/Sex: 2/18/2014 3 years Male

Admit Date: 12/30/2016
Discharge Date: 12/30/2016

Patient Location: Complex Care Service
Patient Type: Outpatient
Financial #: 6119782818

Ambulatory Documentation

DOCUMENT NAME: Complex Care Visit
SERVICE DATE/TIME: 12/30/2016 14:05 EST
PERFORM INFORMATION: BAUK MSN,KATHRYN M (12/30/2016 14:22 EST)
SIGN INFORMATION: BAUK MSN,KATHRYN M (1/9/2017 13:58 EST); COX MD, JOANNE E (1/9/2017 10:44 EST)
RESULT STATUS: Auth (Verified)

Dear Colleagues,

I had the pleasure of seeing your patient Abdulla in the Complex Care Service. He was accompanied to the appointment today by his mother and nanny. History was from mother. An Arabic interpreter was offered but declined as mother is very proficient in English. Our last visit was on 9/29/16 with Dr. Glader. The purpose of today's visit was comprehensive assessment of medical concerns and coordination of care.

Unifying diagnosis
Abdulla is a 2 year 10 month old boy with a history of 25-5/7 weeks' prematurity, intracranial hemorrhage and hydrocephalus s/p VP shunt, who has spastic quadriplegia with superimposition of right hemiplegia, developmental delay, hearing loss and retinopathy of prematurity s/p laser treatment.

INTERIM HISTORY/CONCERNS FOR TODAY'S VISIT
Since the last visit, he has been doing well. He was seen in the ER once because he was vomiting and acted sleepy. Mother was concerned about the shunt but he improved with Tylenol and shunt evaluation was normal. He was discharged home without further problems.

He had Botox and phenol injections on 11/17/16 and is wearing braces which have been helpful. He is also scheduled to see the cochlear implant team on 1/3/17 and they are very anxious to move forward with that.

Review of Systems/Historical Overview
Cardiology: No concerns.

Pulmonary: Abdulla seems susceptible to regular respiratory illnesses and as soon as he develops symptoms he uses albuterol. He was seen by Dr. Martin on 11/9/16 who felt he had mild asthma and recommended Flovent 220 mcg QD. Mother reports this seems to help somewhat. He is not coughing, no oxygen requirement. Dr. Martin also recommended MBSS which is scheduled on 1/10/17.

ENT/audiology: Abdulla had an ABR early on that revealed a markedly abnormal response however with repeat behavioral testing it sounds as if he was felt to be somewhat responsive. His course has waxed and waned. He was given hearing aids but subsequently was felt to improve and has not been using aids. He saw Dr. Kenna on 11/7/16 who recommended cochlear implant team evaluations and had education on cochlear implant with audiology on 11/29/16. The cochlear implant team visits are scheduled on 1/3/17 and family would very much like to proceed with surgery since they will plan to be in the US for 6 months after that surgery.

Problem List/Past Medical History
Ongoing
- Bronchopulmonary dysplasia
- Childhood asthma
- Developmental delay
- Hearing loss
- Spastic quadriplegic cerebral palsy
- Speech delay
- Wheeze

Historical
- No qualifying data

Medications
- aerochamber with medium mask, See Instructions
- albuterol 1.25 mg/3 mL (0.042%) inhalation solution, 1.25 mg, INH, Q4hr, PRN, **Not taking**
- Flovent HFA 110 mcg/inh inhalation aerosol, 2 puff, INH, daily, **Not taking**
- Nebulizer machine, See Instructions

Allergies
No known allergies

Immunization Status
Up to date including influenza vaccine 2016-2017 season (received 2 vaccinations last year)

Social History
Basic Social History
- Living Arrangement Parent(s)/Guardian. Legal Guardian: Parent. Lives With: Mother, Father, Brother, nanny. Language Spoken at Home: English and Arabic.

Home/Environment
- Living situation: Home with assistance. Devices or Anatomic Adaptations: Ventriculoperitoneal shunt, Glasses, Hearing aides. Home equipment:

Ambulatory Documentation

FEN/GI: Abdulla over time has made very nice progress with his chewing and swallowing skills. His parents report that they cut table food up into small bites but that they do not any longer have to puree or mash foods and he is able to lateralize his tongue, moving food from side to side. He does not cough choke or gag while drinking or eating if food is prepared appropriately for him. His appetite is good, now improved from in the past. He eats all types of soft foods, good variety. He does not drink milk but is eating yogurt, total of about 500 mL per day which was their goal from nutrition on 12/1/16. He has no abdominal pain, vomiting, diarrhea or constipation.

Neurology: There is no past history of overt seizure activity. 12/5/16 EEG showed no seizures, recommended follow up in thee months. Dr. Coulter will see him on 3/13/17. Dr. Warf with neurosuregry saw him on 12/12/16 and diagnosed ventricle syndrome, reset his shunt. He had repeat MRI on 12/28 for vent check and the shunt is thought to be at a good level currently. No symptoms of shunt malfunction and family is monitoring for those signs.

Genetics: In the extended family there is a cousin who has cerebral palsy on the basis of hypoxic ischemia in the neonatal period and who also has a seizure disorder. There was a pregnancy on the maternal side of the family that terminated at 9 months secondary to nuchal cord. Abdulla's parents are not consanguineous.

Renal/Urology: There is no history or concern about Abdulla's kidney function. There have been no urinary tract infections nor any evidence of urinary retention.

Musculoskeletal: Abdulla has been seen by Dr. Fogelman of Physiatry who has prescribed bilateral solid AFOs which he recently recieved. This has been helpful since the Botox injections on 11/17/16. Follow up with Dr. Fogelman and Susan Keuker on 10/19/16, follow up planned 1/18/17. Abdulla was seen in the equipment clinic for an adaptive stroller as well as for PT, OT and speech therapies which he continues to received. Family is considering additional private therapies at home as well. At this point there is no indication for systemic or focal tone management but he will be observed. X-rays of the spine were negative for any evidence of early scoliosis and his hip films revealed well-formed femoral heads and slight uncovering of the right head that resolved in abduction.

Endocrine: No history of fracture. No thyroid concerns. No problems with glucose regulation.

Ophthalmology: Abdulla is status post treatment for retinopathy of prematurity. His parents report that he has good visual acuity. He was seen on 9/20/16 and recommended glasses, consideration of patching, follow up in 6 months. This is scheduled for 3/1/17. He continues to have mild exotropia of the right eye but this is stable.

Dental: He was seen in the Dental clinic where they reviewed hygeine, recommended brushing twice daily, follow up in 3 months.

Hematology: No identified concerns.

Infectious disease: No identified concerns.

Further 12 point review of systems was non-contributory.

Provider List
Physiatry: Dr. Fogelman
Neurology: Dr. Coulter
Neurosurgery: Dr. Warf
ORL: Dr. Kenna

Adaptive stroller, Ankle foot orthoses (AFO's).

Family History
Developmental delay: Brother.
Seizures: Cousin.

Ambulatory Documentation

Physical Exam

Vitals & Measurements
HR: 117 (Monitored) **SpO2:** 98%
HT: 92.0 cm **WT:** 13.30 kg **BMI:** 15.7
General: He is awake, alert and interactive in no acute distress.
Skin: No rashes or lesions.
HEENT: Dolicohcephalic. PERRL, sclera clear. Gaze appears conjugate. No nystagmus. Moist mucus membranes, normal posterior oropharynx. TMs pearly gray without effusion.
Neck: Supple, good head control. No LAD.
COR: RRR, no murmur.
Chest: Lungs CTA, no rhonchi or wheezes. No cough.
Abd: Soft, nontender, nondistended. No HSM. Bs x4.
Musculoskeletal/Spine: He has central hypotonia but is able to sit unsupported for about a minute during the exam. He has increased tone in the extremities, right greater than left. There is tightness in the lower extremities as well, but able to get dorsiflexion to 90 degrees. Spine appears straight.
Neurologic: DTRs 2+ and equal, CN 2-10 intact grossly. He does not use any words or babble during the exam but vocalizes multiple times.

Summary:
Abdulla is a 2 year 10 month old boy with a history of 25-5/7 weeks' prematurity, intracranial hemorrhage and hydrocephalus s/p VP shunt, who has spastic quadriplegia with superimposition of right hemiplegia, global developmental delay, BPD, hearing loss and retinopathy of prematurity s/p laser treatment.

Assessment/Plan
1. Spastic quadriplegic cerebral palsy
   Follow up with physiatry as planned
   Continue use of AFOs and PT
   Vitamin D with next labs given non-weightbearing status and risk for bone issues
2. Bronchopulmonary dysplasia
   Continue albuterol as needed
   Follow up with pulmonology as needed
3. Developmental delay
   Continue OT, PT and Speech Therapy
   Augmentative Communications Program is scheduled on 1/3/17
4. Hearing loss
   He is scheduled to see the Cochlear Implant team on 1/3/17
5. Feeding difficulties and mismanagement
   MBSS as scheduled on 1/10/17
   Evaluation with Feeding Team as previously recommended

Care Coordination
Referrals Requested: Feeding Team
CCS follow-up: 3 months
Studies/Labs Requested: Vitamin D 25-OH
Medications Prescribed or Changed: none
Communication: Amy Cohen, BCH International Center

Thank you for allowing me to participate in Abdulla's care.
Sincerely,
Kathryn Bauk, MSN, RN, CPNP
Complex Care Service

Today's visit was 45 minutes in duration and greater than 50% of time was dedicated to

Ambulatory Documentation

counseling, education and coordination of care. This patient was discussed with and seen by Dr. Cox who was the attending physician at the time of this visit.

Abdulla is an almost 3 year old twin with h/o extreme prematurity, intracranial hemorrhage and hydrocephalus with VP shunt. He has spastic quadriplegia will be evaluted in the CP center. He has BPD which is stable. He will continue OT, PT and speech theryap for developmental delay and has a scheudle augmentative communicatcation appointment. He will also be evaluated for a coclhear implant. A feeding team evaluation is pending.
I participated in all components of his care.

Boston Children's Hospital

300 Longwood Avenue
Boston, MA 02115

BCH MRN: **500-20-94**
Patient Name: **ALDHAHERI, ABDULLA KHALIFA**
DOB/Age/Sex: 2/18/2014 3 years Male

Admit Date: 2/23/2017
Discharge Date: 2/23/2017

Patient Location: DHHP Waltham
Patient Type: Outpatient
Financial #: 6120480491

Ambulatory Documentation

DOCUMENT NAME:	Communication Enhancement Visit
SERVICE DATE/TIME:	2/23/2017 17:08 EST
PERFORM INFORMATION:	SALAMY CCC-SLP,NICOLE (2/23/2017 17:09 EST)
SIGN INFORMATION:	SALAMY CCC-SLP,NICOLE (2/23/2017 17:09 EST)
RESULT STATUS:	Auth (Verified)

Abdulla AlDhaheri was here today with his mother, brother and uncle. He recently received a right sided cochlear implant and was activated two days ago. The family was here today for an initial meeting/therapy appointment post activation. He was seated in a traditional stroller; mother reports that his customized stroller was left at home, but she will bring it back for the next session. Sue Russell, occupational therapist, also joined for much of the session to work on his brother's chair.

Per report, Abdulla's CI processor is set very low at the current time. Mother reports that he is not responding to any loud noises in the environment. During the session today, Abdulla enjoyed engaging with the clinician while they played with a ball, drum and car track. He smiled and appeared to be looking for objects when they fell to the ground indicating he wanted to continue playing. When a person left the room, he did seem to notice and waved his hand ('bye bye') appropriately. Basic listening and communication skills will continue to be addressed in future sessions. He has several mapping appointments scheduled in the coming weeks.

Ambulatory Documentation

DOCUMENT NAME: Communication Enhancement Visit
SERVICE DATE/TIME: 2/7/2017 10:13 EST
PERFORM INFORMATION: GROSSMAN CCC-SLP,MIA (3/3/2017 10:14 EST)
SIGN INFORMATION: GROSSMAN CCC-SLP,MIA (3/3/2017 16:24 EST)
RESULT STATUS: Auth (Verified)

Reason for Visit
Oral phase dysphagia

Session Narrative/HPI

CLINICAL FEEDING EVALUATION
FEEDING AND SWALLOWING PROGRAM

PRESENTING INFORMATION:
Abdulla Aldhaheri is a 2-year, 11-month-old boy with a diagnosis of cerebral palsy with right hemiplegia who was seen today for a clinical assessment of his oral feeding and swallowing skills. He was accompanied to today's appointment by his mother and nanny, who served as informants. His brother, Mohamed was also present for today's visit. Abdulla was referred for today's study as follow up to a recent Modified Barium Swallow (MBS) study completed on 1/10/17 that revealed, "*oral phase dysphagia characterized by reduced oral tone and oral hypersensitivity, as well as reports of impaired chewing*."

To briefly review, Abdulla presents with a complex medical history significant for a diagnosis of cerebral palsy with right hemiplegia and spastic quadriplegia, and global developmental delay. He is 1 of 2 surviving of a set of triplets born at 25 5/7 weeks gestation in the UAE. He required a 4 month NICU stay complicated by need for mechanical ventilation for ~6 weeks, followed by CPAP requirement. At 40 weeks gestation, Abdulla suffered from intracranial hemorrhage, resulting in hydrocephalus and placement of VP shunt. Abdulla also presents with a diagnosis of bilateral auditory neuropathy. He underwent right cochlear implantation on 2/2/17 and is reportedly recovering well from this procedure. There are no concerns regarding stooling, vomiting or reflux. No recent changes to medication or allergies reported.

Abdulla is a full oral feeder. He drinks water, which is passively delivered from a small solo cup (~1 oz. cup). Abdulla refuses milk. He occasionally accepts juice via straw with assistance. Abdulla has begun to attempt to self-feed. He accepts pieces of banana, small pieces of bread, fruits, and

Problem List/Past Medical History
Ongoing
- Bronchopulmonary dysplasia
- Childhood asthma
- Cochlear implant in situ
- Developmental delay
- Feeding difficulties and mismanagement
- Hearing loss
- Sensorineural hearing loss, bilateral
- Spastic quadriplegic cerebral palsy
- Speech delay
- Wheeze

Historical
- No qualifying data

Medications
- aerochamber with medium mask, See Instructions
- albuterol 1.25 mg/3 mL (0.042%) inhalation solution, 1.25 mg, INH, Q4hr, PRN
- Flovent HFA 110 mcg/inh inhalation aerosol, 2 puff, INH, daily
- Nebulizer machine, See Instructions
- Vitamin D3 400 intl units/mL oral liquid, 400 unit = 1 mL, PO, daily

Allergies
No known allergies

Social History
Assistive Technology Right - Audiology
- Hearing Device Cochlear Implant. Manufacturer Cochlear Americas. Model Internal: CI522; External: CP950 & CP910. Serial Number Internal: 1020170202749. Date Fit Surgery: 2/2/2017; Activation: 2/21/2017. Battery Size 675. Rechargeable Battery Lithium ion (CP910 only).

Basic Social History
- Living Arrangement Parent(s)/Guardian. Legal Guardian: Parent. Lives With:

Ambulatory Documentation

blended foods. Abdulla is seated in a booster seat for feeding. Mealtimes last 5-10 minutes. There is no reported coughing or choking with feeding, though concerns were noted regarding Abdulla's delayed chewing skills. Since arriving in the United States in September, Abdulla's feeding skills have reportedly improved. He now tolerates tooth brushing. Abdulla's typical feeding schedule was provided by his caregivers as follows:

8am- Breakfast- Infant rice cereal made with water, 4 oz. water via open cup
11am- Snack- soft bread, water
12/1p- Lunch- Rice with chicken or meat and yogurt, water via open cup
Nap
4/5p- Snack- fruit yogurt (2 containers)
7:30/8p- Dinner- Rice with chicken or meat and yogurt, water via open cup
8:30/9- Bedtime

Abdulla receives physical therapy and occupational therapy here at Boston Children's Hospital and will reportedly transition to school based services in April through the Dedham Public Schools.

ASSESSMENT:
Abdulla was seated upright in a Rifton chair with back and foot support for today's assessment. An oral mechanism examination revealed reduced oral muscle tone with an slightly open mouth posture noted at rest. Secretion management was adequate. Lingual range of motion was intact. Abdulla was offered infant rice cereal via spoon, Veggie Straws, Mum-mum in a mesh feeder bag, and water via small open cup and flip-top straw cup.

Abdulla was offered puree via spoon and pouch. He spontaneously opened his mouth to the spoon and demonstrated functional spoon-feeding skills characterized by adequate lip closure and stripping of the bolus from the spoon. He suckled purees posteriorly. Abdulla was introduced to puree via pouch. He readily accepted the spout of the pouch and allowed the clinician to express a small bite of puree into his mouth. Abdulla demonstrated adequate lip closure around the pouch to avoid anterior food loss. With repeated exposure, Abdulla began to independently extract from the pouch. He leaned toward the pouch or reached to the pouch to request more.

With water via open cup, Abdulla stabilized the rim of the cup with his lower lip and passively accepted 2-3 consecutive sips. He demonstrated adequate bolus control with limited anterior liquid loss. Abdulla was introduced to water via flip-top straw cup. He accepted the straw intraorally and allowed the clinician to passively deliver single sips of water into his mouth. With repeated exposure, Abdulla eventually began to independently

Mother, Father, Brother, nanny.
Language Spoken at Home: English and Arabic.

Home/Environment

Living situation: Home with assistance.
Devices or Anatomic Adaptations: Ventriculoperitoneal shunt, Glasses, Hearing aides. Home equipment: Adaptive stroller, Ankle foot orthoses (AFO's).

Family History

Developmental delay: Brother.
Seizures: Cousin.

Ambulatory Documentation

extract consecutive sips of water via straw cup.

Abdulla was introduced to dissolvable solid Veggie Sticks today. He brought the Veggie Sticks to his lateral gums using a palmer grasp and engaged in a sustained munch chewing pattern with tongue lateralization. Initially, as small pieces broke apart in his mouth, Abdulla grimaced and tried to spit out the small pieces. He continued to bring the dissolvable solid to his mouth and with time, chewed and swallowed the dissolvable solids. Abdulla was offered Mum-mums in a mesh feeder bag. He brought the bag to his mouth, grimaced, and showed disinterest in the mesh feeder bag.

Pharyngeal swallow function appeared intact. There were no overt clinical signs concerning for aspiration (e.g. coughing, choking, increased pharyngeal congestion, etc.) with thin liquids, purees or solids.

IMPRESSIONS:
Abdulla Aldhaeri is a 2-year, 11-month-old former 25-week premature infant with a complex medical history significant for cerebral palsy, global developmental delay and auditory and visual impairments who was seen today for a clinical assessment of his oral feeding and swallowing skills. Based on today's evaluation, Abdulla presents with oral phase dysphagia characterized by impaired oral motor skills for chewing. There appears to be a sensory based component to Abdulla’s feeding difficulties characterized by grimacing with solids, though with repeated exposure, Abdulla demonstrated less significant sensory responses. Abdulla’s initial strong reaction to sensory experiences is likely related to spasticity associated with his diagnosis of spastic quadriplegia cerebral palsy. The following recommendations were discussed with his caregivers today.

RECOMMENDATIONS: To be implemented pending physician review.
1. Abdulla is safe to continue to receive thin liquids, purees and dissolvable or soft, mashable solids as currently tolerated.
2. Offer water via straw to promote independence. This is a developmentally appropriate cup for Abdulla, and he efficiently extracted consecutive sips of liquid via straw today. May continue to offer water via open cup as well.
3. Consider offering Abdulla puree via pouch to promote self-feeding. Bringing the pouch to Abdulla’s mouth independently is easier than bringing the spoon to his mouth from a hand to mouth coordination standpoint.
4. Introduce Abdulla to stick-shaped dissolvable solids (e.g. freeze dried fruits, Veggie Sticks, Snapea Crisps, graham crackers, etc.), as these foods break down easily when mixed with saliva and do not require a mature

Ambulatory Documentation

chewing pattern. These foods facilitate development of chewing skills. Placing the foods laterally will support developing tongue lateralization. The stick shape will also help to reduce gagging, as it provides an additional level of control versus smaller pieces of food (e.g., Gerber dissolvable puffs) which can "get lost" once placed intraorally.
5. Avoid offering Abdulla more advanced textures (e.g. chewy bread, meat, nuts, etc.), as he does not yet have the oral motor skills to support chewing of these more difficult to chew textures.
6. Return for a follow-up clinical feeding evaluation in 2-3 months to assess Abdulla's progress and update recommendations as appropriate. Please call 617-355-7727 with scheduling related concerns.

It was a pleasure to see Abdulla and his family today. If you have any questions regarding this report, I can be reached directly at (617) 919-3648 or Mia.Grossman@childrens.harvard.edu.

Mia Grossman, MS, CCC-SLP
Speech-Language Pathologist
Feeding and Swallowing Program

Boston Children's Hospital
300 Longwood Avenue
Boston, MA 02115

BCH MRN: **500-20-94**
Patient Name: **ALDHAHERI, ABDULLA KHALIFA**
DOB/Age/Sex: 2/18/2014 3 years Male

Admit Date: 1/10/2017
Discharge Date: 1/10/2017

Patient Location: Speech Pathology Longwood
Patient Type: Outpatient
Financial #: 6120025918

Ambulatory Documentation

DOCUMENT NAME:	Communication Enhancement Visit
SERVICE DATE/TIME:	1/10/2017 09:09 EST
PERFORM INFORMATION:	ENGSTLER MA,CCC-SLP,KATHERINE A (1/19/2017 09:10 EST)
SIGN INFORMATION:	ENGSTLER MA,CCC-SLP,KATHERINE A (1/19/2017 09:38 EST)
RESULT STATUS:	Auth (Verified)

BOSTON CHILDREN'S HOSPITAL
FEEDING AND SWALLOWING PROGRAM

RESULTS OF MODIFIED BARIUM SWALLOW STUDY

Abdulla Khalifa AlDhaheri is a 2-year-old boy seen today for an instrumental assessment of swallow function.

Referred by: Dr. Thomas R. Martin, MD, 11/21/2016

Accompanied to study by: Mother and nanny

Medical Information:

- Born at 25 weeks, 5 days in the UAE
- 1 of 2 surviving triplets
- Abdulla spent 4 months in NICU with 6 weeks mechanical ventilation, followed by CPAP
- At 40 weeks suffered intracranial hemorrhage resulting in hydrocephalus and placement of VP shunt
- Spastic quadriplegia
- Cerebral palsy with superimposition of right hemiplegia
- Bilateral auditory neuropathy spectrum disorder for which he has hearing aids. Cochlear implant is being considered.
- Vision impairment
- Receives PT, OT, and speech therapy for several hours per week in the UAE, as well as feeding and aquatherapy in UAE. Currently receiving OT and PT through BCH. Not yet enrolled in Early Intervention services.
- No reported vomiting or reflux.
- History of recurrent chest congestion and cough every 4-6 weeks, typically resolved with nebulizer steroid, as well as mild asthma
- Concern for aspiration due to axial weakness/hypotonia, developmental delay, and possible movement disorder

Ambulatory Documentation

- Mother reports no recent upper respiratory infections, nor pneumonia
- Abdulla has been growing well per mother

Feeding and Swallowing Information:

- Full Oral Feeder
- Per mother he generally eats and drinks well and will eat a variety of foods. He is sensitive to taste and texture.
- Abdulla has difficulty chewing and doesn't move food from one side to the other
- He drinks water from a sippy cup or regular cup
- Eats 3 meals a day plus snacks. He is starting to feed himself.
- Mother denied coughing, choking or gagging while eating or drinking.
- Abdulla has not previously been seen for a Modified Barium Swallow Study or Clinical Feeding Evaluation
-

PROCEDURES:
Positioning: seated upright in Tumble Form feeder seat

View: Lateral

Consistencies Offered:

- Thin liquid via open cup
- Thin liquid via straw (refused)
- Thick yogurt via spoon
- Mixed consistency chicken and yogurt via spoon
- Graham cracker

Cooperation: Cooperation was fair. Results are considered reliable for the study of thin liquids via open cup and purees via spoon.

RESULTS:
The oral preparatory phase of the swallow was characterized by reduced oral strength and tone. Abdulla took large, consecutive sips of thin liquid via open cup. Spoon feeding skills with yogurt were functional with adequate bolus formation and propulsion. He demonstrated oral hypersensitivity with gagging and subsequent emesis with mixed consistency chicken and yogurt. Chewing skills could not be assessed as Abdullah spit out pieces of graham cracker after minimal chewing.

The onset of the pharyngeal swallow was timely with thin liquid and puree. There was no evidence of pharyngonasal reflux.

Ambulatory Documentation

The pharyngeal phase of the swallow was characterized by overall adequate laryngeal vestibule closure with thin liquids and purees. There was inconsistent shallow larygneal pentration with large consecutive sips of thin liquids which did not result in aspiration and was not considered clinically significant. There was no laryngeal penetration or aspiration with purees. No swallows of mixed consistency or chewable solids were captured under fluoroscopy. Pharyngeal propulsion was adequate with no residue in the hypopharynx following the swallow.

The upper esophageal phase of the swallow was characterized by adequate cricopharyngeal relaxation for accommodation of all boluses for movement into the esophagus.

IMPRESSIONS:
Abdulla Aldaheri was evaluated today due to concern for oropharyngeal dysphagia in the setting of recurrent cough, axial weakness/hypotonia, developmental delay, and possible movement disorder.

Abdulla presents today with oral phase dysphagia characterized by reduced oral tone and oral hypersensitivity, as well as reports of impaired chewing. Chewing skills could not be assessed during this study due to refusal and spitting out pieces of cracker. Despite oral phase deficits, the pharyngeal phase of the swallow as grossly intact with timely swallow onset and no aspiration with large, consecutive sips of thin liquid and purees. There was inconsistent shallow larygneal pentration with large consecutive sips of thin liquids which did not result in aspiration and was not considered clinically significant. Abdullah appears safe to continue to receive thin liquids and purees by mouth. His oral motor skills for solids will be further assessed during his Clinical Feeding Evaluation which is scheduled for 2/7/17 in Waltham.Given today's results, it is unlikely that aspiration from above has contributed to Abdulla's respiratory symptoms.

RECOMMENDATIONS: Implemented upon physician review.
1. Abdullah is considered safe to continue to receive thin liquids and purees by mouth given no documented aspiration.
2. Continue to offer chewable solids and mixed consistencies as tolerated. Discontinue with repeated gagging.
3. Follow up with referring physician and medical team with today's results.
4. We will see Abdulla for a Clinical Feeding Evaluation 2/7/17 for further assessment of his oral motor skills for solid foods.
5. Repeat MBS is not indicated at this time given grossly intact pharyngeal swallow function. MBS can be repeated as needed based on clinical presentation.

It was a pleasure to see Abdulla today. If there are any questions or concerns, I can be reached directly at 781-216-2241 or via email at katherine.engstler@childrens.harvard.edu.

Katherine Engstler, MA, CCC-SLP
Speech-Language Pathologist
Feeding and Swallowing Program

Ambulatory Documentation

DOCUMENT NAME: Communication Enhancement Visit
SERVICE DATE/TIME: 1/3/2017 20:33 EST
PERFORM INFORMATION: RUSSELL OT,SUSANNE S (1/10/2017 20:34 EST)
SIGN INFORMATION: RUSSELL OT,SUSANNE S (1/10/2017 20:34 EST)
RESULT STATUS: Auth (Verified)

COCHLEAR IMPLANT PROGRAM
Occupational Therapy Assessment
Date of Service: January 3, 2017

Name: Abdulla Aldhaheri
DOB: 2/18/2014
Medical Record Number: 5002094

ICD-10 code: G80.0

Contact:
Parents
160 Boylston Street, Apt 2233
Chestnut Hill, Mass. 02467
Cell: (857) 891-3680

Abdulla Aldhaheri, 2 years 11 months, was seen for a 30 minute occupational therapy session, as part of a Cochlear Implant consultation on January 3, 2017. He was accompanied by his mother and nanny, both of whom observed today's consultation procedures. Other participating members of the Cochlear Implant team today included Dr Terrell Clark, psychologist and Nicole Salamy, speech –language pathologist. Their summaries are found under separate cover. Abdulla is from the UAE and has been in Boston since the Fall, 2016. He is known to multiple doctors at Boston Children's Hospital as well as clinicians within the Occupational Therapy and Physical Therapy Departments where he has been receiving regular therapy services over the past several months.

SESSION FOCUS
The focus of today's session was to assess Abdulla's overall motor profile, as it relates to his candidacy for a Cochlear Implant (CI) and secure placement of the CI external processor.

RELEVANT MEDICAL HISTORY

Ambulatory Documentation

Abdulla presents with a complex sensory motor profile notable for premature birth (25 weeks). He is a product of a triplet birth. His twin brother Mohamed is also here in Boston while his father and siblings remain back home in the UAE. The third sibling unfortunately passed away at age 40 weeks from complications associated with prematurity. Secondary complications to Abdullah's prematurity included intracranial hemorrhage, hydrocephalus status post VP shunt, and spastic quadriplegia with superimposition of right hemiplegia, developmental delay, hearing loss and retinopathy of prematurity s/p laser treatment.

POSITIONING AND PHYSICAL ACCESS STATUS
Abdullah presents with increased muscle tone throughout his entire right side and both legs. He wears bilateral custom AFO's but no trunk support. He demonstrates most voluntary control over movement using his left hand, while no spontaneous use of his right hand was noted. His mother does report that when his left hand is stabilized, he will start using his right hand.

Abdullah arrived in a mass market stroller, which is used primarily for ease of assisted transport.
As noted in a recent Physical Therapy Report, Abdullah was evaluated for a custom seating system, to provide increased proximal and distal support and minimize adverse effects of his underlying movement challenges. Reportedly, when on the floor he is able to combat crawl and roll.

Today's clinician contacted DME equipment supplier NuMotion, who reported that a Kimba Neo wheeled stroller with floor base was recommended. Funding was approved by the UAE Embassy, the custom chair was ordered and reportedly is currently available for setup and adjustments.

SUMMARY
Abdulla presents with underlying sensory-motor challenges secondary to his premature birth. While his vision appears functional, he exhibits significant hearing impairment bilaterally. He is being considered for a Cochlear Implant, as a technology to provide access to sound and hopefully language. Currently he does not have any intelligible speech and no meaningful vocalizations. He presents as very visually attentive and observant, closely watching the facial expressions and gestures of others.

ADAPTIVE SEATING SYSTEM: As a result of a recent seating-positioning assessment by Elizabeth Maczek, RPT within the Physical Therapy Department at Boston Children's Hospital, in conjunction with Ian Kingscote, RTS with Numotion, Abdullah is scheduled to be fit for an Ottobock Kimba Kozi seating system with Kimba Neo Mobility Base. Reportedly, this stroller has been ordered and delivered to NuMotion. So Numotion will be in touch with his family to schedule a date for delivery and setup.

COCHLEAR IMPLANT CANDIDACY: From a physical motor perspective, this clinician feels that Abdulla is a candidate for a Cochlear Implant. Of course, the final decision for cochlear implantation is a collective one, with input from all members of the Cochlear Implant Team, including audiology, speech

Ambulatory Documentation

language pathologists, psychologist, ORL doctors and surgeons, as well as other specialists, as dictated by Abdullah's unique needs.

REFERRAL TO THE AUGMENTATIVE COMMUNICATION PROGRAM (ACP) located at Children's Hospital, 9 Hope Avenue, Waltham, Mass. Tel. (781) 216-2209. Given that Abdullah is unable to speak, and is not using any visual displays or other augmentative communication tools, this clinician is recommending that he be scheduled within the Augmentative Communication Program. (ACP). This appointment needs to be coordinated through BCH's International Office in conjunction with Lynne Moran, ACP Scheduling Coordinator at Tel. (781) 216-2209 or via email: lynne.moran@childrens.harvard.edu

ACP FOLLOW-UP: This summary has been forwarded to the International Office, with a request to establish contact with Lynne Moran, to schedule an appointment with an ACP speech therapist to identify visual supports for augmented communication.
Remember to bring Abdullah's new chair with tray!

In closing, it was a pleasure meeting with Abdullah and his wonderful mother. If there are any questions regarding this summary please contact me directly.

Susanne S Russell MS OT
Susanne.russell@childrens.harvard/ Tel. (781) 216-2228
Massachusetts License: 2014

Boston Children's Hospital

300 Longwood Avenue
Boston, MA 02115

BCH MRN: **500-20-94**
Patient Name: **ALDHAHERI, ABDULLA KHALIFA**
DOB/Age/Sex: 2/18/2014 3 years Male

Admit Date: 1/3/2017
Discharge Date: 1/3/2017

Patient Location: DHHP Waltham
Patient Type: Outpatient
Financial #: 6120075250

Ambulatory Documentation

DOCUMENT NAME:	Communication Enhancement Visit
SERVICE DATE/TIME:	1/3/2017 14:10 EST
PERFORM INFORMATION:	SALAMY CCC-SLP,NICOLE (1/6/2017 14:15 EST)
SIGN INFORMATION:	SALAMY CCC-SLP,NICOLE (1/6/2017 14:15 EST)
RESULT STATUS:	Auth (Verified)

Abdulla AlDhaheri and his brother (Mohamed) and their mother were seen for consultation with three members of the Cochlear Implant team - pediatric psychologist, Terrell A. Clark, PhD; speech-language pathologist, Nicole Salamy, MS, CCC-SLP; and occupational therapist, Susanne Russell, OT-R . This consultative visit through the Boston Children's Hospital at the Waltham site was arranged as components of the process of investigating whether Abdulla would be a "candidate" for cochlear implantation and to address the mother's questions, offer information, and provide anticipatory guidance. The full report of this interdisciplinary clinical consultation will be found in the electronic medical record under the signature of Dr. Terrell Clark. Please refer to that report for full details.

Boston Children's Hospital
300 Longwood Avenue
Boston, MA 02115

BCH MRN: **500-20-94**
Patient Name: **ALDHAHERI, ABDULLA KHALIFA**
DOB/Age/Sex: 2/18/2014 3 years Male

Admit Date: 4/4/2017
Discharge Date: 4/4/2017

Patient Location: Speech Therapy Waltham
Patient Type: Outpatient
Financial #: 6120432959

Ambulatory Documentation

DOCUMENT NAME:	Communication Enhancement Visit
SERVICE DATE/TIME:	4/4/2017 17:03 EDT
PERFORM INFORMATION:	GROSSMAN CCC-SLP,MIA (4/4/2017 17:03 EDT)
SIGN INFORMATION:	GROSSMAN CCC-SLP,MIA (4/4/2017 17:03 EDT)
RESULT STATUS:	Auth (Verified)

CLINICAL FEEDING EVALUATION- FOLLOW UP
FEEDING AND SWALLOWING PROGRAM

INTERIM INFORMATION:
Abdulla Aldhaheri is a 3-year-old boy with a diagnosis of cerebral palsy with right hemiplegia and spastic quadriplegia who was seen today for a clinical assessment of his oral feeding and swallowing skills. He was accompanied to today's appointment by his mother and father, who served as informants. His brother, Mohamed was also present for today's visit. Abdulla is known to this service from a modified barium swallow study on 1/10/17 and known to this clinician from a previous clinical feeding evaluation on 2/7/17.

To briefly review, Abdulla presents with a complex medical history significant for a diagnosis of cerebral palsy with right hemiplegia and spastic quadriplegia and global developmental delay. He is 1 of 2 surviving of a set of triplets born at 25 5/7 weeks gestation in the UAE. He required a 4 month NICU stay complicated by need for mechanical ventilation for ~6 weeks, followed by CPAP requirement. At 40 weeks gestation, Abdulla suffered from intracranial hemorrhage, resulting in hydrocephalus and placement of VP shunt. Abdulla also presents with a diagnosis of bilateral auditory neuropathy. He underwent right cochlear implantation on 2/2/17. There are no concerns regarding stooling, vomiting or reflux. No recent changes to medication or allergies reported. Abdulla and his brother present with nasal congestion at baseline today, treated with a nebulizer.

Abdulla is a full oral feeder. Abdulla's mother reported improvements in his feeding skills since his last appointment. He now independently drinks water or juice via straw cup. Abdulla drinks 8 oz. of juice or 4 oz. of water per sitting. There is no coughing or choking with drinking. Abdulla continues to self-feed. His mother places small pieces of orange, crackers, Veggie Sticks, bread, pancakes, which Abdulla independently brings to his mouth. Abdulla's typical feeding schedule has remained the same as his last visit:

8am- Breakfast- Infant rice cereal made with water, 4 oz. water via open cup
11am- Snack- soft bread, water
12/1p- Lunch- Rice with chicken or meat and yogurt, water via open cup
Nap
4/5p- Snack- fruit yogurt (2 containers)
7:30/8p- Dinner- Rice with chicken or meat and yogurt, water via open cup

Ambulatory Documentation

8:30/9- Bedtime

Abdulla no longer receives physical therapy and occupational therapy at Boston Children's Hospital, but is receiving these therapies through home visits. He is scheduled to transition to school based services in 2 weeks through the Dedham Public Schools, and will likely be enrolled in an extended school year program. His family has plans to return to the UAE in early September.

ASSESSMENT:
Abdulla was seated upright in a Rifton chair with back and foot support for today's assessment. An oral mechanism examination revealed reduced oral muscle tone with a slightly open mouth posture noted at rest. Mouth breathing was noted in the setting of nasal congestion. Secretion management was adequate. Lingual range of motion was intact. Unfortunately, foods from home were not brought to today's appointment. Abdulla was offered Veggie Straws, puffs, and water via flip-top straw cup.

Abdulla was offered water via flip-top straw cup. He accepted the straw intraorally and created an adequate lip seal to avoid anterior liquid loss. He independently extracted consecutive sips of water via straw cup.

With dissolvable solid Veggie Sticks, Abdulla allowed the clinician to hold the dissolvable solid on his lateral molars. He engaged in a sustained munch chewing pattern with tongue lateralization and broke a piece from the whole. Abdulla continued to demonstrate tongue lateralization with the smaller piece of Veggie Stick, and adequately pulverized the solid prior to swallowing. With larger pieces, Abdulla engaged in a suckling pattern combined with tongue lateralization to break down the solid. Abdulla accepted a puff on his lateral molars. He initially spit out the puff. He then self-fed a puff, and engaged in a suckling pattern, moving it laterally with his tongue with alternating unsustained munching.

Pharyngeal swallow function appeared intact. There were no overt clinical signs concerning for aspiration (e.g. coughing, choking, increased pharyngeal congestion, etc.) with thin liquids, or dissolvable solids.

IMPRESSIONS:
Abdulla Aldhaeri is a 3-year-old former 25-week premature infant with a complex medical history significant for cerebral palsy, global developmental delay and auditory and visual impairments who was seen today for a clinical assessment of his oral feeding and swallowing skills. Based on today's evaluation, Abdulla continues to present with oral phase dysphagia characterized by impaired oral motor skills for chewing. There are no concerns regarding pharyngeal swallow function at this time. Since his last visit, Abdulla has demonstrated improved chewing skills, and his developmental feeding skills continue to progress. The following recommendations were discussed with his caregivers today.

RECOMMENDATIONS: To be implemented pending physician review.

1. Abdulla is safe to continue to receive thin liquids, purees and dissolvable or soft, mashable solids as currently tolerated.

Ambulatory Documentation

2. Continue to offer water via straw to promote independence. May continue to offer water via open cup as well.
3. Consider offering Abdulla puree via pouch to promote self-feeding. Bringing the pouch to Abdulla's mouth independently is easier than bringing the spoon to his mouth from a hand to mouth coordination standpoint.
4. Introduce Abdulla to stick-shaped dissolvable solids (e.g. freeze dried fruits, Veggie Sticks, Snapea Crisps, graham crackers, etc.), as these foods break down easily when mixed with saliva and do not require a mature chewing pattern. These foods facilitate development of chewing skills. Placing the foods laterally will support developing tongue lateralization.
5. Avoid offering Abdulla more advanced textures (e.g. chewy bread, meat, nuts, etc.), as he does not yet have the oral motor skills to support chewing of these more difficult to chew textures.
6. Return for a follow-up clinical feeding evaluation in 2-3 months to assess Abdulla's progress and update recommendations as appropriate. Please call 617-355-7727 with scheduling related concerns.

It was a pleasure to see Abdulla and his family today. If you have any questions regarding this report, I can be reached directly at (617) 919-3648 or Mia.Grossman@childrens.harvard.edu.

Mia Grossman, MS, CCC-SLP
Speech-Language Pathologist
Feeding and Swallowing Program

Boston Children's Hospital

300 Longwood Avenue
Boston, MA 02115

BCH MRN: **500-20-94**
Patient Name: **ALDHAHERI, ABDULLA KHALIFA**
DOB/Age/Sex: 2/18/2014 3 years Male

Admit Date: 3/31/2017
Discharge Date: 3/31/2017

Patient Location: DHHP Waltham
Patient Type: Outpatient
Financial #: 6120500266

Ambulatory Documentation

DOCUMENT NAME: Communication Enhancement Visit
SERVICE DATE/TIME: 3/31/2017 13:26 EDT
PERFORM INFORMATION: SALAMY CCC-SLP,NICOLE (4/4/2017 13:32 EDT)
SIGN INFORMATION: SALAMY CCC-SLP,NICOLE (4/4/2017 13:32 EDT)
RESULT STATUS: Auth (Verified)

Reason for Visit
Speech and language therapy

Session Narrative/HPI
Abdulla AlDhaheri was seen today (3/31/17) for speech and language therapy with speech-language pathologist, Nicole Salamy, MS, CCC-SLP. He arrived today with his mother, father and brother. His mother joined him for the duration of the session.

Mother reports that Abdulla is not responding to sounds at home (i.e. when his name is called). However, his mother is noticing that he is vocalizing more at home and producing new sounds such as ‘mama’ and ‘baba.’ Today, he was observed to produce ‘ah’ and /n/, which were different than sounds heard previously. Abdulla's Mother also reports that he is demonstrating comprehension of the spoken word “up” at home. There were no noticeable responses to loud noises or target speech sounds during the session today.

Abdulla was seated in a Rifton chair and wore his cochlear implant processor for the session today, without the headband, which is lost. On several occasions, he pointed to objects of interest and he will look for desired items when they are not visible.

The plan is to see Abdulla return after his next mapping appointment in a few weeks.

Problem List/Past Medical History
Ongoing
- Bronchopulmonary dysplasia
- Childhood asthma
- Cochlear implant in situ
- Developmental delay
- Dysarthria
- Feeding difficulties and mismanagement
- Hearing loss
- Mixed receptive-expressive language disorder
- Sensorineural hearing loss, bilateral
- Spastic quadriplegic cerebral palsy
- Wheeze

Historical
- Speech delay

Procedure/Surgical History
Cochlear device implantation, with or without mastoidectomy (02/02/2017), Cochlear device implantation, with or without mastoidectomy (02/02/2017).

Medications
- aerochamber with medium mask, See Instructions
- albuterol 1.25 mg/3 mL (0.042%) inhalation solution, 1.25 mg, INH, Q4hr, PRN
- Flovent HFA 110 mcg/inh inhalation aerosol, 2 puff, INH, daily
- Nebulizer machine, See Instructions
- Vitamin D3 400 intl units/mL oral liquid, 400 unit = 1 mL, PO, daily

Allergies
No known allergies

Social History
Assistive Technology Right - Audiology
- Hearing Device Cochlear Implant. Manufacturer Cochlear Americas. Model Internal: CI522; External: CP950

Ambulatory Documentation

& CP910. Serial Number Internal: 1020170202749. Date Fit Surgery: 2/2/2017; Activation: 2/21/2017. Battery Size 675. Rechargeable Battery Lithium ion (CP910 only).

Basic Social History

Living Arrangement Parent(s)/Guardian. Legal Guardian: Parent. Lives With: Mother, Father, Brother, nanny. Language Spoken at Home: English and Arabic.

Home/Environment

Living situation: Home with assistance. Devices or Anatomic Adaptations: Ventriculoperitoneal shunt, Glasses, Hearing aides. Home equipment: Adaptive stroller, Ankle foot orthoses (AFO's).

Family History

Developmental delay: Brother.
Seizures: Cousin.

Boston Children's Hospital

300 Longwood Avenue
Boston, MA 02115

BCH MRN: **500-20-94**
Patient Name: **ALDHAHERI, ABDULLA KHALIFA**
DOB/Age/Sex: 2/18/2014 3 years Male

Admit Date: 3/17/2017
Discharge Date: 3/17/2017

Patient Location: DHHP Waltham
Patient Type: Outpatient
Financial #: 6120499960

Ambulatory Documentation

DOCUMENT NAME: Communication Enhancement Visit
SERVICE DATE/TIME: 3/17/2017 16:40 EDT
PERFORM INFORMATION: SALAMY CCC-SLP,NICOLE (3/17/2017 16:43 EDT)
SIGN INFORMATION: SALAMY CCC-SLP,NICOLE (3/17/2017 16:43 EDT)
RESULT STATUS: Auth (Verified)

Reason for Visit
Speech and language therapy/ACP evaluation

Session Narrative/HPI
Abdulla AlDhaheri was seen today (3/17/17) for speech and language therapy with speech-language pathologist, Nicole Salamy, MS, CCC-SLP. He was seen in collaboration with my colleague, Elizabeth Rose, SLP, in the Augmentative Communication Program. His mother joined him for the duration of the session.

Mother reports that Abdulla will cry to express his wants and needs. In addition, Abdulla's mother reports that he can recognize when others are angry and he will react by crying. He also makes attempts to imitate others (e.g. facial expressions). Abdulla will reach for desired objects. Mother has observed that he is less interested in toys but enjoys coloring and using the iPad. He has demonstrated the ability to isolate his pointer finger to swipe on an iPhone.

Abdulla was seated in a Rifton chair and wore his cochlear implant processor for the session today. He was not observed responding to loud sounds or to his mother's voice during the session today. Mother reports that he has been taking off his processor and throwing it at home.

During the session today, he was interested in a book, but he was not observed making a choice when provided two objects. He was shown two pictures, but did not reliably make a choice to indicate a desired item. Abdulla was shown a variety of signs today (more, bubbles, stop, book) and he demonstrated emerging ability to communicate using signs provided maximal adult support. He was also observed using a meaningful point on two occasions. Today, Abdulla's mother was provided coaching and modeling on how to continue to encourage communication at home. Abdulla should be offered choices whenever possible. Furthermore, Abdulla's care providers are encouraged to use meaningful signs (connected with the spoken word and object) to foster the development of expressive and receptive language skills.

For further recommendations please see the evaluation report in the medical record under the signature of Elizabeth Rose, SLP.

Problem List/Past Medical History
Ongoing
- Bronchopulmonary dysplasia
- Childhood asthma
- Cochlear implant in situ
- Developmental delay
- Feeding difficulties and mismanagement
- Hearing loss
- Sensorineural hearing loss, bilateral
- Spastic quadriplegic cerebral palsy
- Speech delay
- Wheeze

Historical
- No qualifying data

Procedure/Surgical History
Cochlear device implantation, with or without mastoidectomy (02/02/2017), Cochlear device implantation, with or without mastoidectomy (02/02/2017).

Medications
- aerochamber with medium mask, See Instructions
- albuterol 1.25 mg/3 mL (0.042%) inhalation solution, 1.25 mg, INH, Q4hr, PRN
- Flovent HFA 110 mcg/inh inhalation aerosol, 2 puff, INH, daily
- Nebulizer machine, See Instructions
- Vitamin D3 400 intl units/mL oral liquid, 400 unit = 1 mL, PO, daily

Allergies
No known allergies

Social History
Assistive Technology Right - Audiology
- Hearing Device Cochlear Implant. Manufacturer Cochlear Americas. Model Internal: CI522; External: CP950 & CP910. Serial Number Internal: 1020170202749. Date Fit Surgery:

Ambulatory Documentation

2/2/2017; Activation: 2/21/2017. Battery Size 675. Rechargeable Battery Lithium ion (CP910 only).

Basic Social History

Living Arrangement Parent(s)/Guardian. Legal Guardian: Parent. Lives With: Mother, Father, Brother, nanny. Language Spoken at Home: English and Arabic.

Home/Environment

Living situation: Home with assistance. Devices or Anatomic Adaptations: Ventriculoperitoneal shunt, Glasses, Hearing aides. Home equipment: Adaptive stroller, Ankle foot orthoses (AFO's).

Family History

Developmental delay: Brother.
Seizures: Cousin.

Boston Children's Hospital

300 Longwood Avenue
Boston, MA 02115

BCH MRN: **500-20-94**
Patient Name: **ALDHAHERI, ABDULLA KHALIFA**
DOB/Age/Sex: 2/18/2014 3 years Male

Admit Date: 3/17/2017
Discharge Date: 3/17/2017

Patient Location: ACP/Waltham
Patient Type: Outpatient
Financial #: 6120487536

Ambulatory Documentation

DOCUMENT NAME: Communication Enhancement Visit
SERVICE DATE/TIME: 3/17/2017 14:50 EDT
PERFORM INFORMATION: ROSE CCC-SLP,ELIZABETH (3/31/2017 15:37 EDT)
SIGN INFORMATION: ROSE CCC-SLP,ELIZABETH (3/31/2017 16:09 EDT)
RESULT STATUS: Auth (Verified)

Reason for Visit
Augmentative Communication Program
Speech-Language Pathology
Initial Evaluation

Session Narrative/HPI
Abdulla, a 3 year, 0 month old male, was seen for a 120-minute augmentative and alternative communication (AAC) evaluation at the Augmentative Communication Program (ACP) to evaluate alternative strategies to facilitate communicative independence. Nicole Salamy, MS, CCC-SLP of the DHHP program, was present for and participated in the evaluation session. Abdulla was accompanied by his mother, and was pleasant and cooperative throughout the evaluation. All background information was gained through parent/caregiver report, review of medical records, and observations throughout the evaluation session. This was Abdulla's first visit to the ACP.

MEDICAL HISTORY
Abdulla, a former 25-5/7 week preemie, presents with a primary diagnosis of spastic quadriplegia with superimposition of right hemiplegia, and resulting and/or concomitant diagnoses including intracranial hemorrhage and hydrocephalus s/p VP shunt, developmental delay, hearing loss and retinopathy of prematurity s/p laser treatment, CI status, dysarthria, and a mixed receptive-expressive langauge disorder. Secondary to his diagnoses, Abdulla presents with medical status significant for the following:

VISION: Abdulla is status post treatment for retinopathy of prematurity. His parents report that he has good visual acuity. He was last seen in ophthalmology on 9/20/2016 and recommended glasses, consideration of patching. He presents with a mild right exotropia. Informal observation of functional visual performance during the SGD assessment revealed that Abdulla does not require modifications to use an appropriate communication system effectively.

HEARING: Abdulla underwent a sedated auditory brainstem response (ABR) completed at Boston Children's on 10/31/2016, revealing bilateral auditory neuropathy spectrum disorder (ANSD). A trial period with bilateral amplification yielded no measurable benefit per parent report.He is now status post cochlear device implantation (2/02/2017): Cochlear CI522 cochlear implant, Kanso external speech processor, a CP910 speech processor. DHHP SLP Nicole Salamy, MS, CCC-SLP, participated in evaluation this date to continue to evaluate and support Abdulla's hearing needs. Abdulla's mother reported that he has few responses to sounds s/p CI. CI is consistently monitored by DHHP and BCH Audiology.

FEEDING/SWALLOWING/NUTRITION: Abdulla does have a known dysphagia. Abdulla's mother reported that he eats all tastes and textures, but food is given to him in small

Problem List/Past Medical History
Ongoing
- Bronchopulmonary dysplasia
- Childhood asthma
- Cochlear implant in situ
- Developmental delay
- Dysarthria
- Feeding difficulties and mismanagement
- Hearing loss
- Mixed receptive-expressive language disorder
- Sensorineural hearing loss, bilateral
- Spastic quadriplegic cerebral palsy
- Wheeze

Historical
- Speech delay

Procedure/Surgical History
Cochlear device implantation, with or without mastoidectomy (02/02/2017), Cochlear device implantation, with or without mastoidectomy (02/02/2017).

Medications
- aerochamber with medium mask, See Instructions
- albuterol 1.25 mg/3 mL (0.042%) inhalation solution, 1.25 mg, INH, Q4hr, PRN
- Flovent HFA 110 mcg/inh inhalation aerosol, 2 puff, INH, daily
- Nebulizer machine, See Instructions
- Vitamin D3 400 intl units/mL oral liquid, 400 unit = 1 mL, PO, daily

Allergies
No known allergies

Social History
Assistive Technology Right - Audiology
- Hearing Device Cochlear Implant. Manufacturer Cochlear Americas. Model Internal: CI522; External: CP950

Ambulatory Documentation

amounts.

MOBILITY STATUS & EQUIPMENT: Abdulla is not yet ambulatory, but is attempting a reciprocal crawl, can army crawl, and typically rolls to get around at home. Abdulla reportedly has the following adaptive equipment: bilateral unhinged AFOs, posterior walker wtih harness, wrist splint (R).

RANGE OF MOTION/ACTIVE TONE/STRENGTH: Abdulla presents with atypical muscle tone and decreased strength. Tone, strength, and upper extremity range of motion were informally observed to be within functional limits for all unadapted. communication activities presented this date. Abdulla demonstrated adequate hand and arm use for adapted communication tasks presented throughout the evaluation.

POSTURAL/POSITIONING: This date, Abdulla was positioned in his conventional stroller, on the floor, in arms, or in a small Rifton with pommel and tray. He was able to maintain upright posture in a chair when provided with minimal positioning support.

LANGUAGE: Abdulla is exposed to both English and Arabic. Both languages are spoken in his home. School and school-based therapies are conducted in English. Abdulla's mother requested that all intervention this date (including language stimulation, informal assessment, voice output, etc.) be conducted in English. Further, Abdulla is now exposed to beginning American Sign Language, although he remains emergent in ASL.

MEDICAL: Abdulla and his twin brother Mohamed (also evaluated this date) receive consistent stem cell therapy out of the country. Their last stem cell treatments occurred in January 2016 and they are scheduled for another round in January 2018. Per parent report, their physical skills increase significantly following stem cell therapies.

EDUCATION/THERAPEUTIC SERVICES
Abdulla has not been enrolled in education or therapy services, but will soon begin a preschool program through Dedham Public Schools (MA). Evaluation and placement has not yet taken place. Through his school program, it is anticipated that Abdulla will receive occupational, physical, and speech-language therapy intervention services.

COMMUNICATION STATUS
Abdulla's receptive and expressive language skills were obtained via report, informal measures, review of records, DHHP SLP reports, and clinical observation. Abdulla presents with dysarthria and a mixed receptive-expressive language disorder secondary to his diagnoses.

RECEPTIVE LANGUAGE:
Abdulla presents with the emerging ability to attend to loud non-speech sounds in his environment s/p CI activation. He reportedly demonstrates anticipation of routines (ex. getting ready to go outside), and has understanding of some routine cause/effect (ex. throwing items for others to retrieve). He does not yet respond to his name due to hearing status; however, responds to social smiling and similar visual pragmatic routines. Abdulla does not yet greet/bid farewell given any level of prompting. When presented with a preferred visual within a routine or when highly motivated, Abdulla demonstrates some emerging understanding of yes/no questions (visual only). Once his attention is gained, Abdulla often mirrors the facial expressions and actions of communication partners. He was observed to enjoy finger plays. Regarding literacy skills, Abdulla has not yet been exposed to books for facing, turning pages, etc. He does not yet demonstrate understanding of sign language signs.

& CP910. Serial Number Internal: 1020170202749. Date Fit Surgery: 2/2/2017; Activation: 2/21/2017. Battery Size 675. Rechargeable Battery Lithium ion (CP910 only).

Basic Social History
Living Arrangement Parent(s)/Guardian. Legal Guardian: Parent. Lives With: Mother, Father, Brother, nanny. Language Spoken at Home: English and Arabic.

Home/Environment
Living situation: Home with assistance. Devices or Anatomic Adaptations: Ventriculoperitoneal shunt, Glasses, Hearing aides. Home equipment: Adaptive stroller, Ankle foot orthoses (AFOs).

Family History
Developmental delay: Brother.
Seizures: Cousin.

Ambulatory Documentation

Assessment of Abdulla's receptive language revealed that he has limited exposure to receptive language (auditorily, visually, etc.) due to his diagnoses and history.

EXPRESSIVE LANGUAGE – UNAIDED:
Abdulla's verbal/vocal output includes laughs, cries, non-speech sounds (ex. grunts), as well as a single consonant /n/ and vowel "uh." Abdulla produced very few sounds this date, and per parent report this is consistent with his typical performance. His mother reported that he does not have different cries to signal different needs.

EXPRESSIVE LANGUAGE – AIDED (i.e. use of supplemental tools and strategies):
Abdulla utilizes several tools and strategies to aid communication. He was recently introduced to American Sign Language, but attempts to produce signs have been limited. He does have one gesture (smacking lips) to consistently indicate *hunger*. He uses a developing yes/no response (reach/smile/make noise for *yes*, throw item for *no*), low-tech eyegaze (without joint attention), gross motor gestures and body language (reaching), pointing (to iPad only), and facial expressions to express his wants and needs.

Outside of emerging exposure to signs, Abdulla has never been exposed to aided communication methods.

CLINICAL ASSESSMENT
BEHAVIORAL OBSERVATIONS: Abdulla has no history of self-injurious or atypical problem behaviors. Per parent report he does not attempt communication, therefore has no communication breakdowns. Abdulla is a passive communicator, but will cry when upset or not attended to immediately. This date, Abdulla was able to warm to the evaluation setting and was cooperative and engaged in all presented activities. Abdulla enjoys playing on his iPad.

ACCESS/INTERACTION WITH PRESENTED MATERIALS: Given substantial support, Abdulla's most successful communication attempts were all observed to be via sign language this date. Additional trials were conducted with devices, visuals, and partner-assisted techniques to increase his exposure to and use of more language than he is currently able to produce via non-aided means.

SESSION SUMMARY
1. Making choices
Abdulla was presented with a choice making activity with results as follows:
Real objects: Abdulla was presented with choice making using real objects if a field of two. He quickly demonstrated the ability to purposefully choose between two preferred items (an errorless learning activity), and between a preferred and a non-preferred item. Notably, he consistently chose the item on his left side regardless of preference. When introduced to preferred v. non-preferred choice making, items were presented on his left side in a vertical orientation to avoid a location bias. When presented horizontally, Abdulla chose even non-preferred items on his left side. Notably, he did not demonstrate understanding of sabotage (i.e. when he chose "bubbles" and was given "ball," Abdulla did not react).

Abdulla was presented with choice making from a field of two object proxies, tangible symbols, true object-based icons, and real photographs (adapted, unadapted, and presented electronically). He was unable to attend and/or functionally choose between these symbols.

Notably, Abdulla had an extreme left side preference. He struggled to orient attention to

Ambulatory Documentation

anything presented on his right side, regardless of motivation.

4. Targeting & cause-effect
Abdulla was presented with a 10" iPad with a cause/effect and targeting activity ("popping" a balloon as it traveled and changed size on the screen). He accessed the screen via a gross motor swipe, occasionally extending his L index finger to access. He struggled to coordinate physical access to the target, regardless of size. Regardless of location, Abdulla accessed the L side of the screen.

Abdulla was presented with a cause/effect activity that required him to access anywhere on the 10" screen when prompted (visually) to change the photo on the screen. He struggled to attend to the device and attempted to throw it.

Abdulla consistently attempted to access the "HOME" button of the iPad, becoming upset when it was locked.

3. Sign language
Abdulla was presented with a sign language activity involving basic signs and a preferred activity (i.e. blowing bubbles). Ongoing aided language input ("more--bubbles" via sign) was presented. Following 5-7 repetitions of the routine, Abdulla spontaneously and independently signed "bubbles," a new sign. He demonstrated understanding of and expectancy of the routine via smiles and low-tech eyegaze toward the bubble wand. Abdulla signed an approximation of "bubbles" 3x total. Any bimanual attempts were taken (and modeled) as productions for "more."

4. Single message voice output device (VOD) with tactile input and symbol
A red buzzer button paired with a photo of "bubbles" was presented. A phrase requesting continuation ("I want more bubbles!") was recorded on the device, with additional visual supports including a real, unadapted photo (bubbles) and tactile (haptic) feedback to offer multi-sensory input given Abdulla's unknown hearing skills. Abdulla initially attempted to throw all items. He was able to tolerate items after several repetitions of the routine, but, regardless of scaffolding and various levels of prompting, was unable to demonstrate understanding of switch access and his preferred activity.

IMPRESSIONS
Abdulla presented this date as a sweet and charming 3 year, 0 month old emergent communicator. He demonstrated the most success using sign language to access increased language. Notably, Abdulla will continue to benefit from ongoing visual and other multi-sensory feedback to support his language development.

RECOMMENDATIONS
1. Sign Language
Abdulla has had limited exposure to traditional speech-language intervention services. Prior to implementing a formal aided communication system (ex. communication symbols, book, app, device, etc.), basic means of nonverbal communication are to be explored, modeled, and used throughout contexts. Abdulla demonstrated the ability to learn and use a new sign within a single activity during evaluation this date. It is recommended that basic sign language (adapted or formal) be implemented. Baby Signing Time resources (http://babysigningtime.com) and BabySignLanguage.com (www.babysignlanguage.com/dictionary) are recommended to help Abdulla and his family learn basic signs. In particular, the following core signs are to be a focus:

Notably, some signs may need to be modified to compensate for Abdulla's physical status.

Ambulatory Documentation

Pending success with these signs, more signs and/or an expanded aided communication system is to be explored.

2. Making Choices
Abdulla should be presented with choices across his day. Hold up two real objects for Abdulla to reach for the one he wants. At this time, give him choices of all preferred items. When he makes a choice, his request should be praised, modeled, and honored. This can build a positive correlation between using the communication system and communicative success. Remember to **follow through** with Abdulla's requests, even if you know he didn't choose it on purpose.

3. Immediacy
Abdulla has a short working memory and requires quick rewards and feedback on his communication attempts. Make sure to provide Abdulla with options that are able to be immediately acted upon.
For example, if you provide Abdulla with the choice for "I want to go outside," make sure you're ready to go outside, at the door, and are in a situation in which you can go outside. If he chooses "I'd like to go outside" and then has to spend 20 minutes getting his hat, boots, mittens, etc. on, the moment of communication is lost.

Similarly, keep reward times to 10-15 seconds before asking Abdulla to repeat the request again. If Abdulla chooses to watch a favorite TV show and then is rewarded with 45 minutes of TV, the moment of communication is long gone. Providing short rewards (ex. pausing the TV) will motivate Abdulla to use his communication system more.

4. Communication Partner Recommendations
- Decrease **your cues, including visuals**. Each time Abdulla is given a new cue, processing re-starts.
- Have Abdulla make choices to be a more active communicator.
- Expect **Abdulla to learn new things.**
- Expect **Abdulla to perform tasks by himself**.
- Give a **longer wait time**. Extra time may be required to give Abdulla time to process and respond.
- Create a consistent routine rather than over-cuing Abdulla. He performed well in a quiet environment where he was not overstimulated by multiple cues.
- Set expectations for Abdulla. Although we understand what he wants and needs often, **help Abdulla be an active, independent communicator**.

5. Multisensory Input
Various techniques, visuals, strategies, and devices were presented throughout the evaluation without success, largely due to Abdulla's medical and therapeutic history. Abdulla struggled to attend to any presented intervention, including non-work tasks (such as playing with preferred toys). It is anticipated that with increased exposure to communication strategies and when given an outlet (sign) for expressive communication, Abdulla's participation in and attention to the world around him will increase. Continue to expose him to a language-rich environment with visuals and multi-sensory input. Require his to be an active participant in his world. This will both increase his understanding of the communication going on around him, as well as encourage him to participate in more communication.

PLAN
1. Abdulla to continue with all current therapies and plans of care, with support and collaboration available from the Augmentative Communication Program as needed.
2. This clinician to collaborate with Abdulla's new therapy team (to ability) regarding

Ambulatory Documentation

coordinating plans of care across environments. A business card and note were sent to Abdulla's team this date via her family/caregivers.
4. Abdulla to return to the Augmentative Communication Program when he's in the USA for a follow-up evaluation session. **Please contact Lynne Moran at 781-216-2209 for any scheduling changes.**
6. If possible, Abdulla's family, therapy team, caregivers, etc. are encouraged to attend any/all additional sessions to learn to use appropriate communication strategies and to assist him in functional use of low-, mid-, and high-tech strategies across communicative settings.

It was a pleasure to work with Abdulla and his family. For scheduling needs or changes, please contact Lynne Moran at 781-216-2209. Please feel free to contact this clinician with any questions, for clarification, or with other comments about this evaluation.

[1]CI Initial Activation; LEWKOWITZ AuD, ASHLEIGH 02/21/2017 09:23 EST
[2]CI Initial Activation; LEWKOWITZ AuD, ASHLEIGH 02/21/2017 09:23 EST

Boston Children's Hospital

300 Longwood Avenue
Boston, MA 02115

BCH MRN: **500-20-94**
Patient Name: **ALDHAHERI, ABDULLA KHALIFA**
DOB/Age/Sex: 2/18/2014 3 years Male

Admit Date: 3/7/2017
Discharge Date: 3/7/2017

Patient Location: DHHP Waltham
Patient Type: Outpatient
Financial #: 6120495783

Ambulatory Documentation

DOCUMENT NAME:	Communication Enhancement Visit
SERVICE DATE/TIME:	3/7/2017 15:06 EST
PERFORM INFORMATION:	SALAMY CCC-SLP,NICOLE (3/7/2017 15:07 EST)
SIGN INFORMATION:	SALAMY CCC-SLP,NICOLE (3/7/2017 15:07 EST)
RESULT STATUS:	Auth (Verified)

Abdulla AlDhaheri was seen today (3/7/17) for speech and language therapy with speech-language pathologist, Nicole Salamy, MS, CCC-SLP. His mother, uncle and twin brother, Mohamed accompanied him to this visit. He also met with Ashleigh Lewkowitz, AuD for his mapping appointment just prior to this session. Abdulla came to this session with his mother and was in a quiet setting with this clinician for the duration of the session.

Mother reports that this week Abdulla has been responding more to loud sounds in his environment. She has also noticed that both boys are 'playing' with one another more often (i.e. if Abdulla does something silly, Mohamed will laugh in response). Mother also reports that the school district will be completing an evaluation in the coming weeks with the hope that Abdulla will be enrolled in school and ready to begin in early April.

Abdulla was seated in a Rifton chair with a tray and was engaged with the clinician for the duration of the session. He was exposed to a variety of sounds and toys and was observed to smile when provided a very loud noise (blocks in a coffee can). He also was seemingly looking for a loud sound when it was not in view. Abdulla also participated in a turn taking activity with a ball and used vocalizations and eye movements to engage and indicate excitement. Furthermore, during one activity, each time the clinician signed, "MORE?" Abdulla seemingly responded "yes" with his eyebrows. Today, this clinician discussed other means of communication (e.g. signs, eye movements, etc) with his mother. Abdulla was offered a choice and he did look in the direction and reached for one particular toy on several occasions.

Abdulla will be seen next in coordination with the ACP department. Mother was also provided information about getting consultation from a teacher of the deaf or educational audiologist when Abdulla is in school. This clinician is also available to speak with the team at the school at any time should questions arise.

Boston Children's Hospital
300 Longwood Avenue
Boston, MA 02115

BCH MRN: **500-20-94**
Patient Name: **ALDHAHERI, ABDULLA KHALIFA**
DOB/Age/Sex: 2/18/2014 3 years Male

Admit Date: 2/2/2017
Discharge Date: 2/2/2017

Patient Location: Audiology
Patient Type: Outpatient
Financial #: 6120378079

Ambulatory Documentation

DOCUMENT NAME:	Audiology Visit
SERVICE DATE/TIME:	2/2/2017 17:36 EST
PERFORM INFORMATION:	TOZER AuD,REBEKAH (2/2/2017 17:37 EST)
SIGN INFORMATION:	TOZER AuD,REBEKAH (2/2/2017 17:37 EST)
RESULT STATUS:	Auth (Verified)

Report of Audiological Services
Cochlear Implant Program
Intraoperative Test

PATIENT NAME: ALDHAHERI, ABDULLA
MEDICAL RECORD: 500-20-94
DATE OF BIRTH: 02/18/2014
DATE OF TEST: 02/02/2017

Abdulla Aldhaheri was seen in the operating room at Boston Children's Hospital to test the function of his Nucleus CI522 cochlear implant (serial number 1020170202749) following surgical insertion in the right ear by Dr. Greg Licameli.

Impedance telemetry was performed in Common Ground, Monopolar 1, Monopolar 2, and Monopolar 1+2 modes. Results showed all electrodes to have intact circuits with no short or open circuits.

Neural Response Telemetry, performed using a comprehensive evoked potential procedure, showed a compound action potential of the auditory nerve to be present upon stimulation of each intracochlear electrode 1-22. Waveforms were viewed and response thresholds were recorded. An x-ray was also obtained which reportedly confirmed good placement of the electrode array.

Summary:

Today's testing is consistent with proper function of the Nucleus CI522 cochlear implant following surgical insertion in the right ear. The implant will be activated in Audiology in three to four weeks.

Rebekah Tozer, Au.D., CCC-A
Audiologist

Ambulatory Documentation

DOCUMENT NAME: Audiology Visit
SERVICE DATE/TIME: 11/29/2016 14:31 EST
PERFORM INFORMATION: LEWKOWITZ AuD,ASHLEIGH (11/29/2016 14:40 EST)
SIGN INFORMATION: LEWKOWITZ AuD,ASHLEIGH (11/29/2016 14:40 EST)
RESULT STATUS: Auth (Verified)

CI INFO CONSULT

NAME: Abdulla Aldhaheri
DOB: 2/18/2014
MRN: 500-20-94

DATE: 11/29/16

AUDIOLOGIST: Ashleigh Lewkowitz, AuD, CCC-A, F-AAA, PASC, CISC

PURPOSE OF VISIT: Informational session regarding cochlear implant candidacy and realistic expectations.

BACKGROUND INFORMATION: Abdulla is a 2 year, 9 month-old boy from the United Arab Emirates who is one of a set of triplets born at 25 weeks and 5 days. He has a history of spastic quadriplegia, cerebral palsy with superimposition of right hemiplegia, intracranial hemorrhage resulting in hydrocephalus necessitating shunt placement, vision impairment, bilateral hearing loss, and significant speech and developmental delays. Abdulla underwent sedated auditory brainstem response (ABR) testing here at Boston Children's on 10/31/2016 and was found to have bilateral auditory neuropathy spectrum disorder (ANSD). Per parental report, Abdulla does not appear to respond to any sounds in his environment; however, he does frequently babble with /ma-ma-ma/. Abdulla has previously worn hearing aids but ceased consistent use roughly one year ago due to lack of perceived benefit. Mom also notes it was very difficult getting him to keep the aids on his ears.

AUDIOMETRIC TESTING (see attached audiogram): Unaided behavioral observation and visual reinforcement audiometry are completed in soundfield and reveal no repeatable responses to speech, warble tones, or narrowband noise at equipment limits. These results are consistent with a profound degree of hearing loss in at least the better-hearing ear. Reliability of today's results is judged to be fair at best.

INFORMATIONAL COUNSELING: Abdulla's mother arrives at today's appointment having done significant research into cochlear implants on her own. She asks appropriate and intelligent questions about candidacy, devices, follow-up care, and outcomes.

The following areas are discussed:
~ Realistic expectations for cochlear implantation in children with a history of extreme prematurity
~ Candidacy criteria for cochlear implantation
~ Timeline of appointments, including pre-op, day of surgery, recovery period, initial activation, and follow-up

Ambulatory Documentation

~ Speech processor options
~ Care/use/maintenance of equipment
~ Audiologic and therapeutic follow-up required after cochlear implantation
~ Range of functional abilities of children who have cochlear implants
~ Benefits of introducing sign language as a bridge to spoken language in context of Abdulla's reduced dexterity
~ Limitations and precautions for children with cochlear implants

Abdulla's mother is provided with take-home materials about cochlear implants and cochlear implant manufacturers.

SUMMARY: Today's two hour appointment is spent counseling Abdulla's mother on all aspects of cochlear implantation. All questions are answered and resources are provided for further education. His mother is highly motivated and appears to have a good understanding of the information presented today. Further appointments with the team will be coordinated through the International Office.

I look forward to working with Abdulla and his family in the future. Please do not hesitate to contact me at 781-216-2265 or ashleigh.lewkowitz@childrens.harvard.edu with any questions or concerns.

Ashleigh Lewkowitz, AuD, CCC-A, FAAA, PASC, CISC
Clinical Audiologist

Boston Children's Hospital
300 Longwood Avenue
Boston, MA 02115

BCH MRN: **500-20-94**
Patient Name: **ALDHAHERI, ABDULLA KHALIFA**
DOB/Age/Sex: 2/18/2014 3 years Male

Admit Date: 8/10/2017
Discharge Date: 8/10/2017

Patient Location: DHHP Waltham
Patient Type: Outpatient
Financial #: 6121049974

Ambulatory Documentation

DOCUMENT NAME: Communication Enhancement Visit
SERVICE DATE/TIME: 8/10/2017 12:01 EDT
PERFORM INFORMATION: SALAMY CCC-SLP,NICOLE (8/11/2017 12:02 EDT)
SIGN INFORMATION: SALAMY CCC-SLP,NICOLE (8/11/2017 12:02 EDT)
RESULT STATUS: Auth (Verified)

Reason for Visit
Speech and Language therapy/ aural habilitation

Session Narrative/HPI
Abdulla AlDhaheri was scheduled to be seen today (8/10/17) for speech, language and listening therapy with speech-language pathologist, Nicole Salamy, MS, CCC-SLP. He arrived today with his mother, nanny and brother. Abdulla arrived asleep in his stroller and he did not have his cochlear implant processor with him today. They were also provided with replacement batteries. Given his fatigue, Abdulla did not have a language/communication based therapy session today and a follow up visit will be scheduled before the family leaves the United States early next month.

Abdulla's mother provided updated information since their last visit:
-Abdulla has been very happy attending summer school. This is the last week.
-Abdulla's speech processor is reportedly not working so a troubleshooting session will be set up for next week with his mapping audiologist, Ashleigh Lewkowitz.
-The family hopes to return home to the UAE early next month
-They have not yet received the equipment recommended following their visit to the Augmentative Communication Program. Mother reports she will go ahead and purchase an iPad Air so that an appropriate mount and accessories can be pursued as previously planned.

The family and future care providers are directed to the report completed by Elizabeth Rose, MS, CCC-SLP in the Augmentative and Communication Program on March 17th 2017 for a detailed list of alternative communication recommendations so that Abdulla can learn communication strategies for more effective and efficient communication.

Problem List/Past Medical History
Ongoing
- Acute vomiting
- Bronchopulmonary dysplasia
- Childhood asthma
- Cochlear implant in situ
- Developmental delay
- Dysarthria
- Feeding difficulties and mismanagement
- Hearing loss
- Mixed receptive-expressive language disorder
- Sensorineural hearing loss, bilateral
- Spastic quadriplegic cerebral palsy
- Wheeze

Historical
- Speech delay

Procedure/Surgical History
Cochlear device implantation, with or without mastoidectomy (02/02/2017), Cochlear device implantation, with or without mastoidectomy (02/02/2017).

Medications
- aerochamber with medium mask, See Instructions
- albuterol 1.25 mg/3 mL (0.042%) inhalation solution, 1.25 mg, INH, Q4hr, PRN
- Flovent HFA 110 mcg/inh inhalation aerosol, 2 puff, INH, daily
- Nebulizer machine, See Instructions
- Vitamin D3 400 intl units/mL oral liquid, 400 unit = 1 mL, PO, daily

Allergies
No known allergies

Social History
Assistive Technology Right - Audiology
- Hearing Device Cochlear Implant. Manufacturer Cochlear Americas.

Ambulatory Documentation

Model Internal: CI522; External: CP950 & CP910. Serial Number Internal: 1020170202749. Date Fit Surgery: 2/2/2017; Activation: 2/21/2017. Battery Size 675. Rechargeable Battery Lithium ion (CP910 only).

Basic Social History

Living Arrangement Parent(s)/Guardian. Legal Guardian: Parent. Lives With: Mother, Father, Brother, nanny. Language Spoken at Home: English and Arabic.

Home/Environment

Living situation: Home with assistance. Devices or Anatomic Adaptations: Ventriculoperitoneal shunt, Glasses, Hearing aides. Home equipment: Adaptive stroller, Ankle foot orthoses (AFO's).

Family History

Developmental delay: Brother.
Seizures: Cousin.

Boston Children's Hospital
300 Longwood Avenue
Boston, MA 02115

BCH MRN: **500-20-94**
Patient Name: **ALDHAHERI, ABDULLA KHALIFA**
DOB/Age/Sex: 2/18/2014 3 years Male

Admit Date: 5/25/2017
Discharge Date: 5/25/2017

Patient Location: DHHP Waltham
Patient Type: Outpatient
Financial #: 6120846037

Ambulatory Documentation

DOCUMENT NAME: Communication Enhancement Visit
SERVICE DATE/TIME: 5/25/2017 17:47 EDT
PERFORM INFORMATION: SALAMY CCC-SLP,NICOLE (5/25/2017 17:48 EDT)
SIGN INFORMATION: SALAMY CCC-SLP,NICOLE (5/25/2017 17:48 EDT)
RESULT STATUS: Auth (Verified)

Reason for Visit
Speech and language therapy

Session Narrative/HPI
Abdulla AlDhaheri was seen today (5/25/17) for speech and language therapy with speech-language pathologist, Nicole Salamy, MS, CCC-SLP. He arrived today with his mother, nanny and brother. His mother joined him for the duration of the session.

Abdulla recently started attending the TEC school in Walpole and mother reports that he has made a smooth transition and enjoys being there. Abdulla arrived wearing his N6 speech processor in a headband. Mother reports that Abdulla will often initially startle and cry when the coil is first placed on his head, but then he settles. Reportedly, he is not responding to sounds at home, but his mother has observed that he is making more vocal attempts and pronouncing more “words” at home.

Abdulla arrived today asleep so his brother was seen first. When it was his turn for the session, he was awake, but had been crying. He came to the therapy room and settled for a few minutes, but was visibly fatigued. He sat in a Rifton chair and looked at a few different toys, but did not engage with anything. While using the iPad, he required hand over hand assistance from his mother. He began to cry again and was visibly tired so mother asked to stop the session so they could go home. The plan is to see Abdulla again in July after the Ramadan holiday.

Problem List/Past Medical History
Ongoing
- Bronchopulmonary dysplasia
- Childhood asthma
- Cochlear implant in situ
- Developmental delay
- Dysarthria
- Feeding difficulties and mismanagement
- Hearing loss
- Mixed receptive-expressive language disorder
- Sensorineural hearing loss, bilateral
- Spastic quadriplegic cerebral palsy
- Wheeze

Historical
- Speech delay

Procedure/Surgical History
Cochlear device implantation, with or without mastoidectomy (02/02/2017), Cochlear device implantation, with or without mastoidectomy (02/02/2017).

Medications
- aerochamber with medium mask, See Instructions
- albuterol 1.25 mg/3 mL (0.042%) inhalation solution, 1.25 mg, INH, Q4hr, PRN
- Flovent HFA 110 mcg/inh inhalation aerosol, 2 puff, INH, daily
- Nebulizer machine, See Instructions
- Vitamin D3 400 intl units/mL oral liquid, 400 unit = 1 mL, PO, daily

Allergies
No known allergies

Social History
Assistive Technology Right - Audiology
- Hearing Device Cochlear Implant. Manufacturer Cochlear Americas. Model Internal: CI522; External: CP950

Ambulatory Documentation

& CP910. Serial Number Internal: 1020170202749. Date Fit Surgery: 2/2/2017; Activation: 2/21/2017. Battery Size 675. Rechargeable Battery Lithium ion (CP910 only).

Basic Social History

Living Arrangement Parent(s)/Guardian. Legal Guardian: Parent. Lives With: Mother, Father, Brother, nanny. Language Spoken at Home: English and Arabic.

Home/Environment

Living situation: Home with assistance. Devices or Anatomic Adaptations: Ventriculoperitoneal shunt, Glasses, Hearing aides. Home equipment: Adaptive stroller, Ankle foot orthoses (AFO's).

Family History

Developmental delay: Brother.
Seizures: Cousin.

Boston Children's Hospital

300 Longwood Avenue
Boston, MA 02115

BCH MRN: **500-20-94**
Patient Name: **ALDHAHERI, ABDULLA KHALIFA**
DOB/Age/Sex: 2/18/2014 3 years Male

Admit Date: 4/20/2017
Discharge Date: 4/20/2017

Patient Location: DHHP Waltham
Patient Type: Outpatient
Financial #: 6120726381

Ambulatory Documentation

DOCUMENT NAME: Communication Enhancement Visit
SERVICE DATE/TIME: 4/20/2017 17:17 EDT
PERFORM INFORMATION: SALAMY CCC-SLP,NICOLE (4/20/2017 17:19 EDT)
SIGN INFORMATION: SALAMY CCC-SLP,NICOLE (4/20/2017 17:19 EDT)
RESULT STATUS: Auth (Verified)

Reason for Visit
Speech and Language therapy post CI

Session Narrative/HPI
Abdulla AlDhaheri was seen today (4/20/17) for speech and language therapy with speech-language pathologist, Nicole Salamy, MS, CCC-SLP. Graduate student intern, Reem Mohamed also joined for the session. His mother and brother, Mohamed joined for the duration of the session.

Abdulla was wearing an N6 speech processor today and Mother reports that he is not responding to sounds at home. She notices a difference since the change in speech processor devices. However, his mother is noticing that he is vocalizing more at home. He continues to produce “mama” and “baba” and is now saying “nuh nuh” as well. He was observed producing “nuh nuh” and /n/ during the session today as well. He also vocalized to get an adult’s attention throughout the session.

During a structured listening task, Abdulla seemed to respond (with a smile) to the speech sound “ahhh,” however this was not consistent. He also raised his eyebrows in the presence of a loud environmental sound.

Abdulla was also observed pointing today to desired items. When his mother left the room, he also pointed towards the door. Mother reports that he is pointing at home to make requests. He was very engaged today and enjoyed playing with a variety of toys, especially cars.

Abdulla will be starting the TEC school next week where he will receive SLP, OT and PT services. Mother also asked about using sign language with Abdulla. Certainly adults and care providers are encouraged to use signs with Abdulla to facilitate language and communication.

The plan is to see Abdulla in one month after they get settled in school. Abdulla’s mother is encouraged to provide my contact information to the school so that I can connect with the speech-language pathologist there.

Problem List/Past Medical History
Ongoing
- Bronchopulmonary dysplasia
- Childhood asthma
- Cochlear implant in situ
- Developmental delay
- Dysarthria
- Feeding difficulties and mismanagement
- Hearing loss
- Mixed receptive-expressive language disorder
- Sensorineural hearing loss, bilateral
- Spastic quadriplegic cerebral palsy
- Wheeze

Historical
- Speech delay

Procedure/Surgical History
Cochlear device implantation, with or without mastoidectomy (02/02/2017), Cochlear device implantation, with or without mastoidectomy (02/02/2017).

Medications
- aerochamber with medium mask, See Instructions
- albuterol 1.25 mg/3 mL (0.042%) inhalation solution, 1.25 mg, INH, Q4hr, PRN
- Flovent HFA 110 mcg/inh inhalation aerosol, 2 puff, INH, daily
- Nebulizer machine, See Instructions
- Vitamin D3 400 intl units/mL oral liquid, 400 unit = 1 mL, PO, daily

Allergies
No known allergies

Social History
Assistive Technology Right - Audiology
- Hearing Device Cochlear Implant. Manufacturer Cochlear Americas. Model Internal: CI522; External: CP950

Ambulatory Documentation

& CP910. Serial Number Internal: 1020170202749. Date Fit Surgery: 2/2/2017; Activation: 2/21/2017. Battery Size 675. Rechargeable Battery Lithium ion (CP910 only).

Basic Social History

Living Arrangement Parent(s)/Guardian. Legal Guardian: Parent. Lives With: Mother, Father, Brother, nanny. Language Spoken at Home: English and Arabic.

Home/Environment

Living situation: Home with assistance. Devices or Anatomic Adaptations: Ventriculoperitoneal shunt, Glasses, Hearing aides. Home equipment: Adaptive stroller, Ankle foot orthoses (AFO's).

Family History

Developmental delay: Brother.
Seizures: Cousin.

Boston Children's Hospital
300 Longwood Avenue
Boston, MA 02115

BCH MRN: **500-20-94**
Patient Name: **ALDHAHERI, ABDULLA KHALIFA**
DOB/Age/Sex: 2/18/2014 3 years Male

Admit Date: 9/11/2017
Discharge Date: 9/11/2017

Patient Location: Audiology Waltham
Patient Type: Outpatient
Financial #: 6120784940

Ambulatory Documentation

DOCUMENT NAME: Audiology Visit
SERVICE DATE/TIME: 5/8/2017 11:55 EDT
PERFORM INFORMATION: LEWKOWITZ AuD,ASHLEIGH (5/15/2017 11:57 EDT)
SIGN INFORMATION: LEWKOWITZ AuD,ASHLEIGH (5/15/2017 11:57 EDT)
RESULT STATUS: Auth (Verified)

Reason for Visit
Routine mapping and testing of right cochlear implant

Session Narrative/HPI
NAME: Abdulla AlDhaheri
DOB: 2/18/2014
MR#: 500-20-94

DATE: 5/8/2017

RIGHT
IMPLANT: CI522
SURGERY DATE: 2/2/2017
INITIAL STIM: 2/21/2017
PROCESSOR(S): CP950 (Kanso) & CP910 (Nucleus 6)

AUDIOLOGIST: Ashleigh Lewkowitz, AuD, CCC-A, FAAA, PASC, CISC

*NOTES: 10 weeks post-stim of right ear. Mother continues to report new vocalizations: /baba/, /mama/, /nana/, /ana/, and a /bumbum/ sound for the car; however, Mom does not feel he consistently responds to sounds in his environement or when she calls his name. Abdulla arrives today wearing his Kanso speech processor as his Nucleus 6 is reportedly broken - visual inspection reveals it is his rechargeable battery which is broken; the processor itself appears to be in working condition.
Abdulla has started school 5 days per week, 6 hours per day in a special needs classroom in Dedham. He receives thrice weekly speech therapy sessions and thrice weekly PT/OT services.

*EVALUATION: Visual and tactile inspection of Abdulla's magnet site reveals no redness or swelling. Prior to mapping, Abdulla is evaluated in the sound booth using two-tester BOA, VRA, and CPA; a speech awareness threshold is obtained at 25-30 dB HL but further reliable responses to warble tones cannot be obtained due to fatigue/inattention.

Impedance measures are within appropriate limits and consistent with previous. Stimulation rate is returned to 900 Hz and Ts/Cs set using NRT and BOA/VRA/CPA responses.

Abdulla's right Nucleus 6 speech processor is configured as follows:

*PROCESSOR CONFIGURATION(S):
RIGHT

Problem List/Past Medical History
Ongoing
- Bronchopulmonary dysplasia
- Childhood asthma
- Cochlear implant in situ
- Developmental delay
- Dysarthria
- Feeding difficulties and mismanagement
- Hearing loss
- Mixed receptive-expressive language disorder
- Sensorineural hearing loss, bilateral
- Spastic quadriplegic cerebral palsy
- Wheeze

Historical
- Speech delay

Procedure/Surgical History
Cochlear device implantation, with or without mastoidectomy (02/02/2017), Cochlear device implantation, with or without mastoidectomy (02/02/2017).

Social History
Assistive Technology Right - Audiology
- Hearing Device Cochlear Implant. Manufacturer Cochlear Americas. Model Internal: CI522; External: CP950 & CP910. Serial Number Internal: 1020170202749. Date Fit Surgery: 2/2/2017; Activation: 2/21/2017. Battery Size 675. Rechargeable Battery Lithium ion (CP910 only).

Basic Social History
- Living Arrangement Parent(s)/Guardian. Legal Guardian: Parent. Lives With: Mother, Father, Brother, nanny. Language Spoken at Home: English and Arabic.

Home/Environment
- Living situation: Home with assistance. Devices or Anatomic Adaptations:

Ambulatory Documentation

P1	Map #29	900 Hz, ADRO (map 28 for Kanso processor)
P2	Map #-	-
P3	Map #-	-
P4	Map #-	-

*SUMMARY & RECOMMENDATIONS: With today's changes, Abdulla is noted to turn consistently to his mother's voice without visual cues. Mom is again counseled on realistic expectations for children in the first few months of implant use. Abdulla will return for mapping in July and in September for booth testing.

I can be reached at 781-216-2265 or ashleigh.lewkowitz@childrens.harvard.edu for any questions/concerns regarding these findings and recommendations.

Ashleigh Lewkowitz, AuD, CCC-A, FAAA, PASC, CISC
Clinical Audiologist

Ventriculoperitoneal shunt, Glasses, Hearing aides. Home equipment: Adaptive stroller, Ankle foot orthoses (AFO's).

Family History

Developmental delay: Brother.
Seizures: Cousin.

Boston Children's Hospital
300 Longwood Avenue
Boston, MA 02115

BCH MRN: **500-20-94**
Patient Name: **ALDHAHERI, ABDULLA KHALIFA**
DOB/Age/Sex: 2/18/2014 3 years Male

Admit Date: 8/18/2017
Discharge Date: 8/18/2017

Patient Location: Cerebral Palsy
Patient Type: Outpatient
Financial #: 6120539933

Ambulatory Documentation

DOCUMENT NAME: Audiology Visit
SERVICE DATE/TIME: 4/5/2017 07:29 EDT
PERFORM INFORMATION: LEWKOWITZ AuD,ASHLEIGH (4/10/2017 07:33 EDT)
SIGN INFORMATION: LEWKOWITZ AuD,ASHLEIGH (4/10/2017 07:33 EDT)
RESULT STATUS: Auth (Verified)

Reason for Visit
Routine mapping of right cochlear implant

Session Narrative/HPI
NAME: Abdulla AlDhaheri
DOB: 2/18/2014
MR#: 500-20-94

DATE: 4/5/2017

RIGHT
IMPLANT: CI522
SURGERY DATE: 2/2/2017
INITIAL STIM: 2/21/2017
PROCESSOR(S): CP950 (Kanso) & CP910 (Nucleus 6)

AUDIOLOGIST: Ashleigh Lewkowitz, AuD, CCC-A, FAAA, PASC, CISC

*NOTES: 6 weeks post-stim of right ear. Mother continues to report increased auditory awareness and sound production. Abdulla reportedly makes /b/ and /m/ sounds consistently and has increased his responsiveness to sounds. Datalogging reveals an average of 1.1 hours use per day with 17 coil-off events per day accounting for an additional 8 hours per day of use time; essentially, Abdulla is utilizing his processor 9 hours per day but is only receiving consistent auditory input for roughly 1 hour.
Mom also reports Abdulla will be starting school in their local public school in Dedham in April but she is awaiting more information from the district regarding start date and program specifics. Abdulla will reportedly be attending school 5 days a week, including the summer.

*EVALUATION: Visual and tactile inspection of Abdulla's magnet site reveals no redness or swelling. Impedance measures are within appropriate limits and consistent with previous. CPA/VRA/BOA are used to adjust T and C levels with fair reliability for Ling sounds. Abdulla's attention for CPA is noted to be less today than at previous visits.
Note: Abdulla's CP910 speech processor is used for programming today; a Hearing Henry headband is used for retention with good success.

Abdulla's right CP910 and CP950 speech processors are configured as follows:

*PROCESSOR CONFIGURATION(S):
RIGHT
P1 Map #25/26 (Kanso/N6): CPA/VRA/BOA with two testers; Home

*SUMMARY & RECOMMENDATIONS: No adverse responses are observed with today's

Problem List/Past Medical History
Ongoing
- Bronchopulmonary dysplasia
- Childhood asthma
- Cochlear implant in situ
- Developmental delay
- Dysarthria
- Feeding difficulties and mismanagement
- Hearing loss
- Mixed receptive-expressive language disorder
- Sensorineural hearing loss, bilateral
- Spastic quadriplegic cerebral palsy
- Wheeze

Historical
- Speech delay

Procedure/Surgical History
Cochlear device implantation, with or without mastoidectomy (02/02/2017), Cochlear device implantation, with or without mastoidectomy (02/02/2017).

Social History
Assistive Technology Right - Audiology
- Hearing Device Cochlear Implant. Manufacturer Cochlear Americas. Model Internal: CI522; External: CP950 & CP910. Serial Number Internal: 1020170202749. Date Fit Surgery: 2/2/2017; Activation: 2/21/2017. Battery Size 675. Rechargeable Battery Lithium ion (CP910 only).

Basic Social History
- Living Arrangement Parent(s)/Guardian. Legal Guardian: Parent. Lives With: Mother, Father, Brother, nanny. Language Spoken at Home: English and Arabic.

Home/Environment
- Living situation: Home with assistance. Devices or Anatomic Adaptations:

Ambulatory Documentation

new settings for very loud sounds. Mother is counseled on the use/care of the CP910 processor, rechargeable batteries, and charger. Abdulla will return for follow-up, to include booth testing, in one month.

I can be reached at 781-216-2265 or ashleigh.lewkowitz@childrens.harvard.edu for any questions/concerns regarding these findings and recommendations.

Ashleigh Lewkowitz, AuD, CCC-A, FAAA, PASC, CISC
Clinical Audiologist

Ventriculoperitoneal shunt, Glasses, Hearing aides. Home equipment: Adaptive stroller, Ankle foot orthoses (AFO's).

Family History

Developmental delay: Brother.
Seizures: Cousin.